

Nonsurgical endodontic treatment of a maxillary central incisor with two separate roots: A case report

Mohammad Reza Nabavizadeh^{1*} DDS, MS, Mohammad Reza Jouyandeh² DDS, Adnan Atbaee¹ DDS, MS, and Mahdi Sedigh Shams¹ DDS, MS

1. Assistant Professor of Endodontics, Dental School, Shiraz University of Medical Sciences, Shiraz, Iran.

2. Postgraduate Student of Endodontics, Dental School, Shiraz University of Medical Sciences, Shiraz, Iran.

Abstract

The success of endodontic therapy requires knowledge of the internal and external dental anatomy and its variations in presentation. This case report involves endodontic treatment of a traumatized maxillary central incisor with two separate roots. [Iranian Endodontic Journal 2010; 5(3):135-7]

Keywords: Incisor, Maxilla, Root canal.

Received March 2010; accepted June 2010

*Correspondence: Dr. Mohammad Reza Nabavizadeh, Department of Endodontic, Faculty of Dentistry, Shiraz University of Medical Sciences, Shiraz, Iran. E-mail: mohammadrezanabavizadeh@yahoo.com

Introduction

Elimination of infection from the root canal system and prevention of reinfection is one of the main objectives of non surgical endodontic treatment (1). Errors in debridement and shaping and obturation of root canal system can lead to endodontic failure and therefore adequate knowledge of anatomy of the root canal system and its variations are essential. These variations can also be found in maxillary central incisors (2-16).

The purpose of this article is to report on the endodontic treatment of a maxillary central incisor with two distinct roots.

Case Report

A 16 years old boy was referred for endodontic treatment of his discolored maxillary left central incisor. He reported a history of athletic trauma to that tooth 8 months previously. Proceeding pulp vitality tests and radiographic examination, the tooth was diagnosed with asymptomatic apical periodontitis. The periapical radiograph revealed previous incomplete endodontic intervention. Moreover the tooth had a root configuration which suggested two separate roots with separate apices (Figure 1A). The periodontal ligament seemed to be widened at both apices. The tooth crown was clinically observed to be discolored when compared with the adjacent incisors.

After application of local anesthetic and rubber dam isolation, the tooth was accessed in the standard manner. Two distinct canal orifices were identified upon exploration of the pulp chamber (Figure 1B). Root canal working length was determined and then the root canal system was cleaned and shaped using Protaper Files (Dentsply, Maillefer, Ballaigues, Switzerland), Gates Glidden drills (Dentsply, Maillefer, Ballaigues, Switzerland), and sodium hypochlorite irrigant. Both canals were dried with paper points (Diadent, Tianjin, China) and obturated with gutta-percha (Orca, China) and AH-26 sealer (Dentsply, Riodejaniro, RJ, Brazil), using warmed vertical condensation. The lingual access cavity was sealed with a polycarboxylate base (Hongchang Dental Equipment, China); subsequently, the tooth was restored with light cured composite resin (Shanghai A- Dental Products, China). The postoperative radiograph revealed two separate obturated canals with two separate roots (Figure 1C).

The patient was given postoperative instructions and then dismissed. At the recall examination six month post-operatively, he reported no symptoms or signs. Clinical examination also did not reveal any signs of pathology and the radiographs taken (Figure 1D) demonstrated no abnormalities and complete periapical osseous repair.

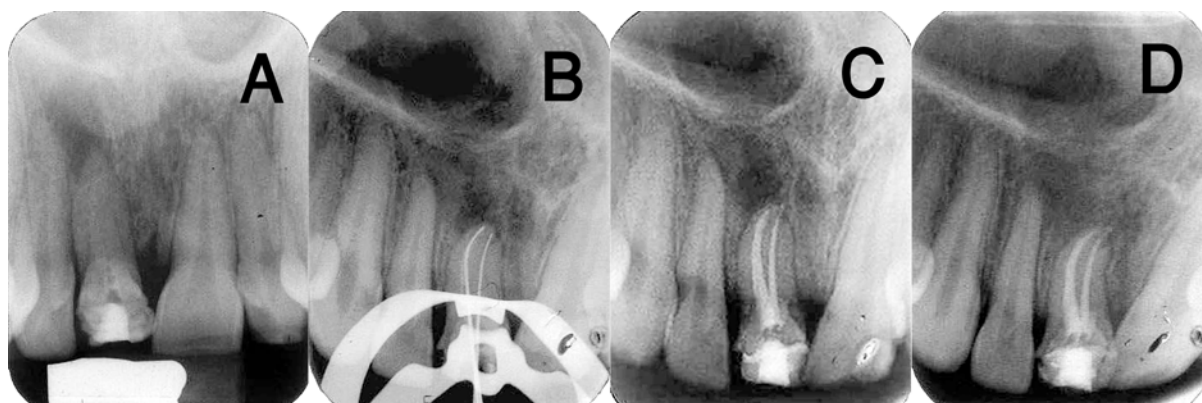


Figure 1. A) A pulp-otomized right central incisor. Examination of the radiograph revealed the possibility of two roots. B) The working length measurement radiograph showed two files in two separated roots. C) Postoperative radiograph, two separated roots. D) Radiograph taken at six-month recall visit, showing healing of apical pathosis

Discussion

The prevalent opinion that maxillary central incisors possess only one root with one canal can lead to endodontic treatment failure.

The present report illustrates a rare case of maxillary central incisor with two root canals, without morphological anomaly of the crown. According to literature (5), there are no limits for the morphological variability of the root canal. So practitioners must consider anatomical variation in number and architecture of root canal system. Vertucci (2) has reported that maxillary central incisor presents single root and single canal in 100% of the cases. There were few case reports describing an additional canal in the maxillary central incisor (3-12). However, a proportion of these cases were teeth that had undergone gemination or fusion (7,11). In these teeth canals were usually located mesiodistally to each other; however, in our study they were aligned buccolingually. Double crowns are characteristic in geminated teeth, and bifid crowns with one root is obvious in fused teeth (17). However, in this case anomalous crown anatomy was absent. Moreover, a diagnosis of dens invagination could be disregarded due to absence of enamel and dentin invagination in the pulp on the pretreatment radiograph. Palatogingival or distolingual groove was also absent clinically and radiographically.

It may be reasonable to assume that during epithelial diaphragm formation, an incident may induce the development of a horizontal flap of Hertwig's epithelial root sheet and the

fusion of this horizontal flap, results in the formation of second root without any alterations in the crown (18). However, this is a rare phenomenon and a maxillary central incisor with more than one root is an exceptional condition with only few case reports mentioned in literature (3-12).

Conclusion

The experience from the present case demonstrates the variability of root canal morphology of maxillary central incisor. The clinician should be careful; even the most routine of cases might deviate from the norm.

References

1. Cohen S, Hargreaves KM: Pathways of the pulp. 9th Edition. Mosby Ins. 2006; pp. 290-2.
2. Sinai IH, Lustbader S. A dual-rooted maxillary central incisor. *J Endod* 1984;10:105-6.
3. Vertucci FJ. Root canal anatomy of the human permanent teeth. *Oral Surg Oral Med Oral Pathol* 1984;58:589-99.
4. Patterson JM. Bifurcated root of upper central incisor. *Oral Surg Oral Med Oral Pathol* 1970;29:222.
5. Heling B. A two-rooted maxillary central incisor. *Oral Surg Oral Med Oral Pathol* 1977;43:649.
6. Mader CL, Konzelman JL. Double-rooted maxillary central incisor. *Oral Surg Oral Med Oral Pathol* 1980;50:99.
7. Libfeld H, Stabholz A, Friedman S. Endodontic therapy of bilaterally geminated permanent maxillary central incisors. *J Endod* 1986;12:214-6.
8. Michanowicz AE, Michanowicz JP, Ardila J, Posada A. Apical surgery on a two-rooted maxillary

central incisor. J Endod 1990;16:454-5.

9. al-Nazhan S. Two root canals in a maxillary central incisor with enamel hypoplasia. J Endod 1991;17:469-71.

10. Lambruschini GM, Camps J. A two-rooted maxillary central incisor with a normal clinical crown. J Endod 1993;19:95-6.

11. Cimilli H, Kartal N. Endodontic treatment of unusual central incisors. J Endod 2002;28:480-1.

12. Rao Genovese F, Marsico EM. Maxillary central incisor with two roots: a case report. J Endod 2003;29:220-1.

13. González-Plata-R R, González-Plata-E W. Conventional and surgical treatment of a two-rooted maxillary central incisor. J Endod 2003;29:422-4.

14. Ghoddsi J, Zarei M, Vatanpour M. Endodontic treatment of maxillary central incisor

with two roots. A case report. N Y State Dent J 2007;73:46-7.

15. Sponchiado EC Jr, Ismail HA, Braga MR, de Carvalho FK, Simões CA. Maxillary central incisor with two root canals: a case report. J Endod 2006;32:1002-4.

16. Benenati FW. Endodontic treatment of a maxillary central incisor with two separate roots: case report. Gen Dent 2006;54:265-6.

17. Hosomi T, Yoshikawa M, Yaoi M, Sakiyama Y, Toda T. A maxillary central incisor having two root canals geminated with a supernumerary tooth. J Endod 1989;15:161-3.

18. Khojastepour L, Khayat A. Maxillary central incisor with two roots: A case report. Journal of dentistry, Tehran University of Medical Sciences 2005;2:74-7.

The Importance of a Well Written Paper

An international report 20 years ago showed that most surveyed business executives cited writing as one of the most neglected skills in the business world, yet one of the most important to productivity. Ten years later, clear writing was noted as the most valued skill that 80 percent of employees did not have. Clear and concise writing skills in both Farsi and English are sometimes lacking in Iranian scientist, clinicians and researchers. At high school level, university entrance exams do not assess our essay writing abilities in any language, let alone scientific or creative writing skills. Moreover, there is a huge deficit of native English language teachers from Preschool to Universities and therefore a whole generation of educated skilled individuals may be unaware of the inadequacies of their second language.

Scientific writing is more than just science; it is an art that needs patience, practice and training.

Prose, like food, needs to be well presented, suitable for the audience and provided in small bites-for easy digestion. Whether writing a journal article in English or Farsi, the paper needs to be crystal clear; *i.e.* plain and simple.

Word by word or line by line translations from Farsi to English transform the text into an alien language. A whole paragraph that is thought or written in Farsi needs to be restructured before pen is put to paper. Repetitions may be appreciated in poetry and literature, yet they should be absolutely avoided in scientific writing. Long winded sentences should be broken down and grammar and writing style should be addressed. General recommendation would be to read up on scientific writing or take lessons; and finally practice, practice and practice.

We will be providing a series of short guidance notes on how to write and publish a good paper in English the forthcoming issues of IEJ.

Dr Laleh Marvasti
Dr. Sanam Kheirieh
Technical and English Editor of IEJ