

# Mandibular first and second molars with three mesial canals: a case series

Mohsen Aminsobhani<sup>1</sup> DDS, MSc, Behnam Bolhari<sup>2\*</sup> DDS, MSc, Noushin Shokouhinejad<sup>1</sup> DDS, MSc, Abdollah Ghorbanzadeh<sup>2</sup> DDS, MSc, Sholeh Ghabraei<sup>2</sup> DDS, MSc, and Mohamad Bagher Rahmani<sup>3</sup> DDS

1. Assistant Professor of Endodontics, Dental School/Dental Research Center, Tehran University of Medical Sciences, and Iranian Center for Endodontic Research, Tehran, Iran.

2. Assistant Professor of Endodontics, Dental School/Dental Research Center, Tehran University of Medical Sciences, Tehran, Iran.

3. Dentist, Private Practice.

## Abstract

Adequate cleaning, shaping and filling of the root canal system are mandatory for successful root canal treatment. Thorough knowledge of root canal morphology and unusual anatomy of the tooth is critical for the practitioner. The occurrence and location of the third mesial canal (Middle Mesial Canal) in mandibular first and second molars in relation to other two mesial canals that were treated in private practice were studied. In 27 clinical cases, the presence of a middle mesial canal was demonstrated. The third canal was located in the middle of the distance between the mesiobuccal and mesiolingual canals. This canal configuration was found in six second lower molars and twenty one first molars. Middle mesial canal in all of our cases joined to mesiobuccal or mesiolingual canals. None of the teeth consisted of three independent canals with three apical foramina. In conclusion, every attempt should be made to find and treat all root canals of a tooth. [Iranian Endodontic Journal 2010;5(1):36-9]

Keywords: Four canals tooth, Mandible, Molar, Root canal anatomy.

Received July 2009; accepted December 2009

\*Correspondence: Dr. Behnam Bolhari, Department of Endodontics, Dental School, Tehran University of Medical Sciences, Ghods Ave., Enghelab St., Tehran, Iran. E-mail: [behnambolhari@yahoo.com](mailto:behnambolhari@yahoo.com)

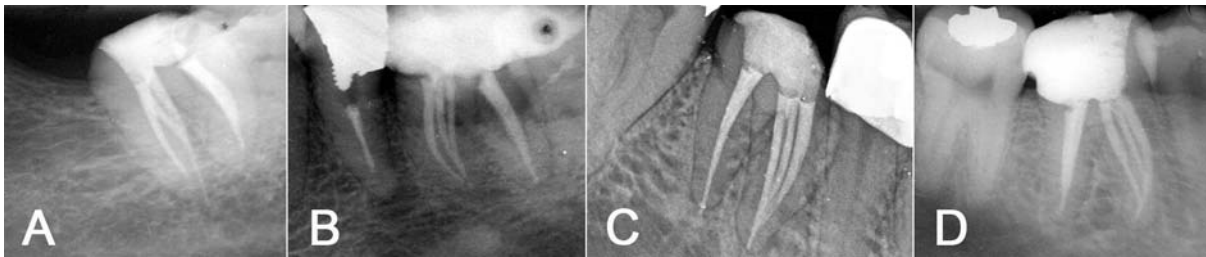
## Introduction

Successful root canal treatment depends on adequate cleaning, shaping, and filling of the root canal system. It is critical that the practitioner has thorough knowledge of root canal morphology of each individual tooth.

The two-rooted mandibular first permanent molars usually have three canals. Two root canals are located in mesial root and another one in distal root. Hess reported that the prevalence of three root canals in mandibular molars was 78% (1). *In vitro* studies by Skidmore and Bjorndal (2) demonstrated the prevalence of two root canals in distal root of mandibular molars was almost 30%.

However, unusual root canal anatomy associated with the mandibular first molars has been reported in several studies and case reports (3-10). Vertucci and William (11), as well as Barker *et al.* (12) described the presence of a middle mesial canal (MMC).

Middle mesial canal is sometimes present in the developmental groove between MB and ML canals (8). In a radiographic study of extracted teeth Goel *et al.* (5) reported that mandibular first molars had three mesial canals in 13.3%, four mesial canals in 3.3%, and three distal canals in 1.7% of specimens. In a clinical study of 145 mandibular first molars, Fabra-Campos found four molars (2.07%) with five canals—three in mesial root and two in distal (4). In the four cases, the MMC did not show an independent apical foramen. On the other hand, it has been reported very few mandibular first and second molars with three separated canals in mesial root (3,6,7,13-16). Shahi *et al.* evaluated the distribution of the root canal number and configuration in the 209 mandibular first permanent molars in Iranian population and found that 0.95% of the mesial roots had three mesial canals but they did not show canal configuration of this root canals (17).



**Figure 1.** A) Mandibular second molar (2-3-2), B) mandibular first molar (3-2), C) mandibular first molar (3-1), D) mandibular first molar (3-2-1)

They mentioned that three canals with separate foramina were not seen in any of the roots studied. In Ahmed *et al.*'s study, in a Sudanese population using a clearing technique, the prevalence of three mesial canals was 4% in mandibular first molars and 10% in mandibular second molars (18).

In a clinical study of 251 root-canal treated permanent mandibular first molars in a Saudi Arabian sub-population, the teeth were examined clinically and radiographically and all mesial roots had two root canals and no unusual canal configuration was observed (19). Reuben *et al.* evaluated root canal morphology of 125 extracted mandibular first molars in an Indian population by using spiral computed tomography (SCT); they did not find mandibular molar mesial roots with three mesial canals (20).

In the current study, 27 cases of mandibular first and second molars with three mesial canals and one or two distal canals in Iranian population were reported.

**Case Series**

A total of 27 mandibular molars with three mesial canals were treated from 2000 to 2009 in our practice. Twenty two cases received initial root canal therapy (RCT); and in five cases, endodontic re-treatment was performed. Two were treated by a general practitioner and the rest were treated by endodontists in their private practice.

Of the 27 mandibular molars, 21 teeth (77.8%) were first molars and 6 teeth (22.2%) were second molars. Two cases showed 2 orifices, 3 root canals, and 2 apical foramina "2-3-2" (Figure 1A). Three orifices and 2 apical foramina "3-2" were seen in 14 cases (Figure 1B); three orifices and one apical foramen "3-

1" in 4 cases (Figure 1C); and 3 orifices, 2 root canals, and 1 apical foramen "3-2-1" were seen in 7 cases (Figure 1D). The variations of canal configurations of mesial roots of the treated teeth are shown in Table 1.

Of the 14 cases which showed type "3-2" root canal morphology, in 10 cases the middle mesial canal joined the mesiobuccal canal at the apical area; and in 4 cases, MMC and mesiolingual canals joined together in the apical third of the mesial root. In all of 7 cases that showed type "3-2-1" root canal morphology, the MMC joined the mesiobuccal canal to make a single canal. Subsequently, this canal joined the mesiolingual canal ending in one apical foramen at the apical area of the mesial root.

**Discussion**

Before root canal treatment is performed, the clinician should ideally have adequate knowledge of the pulp chamber and internal anatomy of the teeth. All root canals should be accessed, cleaned, and shaped to achieve a hermetic obturation of the entire root canal space.

There is an abundant amount of reports that relate the anatomic variations of mandibular molars (1). This should induce the clinician to accurately observe the pulp chamber floor to locate possible canal orifices. This will increase the long term prognosis of endodontic therapy. Searching for additional canal orifices should

**Table 1. Mesial root canal pattern (Vertucci)**

Pattern	2-3-2	3-2	3-1	3-2-1
Tooth				
Mandibular 1 <sup>st</sup> molar	0	13	4	4
Mandibular 2 <sup>nd</sup> molar	2	1	0	3
Total	2	14	4	7

be standard practice for clinicians. A round bur or an ultrasonic tip can be used for removal of any protuberance from the mesial axial wall which would prevent direct access to the developmental groove between MB and ML orifices. This developmental groove should be carefully checked with the sharp tip of an endodontic explorer. If depression or orifices are located, the groove can be troughed with ultrasonic tips at its mesial aspect until a small file can negotiate this intermediate canal (8).

New technologies, such as the dental operating microscope and dental loupes, offer magnification and illumination of the operating field and substantially improve the visualization of root canal orifices (21,22). We did not use magnification or these new technologies during treatment sessions (Figure 5). It is possible that more cases may have been discovered with magnification and extra illumination.

Numerous studies in the past decades have described the morphology of teeth including mandibular molars (23). The morphology of the mesial root canals in mandibular molars is complex and difficult to find, with a high frequency of inter-canal communications and or isthmuses (2,5,18,23-26).

The presence of a third canal (middle mesial) in the mesial root of the mandibular molars has been reported to have an incidence of 0.95%-15% (4,8,9,12,17,23,24,27,28). In almost all of the clinical cases reported until today, this canal joined the mesiobuccal or mesiolingual canal in the apical third (3,4,7,29,30). However a few mandibular first molars that had three independent canals in their mesial root have been reported (3,6,7,13-16). In this case series no mesial root with three distinct and independent canals was discovered which concurs with other studies (6,17,27).

In 12 cases (44.5%), MMC joined the mesiobuccal canal in the apical third. In 4 cases (14.8%), it joined to the mesiolingual canal in the apical area. These finding are in agreement with Fabra-Campos (4) who showed that MMC joined to mesiobuccal canal in most cases.

Most of the reported and reviewed cases in literature look at first mandibular molars and a few clinical cases that have been reported are second mandibular molars. In our case series, of the 27 molars treated, 21 (77.8%) were first

molar and the others were second molar. This correlates with Barker's findings (12).

### Conclusion

In conclusion, every attempt should be made to find and treat all root canals to ensure successful endodontic treatment. The importance of an accurate clinical evaluation of root canal number and morphology in mandibular molars cannot be overemphasized.

### References

1. Cleghorn BM, Goodacre CJ, Christie WH: Morphology of teeth and their root canal system. In: Ingle JJ, Backland LK, Baumgarthner JC: ENDODONTICS, 6<sup>th</sup> Edition. BC Decker: Inc, 2008: pp. 151-210.
2. Skidmore AE, Bjorndal AM. Root canal morphology of the human mandibular first molar. *Oral Surg Oral Med Oral Pathol* 1971;32:778-84.
3. Beatty RG, Krell K. Mandibular molars with five canals: report of two cases. *J Am Dent Assoc* 1987;114:802-4.
4. Fabra-Campos H. Unusual root anatomy of mandibular first molars. *J Endod* 1985;11:568-72.
5. Goel NK, Gill KS, Taneja JR. Study of root canals configuration in mandibular first permanent molar. *J Indian Soc Pedod Prev Dent* 1991;8:12-4.
6. Min K. Clinical management of a mandibular first molar with multiple mesial canals: a case report. *J Contemp Dent Pract* 2004 15;5:142-9.
7. Pomeranz HH, Eidelman DL, Goldberg MG. Treatment considerations of the middle mesial canal of mandibular first and second molars. *J Endod* 1981;7:565-8.
8. Vertucci FJ. Root canal morphology and its relationship to endodontic procedures. *Endod Topics* 2005;10:3-29.
9. Sert S, Bayirli GS. Evaluation of the root canal configurations of the mandibular and maxillary permanent teeth by gender in the Turkish population. *J Endod* 2004;30:391-8.
10. Zhao X, Gong JY. Five root canals in right mandibular first molar: report of one case. *Shanghai Kou Qiang Yi Xue* 2009;18:223-4.
11. Vertucci FJ, Williams RG. Root canal anatomy of the mandibular first molar. *J N J Dent Assoc* 1974;45:27-8.
12. Barker BC, Parsons KC, Mills PR, Williams GL. Anatomy of root canals. III. Permanent mandibular molars. *Aust Dent J* 1974;19:408-13.
13. Bond JL, Hartwell GR, Donnelly JC, Portell FR. Clinical management of middle mesial root canals in mandibular molars. *J Endod* 1988;14:312-4.

14. Ricucci D. Three independent canals in the mesial root of a mandibular first molar. *Endod Dent Traumatol* 1997;13:47-9.
15. Poorni S, Kumar R, Indira R. Canal complexity of a mandibular first molar. *J Conserv Dent* 2009;12:37-40.
16. Jacobsen EL, Dick K, Bodell R. Mandibular first molars with multiple mesial canals. *J Endod* 1994;20:610-3.
17. Shahi S, Yavari HA, Rahimi S, Torkamani R. Root canal morphology of human mandibular first permanent molars in an Iranian population. *JODDD* 2008;2:20-3.
18. Ahmed HA, Abu-bakr NH, Yahia NA, Ibrahim YE. Root and canal morphology of permanent mandibular molars in a Sudanese population. *Int Endod J* 2007;40:766-71.
19. Al-Nazhan S. Incidence of four canals in root-canal-treated mandibular first molars in a Saudi Arabian sub-population. *Int Endod J* 1999;32:49-52.
20. Reuben J, Velmurugan N, Kandaswamy D. The evaluation of root canal morphology of the mandibular first molar in an Indian population using spiral computed tomography scan: an in vitro study. *J Endod* 2008;34:212-5.
21. Barletta FB, Dotto SR, Reis Mde S, Ferreira R, Travassos RM. Mandibular molar with five root canals. *Aust Endod J* 2008;34:129-32.
22. De Carvalho MC, Zuolo ML. Orifice locating with a microscope. *J Endod* 2000;26:532-4.
23. Vertucci FJ. Root canal anatomy of the human permanent teeth. *Oral Surg Oral Med Oral Pathol* 1984;58:589-99.
24. Navarro LF, Luzi A, García AA, García AH. Third canal in the mesial root of permanent mandibular first molars: review of the literature and presentation of 3 clinical reports and 2 in vitro studies. *Med Oral Patol Oral Cir Bucal* 2007;12:E605-9.
25. Teixeira FB, Sano CL, Gomes BP, Zaia AA, Ferraz CC, Souza-Filho FJ. A preliminary in vitro study of the incidence and position of the root canal isthmus in maxillary and mandibular first molars. *Int Endod J* 2003;36:276-80.
26. Yesilsoy C, Gordon W, Porras O, Hoch B. Observation of depth and incidence of the mesial groove between the mesiobuccal and mesiolingual orifices in mandibular molars. *J Endod* 2002;28:507-9.
27. Baugh D, Wallace J. Middle mesial canal of the mandibular first molar: a case report and literature review. *J Endod* 2004;30:185-6.
28. Gulabivala K, Opananon A, Ng YL, Alavi A. Root and canal morphology of Thai mandibular molars. *Int Endod J* 2002;35:56-62.
29. DeGroot ME, Cunningham CJ. Mandibular molar with 5 canals: report of a case. *J Endod* 1997;23:60-2.
30. Frough Reyhani M, Rahimi S, Shahi S. Root canal therapy of a mandibular first molar with five root canals: A case report. *Iranian Endodontic Journal* 2007;2:110-2.