
Clinical evaluation of forceps eruption: reestablishing biologic width and restoring non restorable teeth.

Akbar Khayat ^{1*} DMD, MS, Shayan Fatehi ² DMD, MS

1. Professor of Endodontics, School of Dentistry, Shiraz University of Medical Sciences, Shiraz- Iran

2. Endodontist, Shiraz, Iran

Abstract

Introduction Complicated crown-root fractures, extended caries and iatrogenic destruction often result in insufficient sound tooth structures and compromise the biologic width. Two common options for re-establishing biologic width are orthodontic extrusion, and the use of the apically positioned flap with osseous surgery. Although some advantages are related to these two options, but coronal movement of gingival and alveolar bone in orthodontic extrusion, esthetic problem and inconsistent topography between the involved tooth and the adjacent teeth following osseous surgery are the major disadvantages of these two approaches. The purpose of this investigation was to evaluate clinically as well as radiographically the effect of surgical extrusion upon the surrounding root structures.

Materials and Methods The material consisted of 21 developed single roots(1 upper and 3 lower) surgically extruded in 17 patients(15 male and 2 female mean age 26 years, ranging 10-40). The indication for surgical extrusion was in 15 cases complicated crown root fracture and in 6 cases early loss of the crown due to an extensive decay. The roots were used where there were completed root developments and the apical fragments were long enough to accommodate a post retained crown. Preoperative radiograph as well as photograph was taken and the clinical and radiographic findings were monitored. The roots were transplanted in their socket in order to re establish the biologic width. Fixation was carried out with a suture splint and/ or periodontal dressing for 7 days. Recall radiographs were taken at 1 and 4 weeks and at 3 month intervals over a 12- month period.

Results Clinically none of the material of 21 teeth demonstrated ankylosis, abnormal mobility and sensibility to percussion or palpation radiographically, PDL healing at 12- month follow up was found in 20 teeth (95.2%).

Conclusion Successful results up to the time of evaluation encouraged further use of surgical extrusion. Long term evaluation is recommended.

Keywords: Biologic width, Extrusion, Forceps eruption.

Received July 2004; accepted December 2004

* Correspondence: Dr Akbar Khayat, Endodontic Dept School of Dentistry, Shiraz University of Medical Sciences, Shiraz, Iran. Email: Khayata@sums.ac.ir

Introduction

To perform a coronal restoration of a tooth with a complicated crown- root fracture or in the case with an extended caries, it is often necessary to re-establish the biologic width for the placement of restorative margin. Orthodontic extrusion and

apically positioned flap and osseous surgery are two commonly used options to re-establish the biologic width. Orthodontic extrusion methods were introduced in 1973 by Heithersay (1). Although orthodontic extrusion is reported with

suitable results, it has been demonstrated that this method leads to a coronal movement of the marginal gingiva and alveolar bone (2-5). Additionally, the relapse of the root following orthodontic extrusion is a common finding as a result of stretched state of marginal periodontal fibers. Many authors advocated periodontal surgery and supracrestal fiberotomy in order to remove displaced tissues, and prevent relapse of tooth intrusion (6-8).

Apically positioned flap and osseous surgery is another method to re-establish the biologic width. This technique has also limitations, and should be used where the surgery does not compromise the esthetic result (9). Forceps eruption or intra-alveolar transplantation- the other option to re-establish biologic width- was introduced in 1978 by Tegsjö et al (10) and was further developed by Bühler (11) and Kahnberg (12). Forceps eruption is relatively simple, and enables transplantation of the root in its socket to a supragingival position, including rotation. In this method, the time factor for transplantation is most critical for the success of treatment, and prognostically can be compared with immediate replantation of the teeth (13-14). In forceps eruption, the root does not leave the socket. If the root has been removed for any reason such as inspection, maximum extra oral time does not exceed two minutes, and potential deleterious effect of extra-oral time for dryness of the periodontal cells is eliminated (15). The purpose of this study was to show clinically as well as radiographically the healing of supporting root tissues after immediate replantation by forceps eruption.

Materials and Methods

The material included 21 single roots (18 upper and 3 lower) in 17 patients (15 males, 2 females) who were referred to the department of endodontics in Shiraz University Dental School because of complicated crown- root fracture or extensive caries. The patients' ages ranged from 10 to 40 years (mean of 26 years). The roots needed transplantation in order to re-establish the biologic width.

To re-establish the biologic width, surgical extrusion as an alternative to orthodontic extrusion or periodontal surgery was selected and offered to the patients. After obtaining informed consent, all the cases were scored photographically. Periapical radiography was carried out; using

standardized parallel techniques (24x 36 mm film). The roots were used where there were completed root development and the apical fragments were long enough to accommodate a post-retained crown. Endodontic treatment was performed previously or was carried out prior to forceps eruption. After anesthesia with 2% lidocaine 1:100000 epinephrine, luxation and extrusion of the roots were performed with a fine elevator after extirpation of the covering soft tissue. The extracted root was then inspected for incomplete fractures which would contraindicate the treatment plan. In the case of palatally inclined fracture, where the fracture line slanted towards the palatal or proximal sides and the level of the gingiva was more apical at the buccal side, the roots were rotated and placed to an appropriate position (Fig1. A, B, C and D). Immobilization of the roots in their new position was secured by simple interrupted interproximal sutures and / or surgical dressing.

Postoperative controls, including standard radiograph, clinical examination with probe and percussion as well as mobility tests were performed in weeks 1 and 4, months 3 and 6, up to 1 year after the surgery. Three different types of root resorption were radiographically described and recorded, as defined by Andreasen (16):

1. Surface resorption,
2. Replacement resorption,
3. Inflammatory resorption.

Radiographic examination for periapical lesion, root resorption, marginal bone loss and signs of ankylosis was performed. In the clinical follow-up, a metal percussion sound indicated ankylosis, and the loosening grade was controlled by means of a mobility test based on a scale of 0-3 (grade 0: no abnormal mobility; grade 1: abnormal horizontal mobility of not more than 1mm; grade 2: abnormal horizontal mobility of more than 1mm; grade 3: abnormal horizontal mobility of more than one millimeter and axial mobility) (17). A completely successful result was recorded when the tooth was in function and no clinical signs of ankylosis, percussion, palpation or abnormal mobility and radiographic signs of root resorption, periapical pathology or crestal bone resorption were present. Preoperative and postoperative radiographic and clinical data were monitored and compared with those taken previously (Fig2. A, B, C, D, E and F). Only the teeth with a minimum follow-up period of 1 year were included in this study.

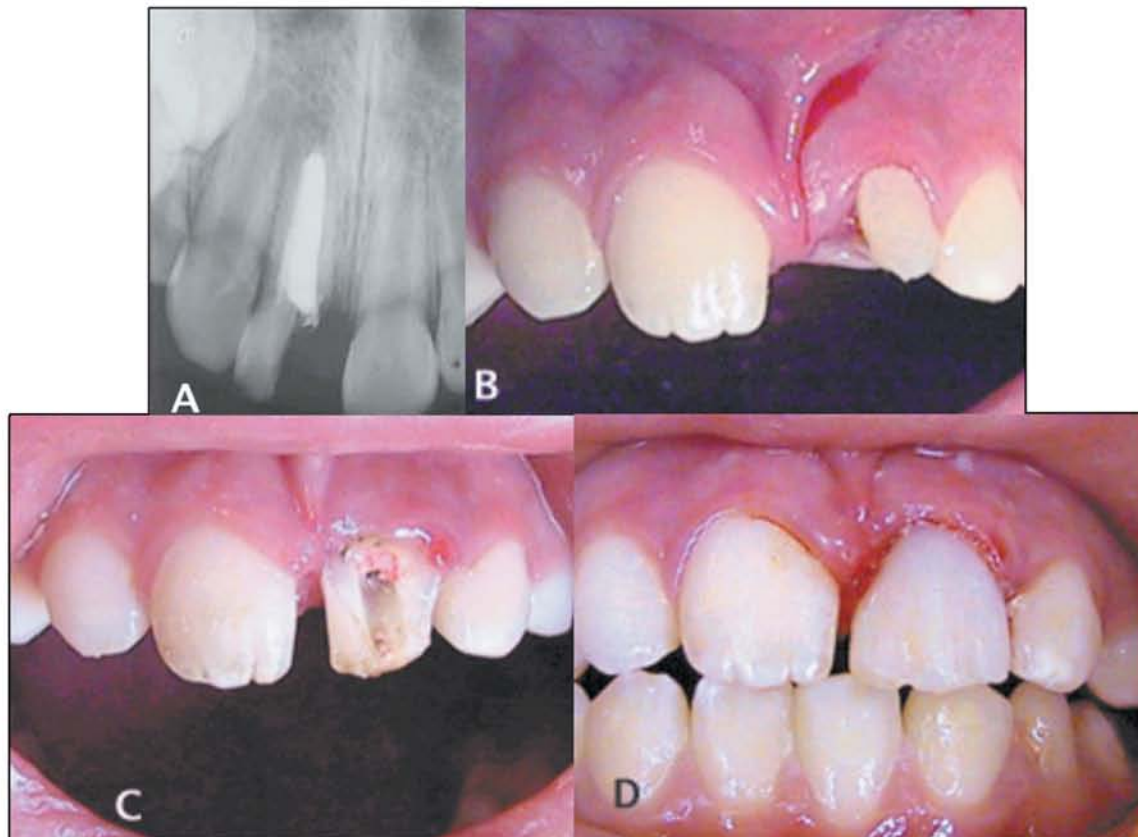


Fig.1. A complicated crown-root fracture on tooth 9 in a 10-year-old Afghanian boy. **A** and **B.** Radiographic and photographic of oblique crown- root fracture below the marginal bone mesial on tooth 9. **C.** The root is rotated 90 degree (mesial aspect at the labial aspect) and transplanted. **D.** After placement of the resin core builds up.

Results

Table 1 shows supporting tissue healing related to various clinical and radiographic factors. Clinically, none of the material of 21 teeth demonstrated ankylosis, abnormal mobility and sensibility to percussion or palpation. Radiographically, PDL healing at 12-month follow-up was found in 20 teeth (95.2%). 4 teeth (19%) showed crestal bone resorption ranging between 1-3 mm.

Discussion

The result of forceps eruption so far shows that all the teeth functioned with normal mobility and no sensibility to percussion and palpation was present. Complete bone formation was also found in all cases (100%) after 6 months. This phenomenon indicated that damaged tissue left in the socket could be healed by the source of undifferentiated cells, careful tissue handling, immobilization of the root and wound edges

closer which are all factors to reduce the risk of infection. PDL healing was demonstrated in 95% of the roots. This finding is paralleled by the findings following immediate replantation of avulsed teeth in which 85-97% rate of PDL healing is demonstrated (18).

In this study, none of the cases demonstrated ankylosis. This is a predictable good result after stabilization with a periodontal dressing and/or suture splint and is parallel with other findings (19) which indicated that auto transplantation following fixation with a suture splint for a week was more successful than with an extended and rigid fixation.

In the present study, the results are in agreement with a similar study evaluating the same parameters following surgical extrusion, performed by Tegsjo et al (20) and Kahnberg (21), in which PDL healing with no or slight root resorption (surface resorption) had been year mean observation time follow-up, a high occurrence of periapical healing (95%)

Table. Clinical and radiographic signs of supporting tissue healing at different interval times.

Observation period month	1	3	6	12
No of teeth	21	21	21	21
Mobility	-	-	-	One grade I
Ankylosis	-	-	-	-
Percussion	-	-	-	-
Palpation	-	-	-	-
Complete bone formation	10	16	21	21
PDL healing	10	15	20	20
Crestal bone resorption	3	4	4	4

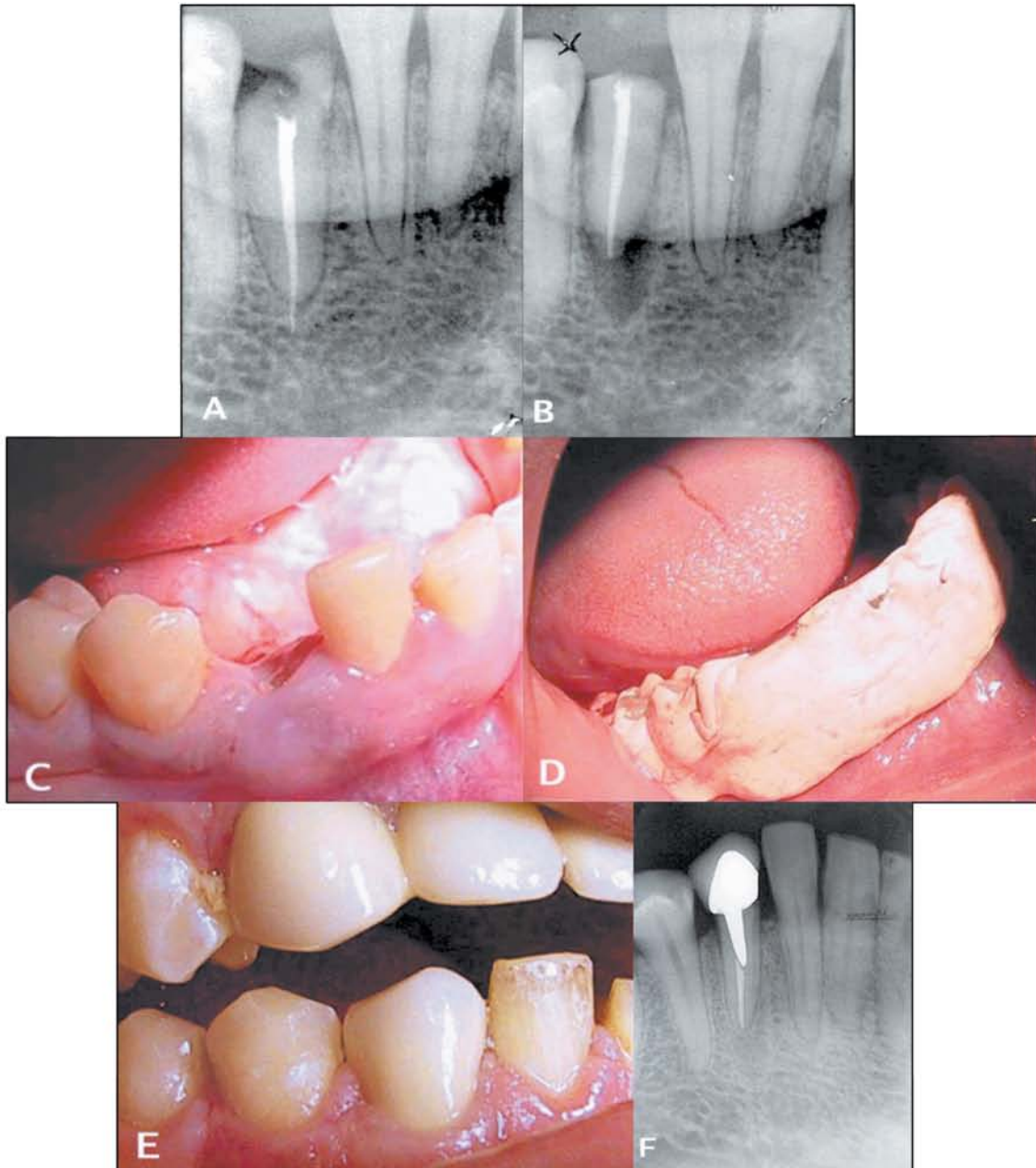


Fig 2-A. Preoperative radiograph appearance of a crown- root fracture on tooth 27 **B.** Radiograph appearance following eruption **C.** Preoperative photograph of crown- root fracture **D.** Surgical dressing is placed for stabilizing **E.** After placement of the ceramic core build-up **F.** No sign of root resorption is seen 12 months after transplantation.

and regeneration of PDL was found (74.3%). Crestal bone resorption was seen radiographically in 4 roots, and clinically a pathological pocket was found in only one instance. This phenomenon was seen at the mesial corner and probably was due to pressure applied by the elevator.

In conclusion, we observed that a careful immediate forceps eruption had many advantages and could be considered as an alternative to extraction. Long-term evaluations are suggested to be performed.

Acknowledgment

This study was supported in part by a grant (83-2058) from Shiraz University of Medical Sciences, Shiraz, Iran.

References

1. Heithersay GS. Combined endodontic-orthodontic treatment of transverse root fractures in the region of the alveolar crest. *Oral Surg* 1973; 36:404-15.
2. Reitan K. Clinical and histological observations on tooth movement during and after orthodontic movement. *Am J Orthod* 1967; 53:721-45.
3. Simon JH, Lythgoe JB, Torabinejad M. Clinical and histological evaluation of extruded endodontically treated teeth in dogs. *Oral Surg Oral Med Oral Pathol* 1980; 50:361-71.
4. Oppenheim A. Artificial elongation of teeth. *Am J Orthod Oral Surg* 1940; 26:931-40.
5. Reitan K. Initial tissue behavior during apical root resorption. *Angle Orthod* 1974; 44:68-82.
6. Kozlovsky A, Tal H, Lieberman M. Forced eruption combined with fiberotomy. A technique for clinical crown lengthening. *J Clin Period* 1988; 15:534-38.
7. Pontoriero R, Celenza F, Ricci G, Carnevale G. Rapid extrusion with fiber resection: a combined orthodontic-periodontic treatment modality. *Int J Period Rest Dent* 1987; 5:31-43.
8. Malmgren O, Malmgren B, Frykholm A. Rapid orthodontic extrusion of crown root and cervical root fractured teeth. *Endod Dent Traumatol* 1991; 7:49-54.
9. Nevins M, Mellonig JT. Clinical approaches and evidence of success, vol 1. Periodontal therapy, Chicago: Quintessence 1998.
10. Tegsjo U, Valerius-Olsson H, Olgart K. Intra-alveolar transplantation of teeth with cervical root fractured teeth. *Swed Dent J* 1978; 2:73-82.
11. Buhler H. Intraalveolar transplantation von Einzel wurzeln. *Quintessence Int* 1987; 38:1963-70.
12. Kahnberg K-E, Warfvinge J, Birgersson B. Intraalveolar transplantation (1). The use of autologous bone transplants in the periapical region. *Int J Oral Surg* 1982; 11:372-9.
13. Andreasen Jo. Pvation of permanent teeth due to trauma. A clinical and radiographic follow-up study of 189 injured teeth. *Scand J Dent Res* 1970; 78:273-86.
14. Andreasen Jo. Traumatic injuries of the teeth. Munksgaard: Copenhagen, 1972; 97:117.
15. Soder Po, Ottosko GP, Andreason Jo, Modeer T. The effect of drying on the viability of periodontal membrane. *Scand J Dent Res* 1977; 84:164-8.
16. Andreasen Jo. The effect of splinting upon periodontal healing after replantation of permanent incisors in monkeys. *Acta Odontol Scand* 1975; 33:313-23.
17. Andreasen Jo, Paulsen HU, Yu Z, Ahlquist R, Bayer T, Schwartz O. A long-term study of 370 autotransplanted premolars. Part I. Surgical procedures and standardized techniques for monitoring healing. *Eur J Orthod* 1990; 12:3-13.
18. Andreasen JO, Borsum MK, Jacobsen HL, Andreasen FM. Replantation of 400 avulsed Permanent incisors. 4. Factors related to periodontal healing. *Endod Dent Traumatol* 1995; 11:76-89.
19. Bauss O, Schilke R, Fenske G, Engelke W, Kiliaridis S. Auto transplantation of Immature third molars: Influence of different splinting methods and fixation periods *Endod Dent traumatol* 2002; 18:322- 8.
20. Tegsjo U, Valerius-Olsson H, Frykholm MH, Olgart K. Clinical evaluation of intra-alveolar transplantation of teeth with cervical rootfractures. *Swed Dent J* 1987; 11:235-50.
21. Kahnberg K-E. Surgical extrusion of root fractures teeth. A follow-up study of two surgical methods. *Endod Dent traumatol* 1988; 4:85-9.