

Comparison of portal hypertensive gastropathy and gastric antral vascular ectasia: an update

Mohsen Rajabnia¹, Behzad Hatami¹, Pardis Ketabi Moghadam¹, Mahsa Mohammadi¹, Mitra Rafizadeh², Forogh Mangeli², Mobin Fathi¹, Ali Jahanian¹

¹Gastroenterology and Liver Diseases Research Center, Research Institute for Gastroenterology and Liver Diseases, Shahid Beheshti University of Medical Sciences, Tehran, Iran

²Taleghani Hospital, Shahid Beheshti University of Medical Sciences, Tehran, Iran

ABSTRACT

Portal hypertensive gastropathy (PHG) and gastric antral vascular ectasia (GAVE) are two distinct entities that are frequently mistaken with each other, because they present with similar manifestations. This issue may cause catastrophic outcomes, as each one of them has a unique pathophysiology, thereby making their management approaches completely different. There are clinical clues that help physicians distinguish these two. Direct vision via upper endoscopy is often mandatory to establish the diagnosis, and sometimes biopsy is required. In this review, we sought to discuss different aspects of both conditions and highlight clinical evidence that may help in identifying and managing the disease appropriately.

Keywords: Portal hypertensive gastropathy, Gastric antral vascular ectasia, Portal hypertensive.

(Please cite as: Rajabnia M, Hatami B, Ketabi Moghadam P, Mohammadi M, Rafizadeh M, Mangeli F, et al. Comparison of portal hypertensive gastropathy and gastric antral vascular ectasia: an update. *Gastroenterol Hepatol Bed Bench* 2022;15(3):204-218).

Introduction

Portal hypertensive gastropathy (PHG) and gastric antral vascular ectasia (GAVE) are two conditions occurring in the gastric mucosal and submucosal tissue that share many similar features, making them difficult to differentiate, especially in the presence of liver cirrhosis (1, 2). The ability of physicians to distinguish between these two entities significantly affects the clinical outcomes, as their management and therapeutic plans are different (3).

PHG is a result of portal hypertension due to cirrhotic and non-cirrhotic causes characterized by a fine, white, mosaic-like pattern separating areas of pinkish mucosa, giving the gastric mucosa a snakeskin

appearance (4). The most common diseases that may cause portal hypertension and subsequent PHG are liver cirrhosis, hepatic schistosomiasis, and portal vein thrombosis (5). GAVE, on the other hand, is characterized by longitudinal rows of flat, reddish stripes radiating from the pylorus into the antrum, resembling the stripes on a watermelon (watermelon stomach). Although the exact physiopathology of GAVE is currently unknown, it is often considered as accompanying systemic diseases, such as liver cirrhosis, autoimmune connective tissue disorders like systemic sclerosis, bone marrow transplantation, and chronic renal failure (6).

In this review, we sought to explain each of these conditions and highlight the characteristic features that help physicians correctly diagnose and select appropriate treatments for them. We mention different aspects of the two entities, and we discuss suggested ways to differentiate between them.

Received: 04 May 2022 Accepted: 01 July 2022

Reprint or Correspondence: Ali Jahanian, Gastroenterology and Liver Diseases Research Center, Research Institute for Gastroenterology and Liver Diseases, Shahid Beheshti University of Medical Sciences, Tehran, Iran.

E-mail: alijahanian1998@yahoo.com

ORCID ID: 0000-0002-8580-3560

Epidemiology

PHG is most likely to present in patients who suffer from chronic liver disease. According to studies, the prevalence of PHG varies greatly from 20% to 75% in patients with portal hypertension and may reach 100% in cirrhotic patients (7). Some studies have shown that PHG has a higher prevalence in patients with advanced disease, higher Child-Pugh scores, and a history of or current esophageal varices (EVs). Collectively, studies suggest that the higher prevalence of PHG in more advanced diseases may be related to the severity of portal hypertension in these patients (4, 8-11). There is no certain factor to predict the development of PHG; however, it is suggested that cirrhotic patients who undergo EV obliteration may have a greater chance of developing PHG (12). Moreover, *Helicobacter pylori* (*H. pylori*) infection may be a predictor of PHG formation and progression (13-15). There is limited reliable data indicating the demographic distribution of PHG, but it is considered to be the same as portal hypertension, which can be seen in all ages.

GAVE is a rare cause of upper gastrointestinal bleeding (UGIB), but it may cause fatal blood loss, especially among the elderly with multiple comorbidities (16). Most patients presenting with GAVE are female with an average age of 73 (17).

Etiology and pathophysiology

PHG is a consequence of portal hypertension which may develop through cirrhotic and non-cirrhotic medical conditions (18). Cirrhosis is the prototypical cause of portal hypertension. During the process of cirrhosis, fibrosis causes architectural distortion of the liver tissue, which leads to intrahepatic vascular resistance. Moreover, the combination of a hyperdynamic circulatory state and increased plasma volume leads to portal venous inflow. An increase in both intrahepatic vascular resistance and portal venous inflow in cirrhotic patients contributes to the development of portal hypertension (19, 20). Some factors such as the severity of liver disease, etiology of portal hypertension, and coexisting gastric varices may influence the development of PHG in patients with portal hypertension, but intravariceal pressure is not directly correlated with PHG (21).

The most important post-hepatic causes of non-cirrhotic portal hypertension are Budd-Chiari syndrome and cardiac diseases. When there is no clinical evidence of any underlying disease, the condition is called idiopathic non-cirrhotic portal hypertension (22, 23).

Although the exact mechanism of PHG formation is not clear, the presence of portal hypertension seems to be mandatory in the process (21, 24); however, it may not be the sole factor in the process, regarding the fact that many patients with portal hypertension do not develop PHG (25, 26). Hemodynamic changes that happen in portal circulation affect gastric mucosal blood flow in a hyperdynamic way that may lead to mucosal congestion (27). Hyperdynamic gastric circulation is described as a state of increased gastric blood flow and, most likely, decreased gastric mucosal flow (28). Furthermore, it alters gastric microcirculation by dilation of small gastric blood vessels, including arterioles and submucosal veins, with a decrease in arteriovenous resistance and straightening of arterioles (29). These changes may result in the release of cytokines and factors that exacerbate this hyperdynamic gastric circulation (30). The roles of free radicals, vascular endothelial growth factor (VEGF), tumor necrosis factor alpha (TNF- α), nitric oxide (NO), prostaglandin E2 (PGE2), and prostacyclin have been suggested in the process (31-36). Moreover, these proinflammatory factors impair the gastric mucosal healing system, predisposing it to injury (37-39). Thus, this fragile and vulnerable mucosa may be a possible site of bleeding in cirrhotic patients (7, 40, 41).

GAVE is usually an isolated lesion, but it may accompany some autoimmune and connective tissue diseases or liver cirrhosis (2, 42, 43). Liver cirrhosis is found in 30% of GAVE patients (44). Among autoimmune diseases, Reynaud's phenomenon and sclerodactyly are the most common conditions that may be found with GAVE. Other autoimmune and connective tissue diseases include Sjogren's syndrome, systemic lupus erythematosus (SLE), primary biliary cirrhosis (PBC), and systemic sclerosis (SSc). Some other conditions may be complicated by GAVE such as bone marrow transplantation, chronic kidney disease (CKD), ischemic heart disease, hypertension, valvular heart disease, familial Mediterranean fever, and acute myeloid leukemia (6, 42).

Studies on the pathophysiological factors involved in non-cirrhotic GAVE formation are lacking, and most studies explore GAVE in cirrhotic patients. The exact pathophysiology of GAVE is not clear and remains controversial in many aspects; however, unlike PHG, the role of portal hypertension in the process of GAVE formation seems to be minimal, as evidence has shown no correlation between the degree of portal hypertension and the severity and prevalence of GAVE (45). Moreover, treatments that reduce portal hypertension are ineffective in the amelioration of GAVE-related presentations (46). Regardless of the presence of portal hypertension, liver cirrhosis is an important comorbidity in GAVE patients which is considered to be involved in the formation of GAVE, as liver transplantation, which is the ultimate cure for cirrhosis, can also cure GAVE (44, 47). Although gastric neuroendocrine dysfunction is the main suggested theory for GAVE, there are numerous controversies regarding the hormonal and neural underlying process of GAVE formation. Some studies have demonstrated an association between GAVE and achlorhydria, raised levels of gastrin, and low levels of pepsinogen (17, 45). In contrast, another study has shown a link between GAVE and low gastrin levels (2). It is known that gastrin is a vasodilating hormone, and further studies are required to identify its role in GAVE (48). The same role is considered for PGE₂, and a study has shown a correlation between the presence of GAVE and high levels of PGE₂ in cirrhotic patients (49). Another suggested condition that leads to GAVE is abnormal antral motility and the following mechanical stress that may cause damage (50). Further studies are needed to clarify the role of each mentioned factor and other possible factors involved in the pathogenesis of GAVE.

Conclusively, the presence of portal hypertension is mandatory for the diagnosis of PHG, whereas GAVE is not considered related to portal hypertension. GAVE is also present in some autoimmune connective tissue diseases that rarely cause portal hypertension and subsequent PHG. However, the fact that both of these conditions may accompany liver cirrhosis causes confusion and misdiagnosis, which can be minimized by their features discussed below.

Clinical manifestations

PHG is usually asymptomatic and is detected mostly during upper endoscopy for other reasons, such

as screening for esophageal varices (51). It may also present by upper gastrointestinal bleeding (UGIB). The extent of bleeding varies vastly, as it may cause acute UGIB that destabilizes patients hemodynamically, or it may cause chronic occult blood loss that presents by iron-deficiency anemia (IDA), which is the more common presentation. It is believed that the severity of symptoms is correlated to the extent and severity of PHG lesions (10, 11, 52).

Similarly, GAVE is mostly asymptomatic and labeled as an accidental finding during upper endoscopy (53). It is, however, an uncommon cause of UGIB which, If it occurs in the setting of a known liver cirrhosis, may be confused with PHG, because like PHG, the severity and chronicity of the bleeding vary greatly (54, 55). Therefore, it seems that there is no clear line distinguishing GAVE from PHG, and upper endoscopy is mandatory for establishing the underlying pathology (16).

Diagnosis

As mentioned earlier, the main challenge that physicians face in the approach to PHG and GAVE is discriminating one from the other. Although upper endoscopy is sufficient for the diagnosis in most cases, histopathologic examination of the tissue specimens obtained during endoscopy is sometimes required to eliminate ambiguity and lead to an appropriate therapeutic plan (3).

Endoscopic features

PHG mainly occurs in the body and fundus, whereas GAVE is found mostly in the antrum. This rule is not absolute, however, as there are exceptions of severe PHG that involves the antrum as in addition to GAVE lesion whose stripes continue into the body and even the fundus (56).

The endoscopic appearance of PHG is typically defined as a “snakeskin mosaic” pattern which consists of fine, white, reticular lines that separate areas of pink-to-reddish mucosa (Figure 1) (12). This mosaic pattern is not typically present in GAVE patients, who usually have raised or flat stripes of ectatic vascular tissue on endoscopy (Figure 2), but a minority of them may show diffusely scattered spotty lesions (17). Similarly, some patients with severe PHG may present with fine pink speckling, superficial reddening, red-point lesions,

cherry-red spots, isolated red marks, or confluent red marks (57). When PHG presents with these flat or bulging red spots, it resembles vascular ectasias that can also be found in the minor subtype of GAVE.

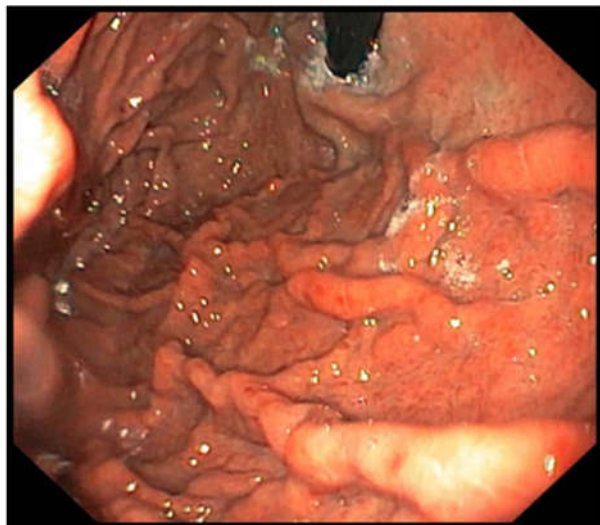


Figure 1. The endoscopic view of PHG. The pale, pinkish mucosa of the stomach is divided into small polygonal areas by fine, white lines. Also there are some red spot lesions that may be confused with GAVE if there was no typical snakeskin pattern.

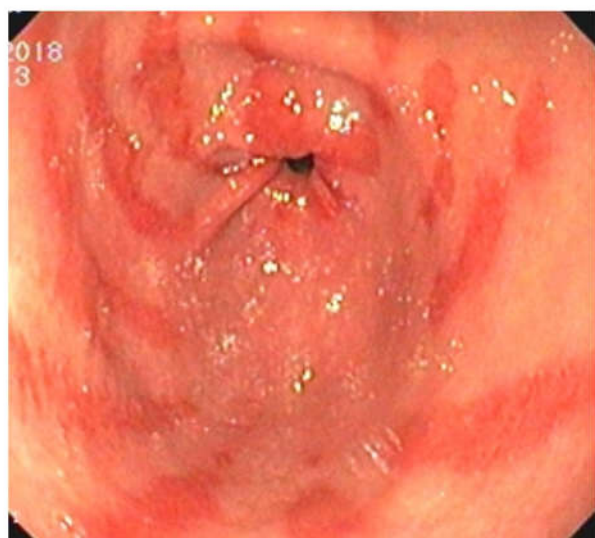

Figure 2. The typical endoscopic view of GAVE. The red, flat stripes of ectatic vessels radiating from pylorus into the antrum is the most common view observed in most of the GAVE cases.

Histopathologic features

When endoscopic features and clinical findings are ambivalent, histopathologic studies are helpful. This situation is more likely when red spots are detected on the upper endoscopy of a patient who presents with

UGIB, especially if the patient gives a history of liver cirrhosis and portal hypertension. The histologic pattern of PHG is totally different from that of GAVE (58).

Typical histologic findings in PHG include dilation of submucosal and mucosal veins and venules and dilated capillaries (3). The absence of any evidence of an inflammatory process or thrombi in PHG differentiates it from gastritis. These dilated vessels give the gastric mucosa an edematous appearance (Figure 3) (59). Moreover, increases in size, length, and count of gastric glands, capillary congestion, and inflammatory cell infiltration are also seen, despite the absence of an active inflammatory process (60). Some degrees of intestinal metaplasia and mucosal atrophy may also be seen (Figure 4) (61).

GAVE seems to have enough distinct characteristics to be differentiated from other antral pathologies (Figure 5) (62). It is defined by its ectatic vascular nature, thrombosed capillaries in the lamina propria, and the associated reactive fibromuscular hyperplasia (63). Moreover, GAVE is described by spindle cell proliferation and fibrohyalinosis (2).

Despite the definite diagnosis that histologic studies may provide, endoscopic gastric mucosal biopsy should be avoided as much as possible, especially in liver failure. The coagulopathy that is a consequence of cirrhosis can sometimes cause massive bleeding in these patients (64, 65). Moreover, many of these patients are undergoing endoscopy due to UGIB, and during bleeding, loss of coagulation factors may worsen the coagulopathy (66). Thus, biopsy should be avoided or obtained cautiously in times of desperate necessity (67). A promising novel method that may obviate the need for biopsies is virtual chromoendoscopy, is a technique of using dyes during endoscopy to distinguish the pathologies of gastric mucosa; however, larger studies are required to prove its advantages (68).

Management

Because PHG and GAVE are different entities in terms of pathophysiology, their management is also different. As PHG is a consequence of portal hypertension, its treatment and prophylaxis focus on reducing portal vein pressure and correcting possible cirrhotic complications (12, 56, 69). On the other hand,

portal hypertension is irrelevant in GAVE. The approach to GAVE is more endoscopic and tends to

diagnose and treat the underlying disease that might cause it (6, 70).

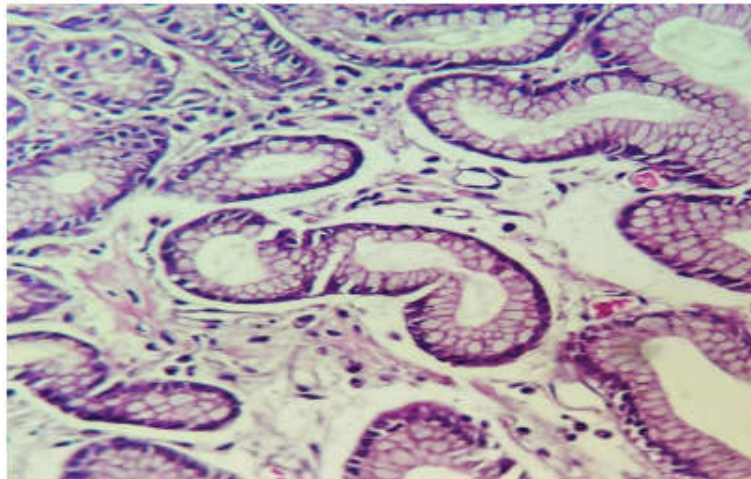


Figure 3. Portal hypertensive gastropathy. Numerous dilated mucosal capillaries impart an edematous appearance to the mucosa.

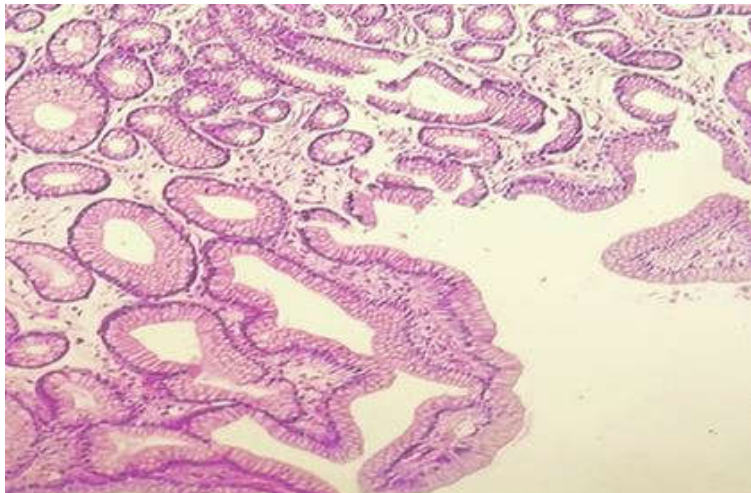


Figure 4. Portal hypertensive gastropathy. Foveolar hyperplasia, regeneration, edema, and a paucity of inflammation, all of which resemble reactive (chemical) gastropathy.

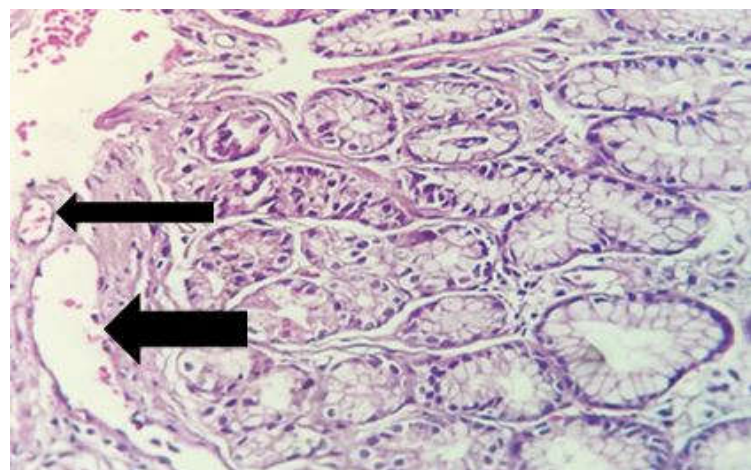


Figure 5. Histology of GAVE. Gastric antral mucosa with mildly edematous lamina propria devoid of inflammation, revealing dilated and mildly congested capillaries that the diameter of the lumen approximates the diameter of antral mucosal glands (arrows).

The common principle in the management of both PHG and GAVE is that the initial approach to UGIB should be applied, as both of them present with this manifestation. For acute UGIB, the physician must consider intravenous fluid resuscitation, red blood cell transfusion, proton pump inhibitors (PPIs), antibiotics (e.g., ceftriaxone), vasoactive agents, and early endoscopy, as indicated (71, 72). In the case of chronic UGIB, because it usually presents with iron deficiency anemia, iron repletion is mandatory, and in cases of severe anemia, red blood cell transfusion may be required (73-75). Moreover, patients should be advised to avoid substances that may cause gastric mucosal damage such as aspirin and alcohol.

Management of PHG

The cornerstone of treating PHG is the reduction of portal blood pressure. Many ways are available to physicians to achieve this, but the preferred method is pharmacotherapy (69). The main complaint that mandates the treatment of PHG is UGIB, which may be either acute or chronic. There is not much difference in the principles of the treatment, but acute UGIB demands more vigorous action. Acute UGIB due to PHG heralds a more severe pathology. Although rare, PHG can cause hemodynamic instability in the setting of acute UGIB (12). Unlikely, chronic UGIB may be a result of mild or severe PHG (11).

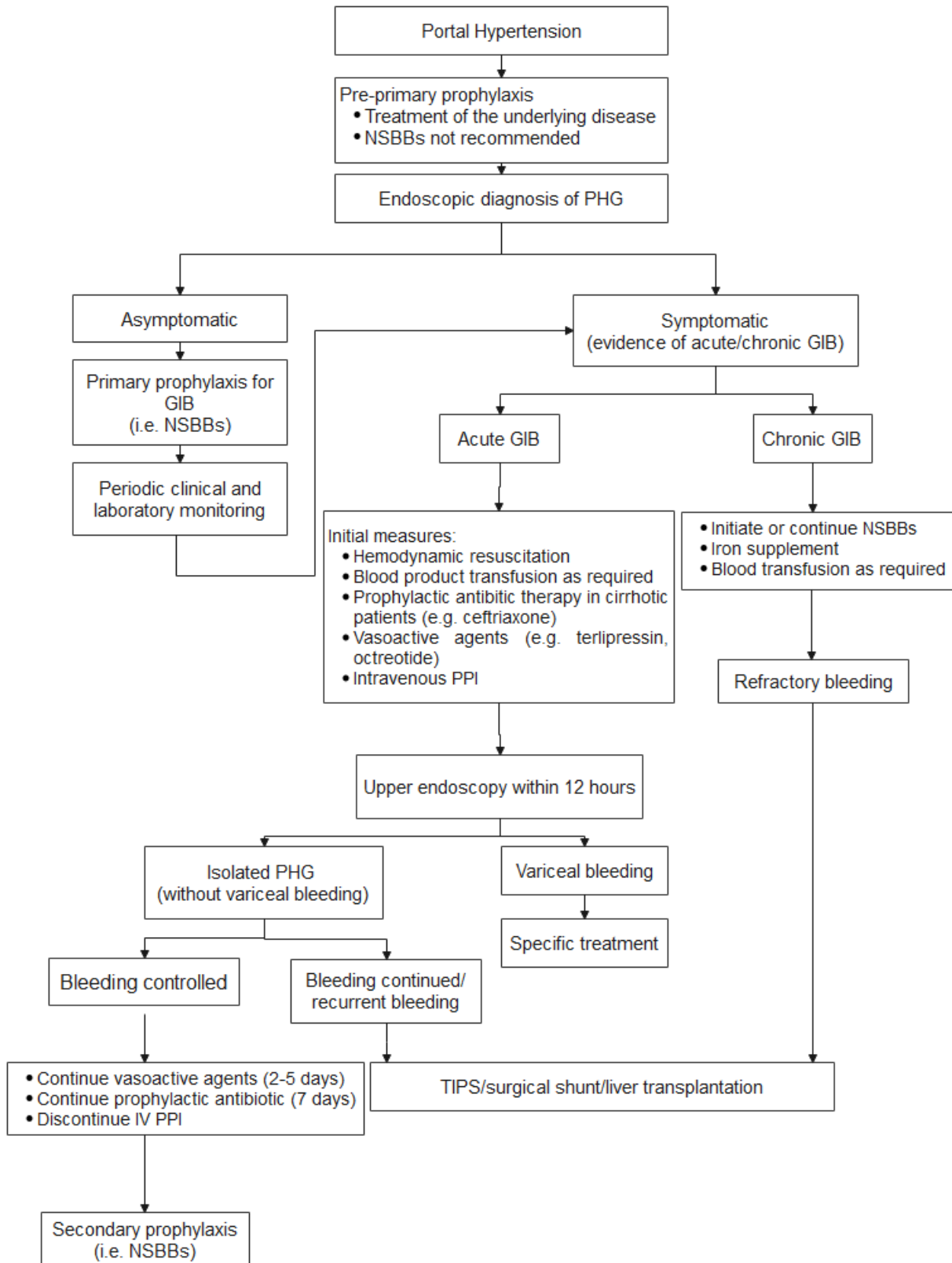
The main class of drugs used to lower portal hypertension and treat PHG are non-selective β -blockers (NSBBs), and among them, propranolol is used most frequently. It is an effective choice in both acute and chronic UGIB. It also appears to be effective in the prevention of bleeding and is prescribed by the time the diagnosis of moderate to severe portal hypertension gastropathy has been established. It is also indicated when patients have simultaneous esophagogastric varices or coagulopathy or any other predisposing conditions precipitating bleeding (76-81). Another suggested NSBB agent is nadolol which has low hepatic metabolism and acceptable efficacy in long-term treatment (82). Carvedilol is a more potent NSBB in decreasing hepatic venous pressure gradient (HVPG) (83). However, its systemic hypotensive effects make it less applicable in long-term use and limit it to acute heavy bleeding (84).

There are some other agents suggested for use in decreasing portal hypertension. Octreotide, a somatostatin analogue, has shown strong therapeutic effects in reducing portal blood pressure (86); however, its numerous adverse effects limit its clinical use (87, 88). Octreotide is generally suggested to be administered when there is acute UGIB, especially with concomitant variceal bleeding (89). Vasopressin and its analog terlipressin reduce portal blood pressure by producing splanchnic vasoconstriction and are useful in the management of acute UGIB (90). However, its high frequency of systemic side effects such as hypertension, cardiac arrhythmias, and vascular ischemia has limited its application (91-93).

Conclusively, the first line of treatment for PHG is the treatment of the underlying disease as a pre-prophylactic step to ablate the process of portal hypertension. When the diagnosis of PHG is established if there is no evidence of bleeding, NSBBs are prescribed as primary prophylaxis (94). The main agents prescribed for chronic UGIB are NSBBs; other agents are not recommended (95). An acute UGIB in the setting of PHG, however, mandates the prescription of vasoactive agents such as octreotide, terlipressin, and somatostatin for two to five days. When the course of vasoactive agents is finished, NSBBs should be initiated for the prevention of recurrent bleeding (81). Moreover, acute UGIB requires intravenous antibiotic (e.g., ceftriaxone) for seven days. PPIs are not necessary in the treatment of PHG and should be discontinued if there is no other reason for them (96-98).

Beside pharmacotherapy, the transjugular intrahepatic portosystemic stent (TIPS) and shunt surgery are other options for reducing portal hypertension. Although they are considered invasive and have a lack of reassuring studies confirming their efficacy, small studies have demonstrated their potential to decrease portal blood pressure and thereby the severity of PHG (99). Because they are associated with significant morbidity and mortality, they are indicated as salvage therapy and a last resort in the setting of a refractory disease with recurrent hemorrhages (Algorithm 1) (100).

210 Comparison of portal hypertensive gastropathy and gastric antral vascular ectasia: an update



Algorithm 1. Management of PHG.

NSBB: Non-selective beta-blocker; PHG: Portal hypertension gastropathy, GIB: Gastrointestinal bleeding; PPI: Proton-pump inhibitor.

Unlike esophagogastric varices that are treated mainly by endoscopic techniques (101), PHG is a diffuse pathology spreading in a vast area of gastric mucosa; thus, focal endoscopic procedures such as thermocoagulation are rarely useful unless a focal site of massive hemorrhage can be detected. A recent study has shown that argon plasma coagulation is more effective in alleviating symptoms compared to NSBB carvedilol, and combined they can produce a synergistic effect (102). There are some case reports of the successful hemostasis of PHG using hemospray, which is a hemostatic agent licensed for endoscopic treatment of non-variceal upper gastrointestinal bleeding (103, 104). This method signals some promising progress in the field of the endoscopic treatment of diffuse bleeding mucosal lesions.

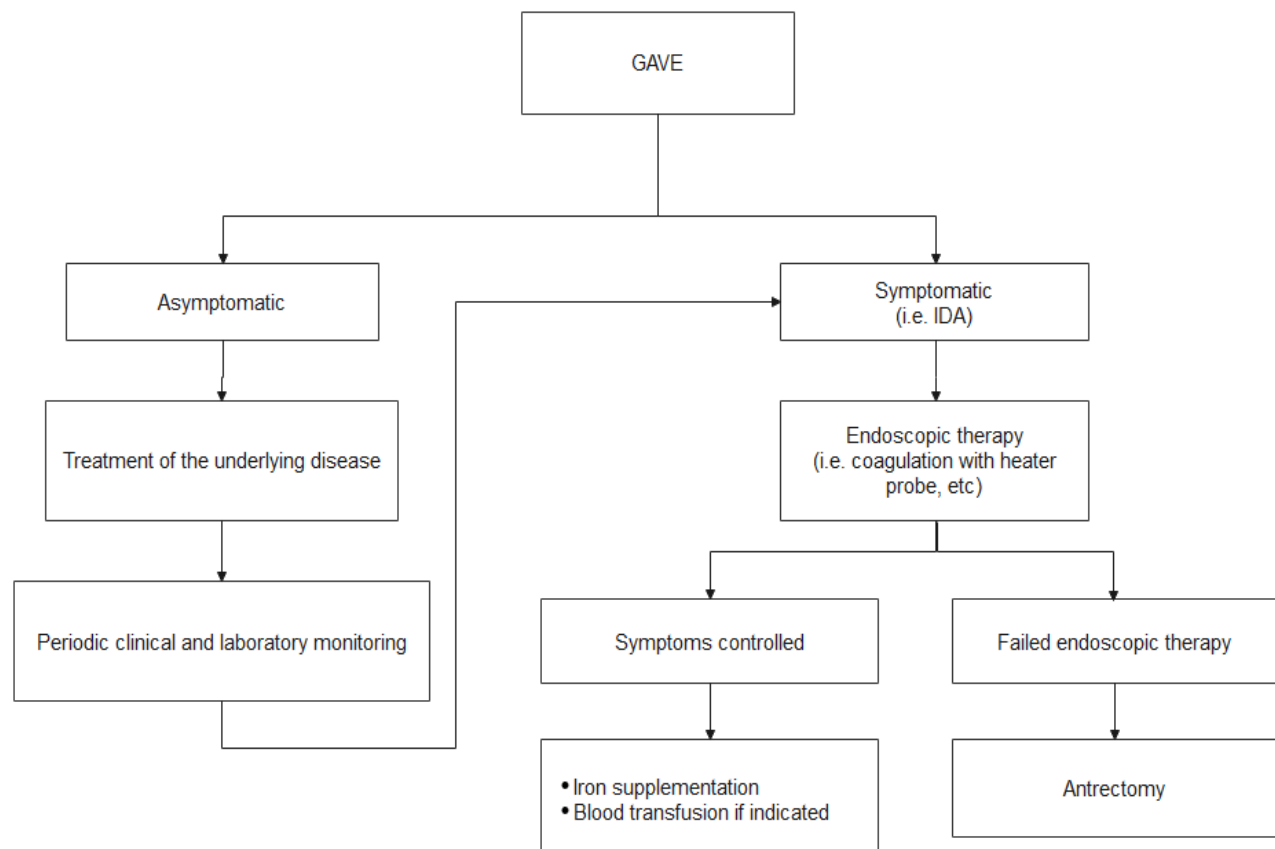
Management of GAVE

Endoscopic intervention is the main treatment for watermelon stomach. Thermal techniques, such as neodymium-yttrium-aluminum garnet laser coagulation (Nd: YAG lasers), cryotherapy, argon plasma coagulation (APC), and radiofrequency ablation (RFA), that can demolish ectatic vessels as well as mechanical methods, such as endoscopic band ligation (EBL), that can destroy the submucosal vessels are available (Algorithm 2) (43, 105). APC is a method in which ionized argon gas (plasma) is used to produce high-frequency electrical current flows to cause tissue coagulation. It is mainly considered as the first-line treatment of GAVE (70). Notably, APC requires several sessions and has high recurrence rates, limiting its utilization (106, 107). Nonetheless, it is an effective tool because of its ease of use, safety, high efficacy, and low costs (108, 109). Nd: YAG laser obliterates the tissue by radiating laser light without any direct contact. Its usage, however, is limited because of the lack of studies supporting its efficacy in the treatment of GAVE (43). RFA is another tool that destroys superficial ectatic capillaries by applying high-energy coaptive coagulation. RFA seems to be an effective tool, especially in cases refractory to APC, but further studies are required to determine its efficacy and side effects (110). As a mechanical method, EBL was initially designed for the treatment of esophageal varices, but its application crossed beyond such cases (111, 112). Recent studies suggest that EBL may be

superior to APC in the treatment of GAVE, because it is inexpensive, widely available, and needs fewer sessions to complete the treatment course. Moreover, it is easy and has acceptable long-term outcomes (113-115). Conclusively, there is a lack of studies concerning which technique is more effective and has better outcomes, and most physicians decide based on the circumstances of the patient and endoscopic unit.

There are some suggestions regarding the pharmacotherapy of GAVE with agents such as octreotide, cyproheptadine, cyclophosphamide, prednisolone, estrogen-progesterone, thalidomide, bevacizumab, and tranexamic acid (116). These medications may be useful in the setting of acute bleeding, and there are case series of their successful application (116). Cyproheptadine, a first-generation antihistamine, seems to have some favorable effects in the reversal of iron deficiency anemia (117). Corticosteroids and immunosuppressive therapy with cyclophosphamide are associated with better outcomes in SSc and may be beneficial in other autoimmune diseases with GAVE (118). There is evidence that considers a role for cyclophosphamide in the treatment of refractory SSc-associated GAVE that does not respond to endoscopic management (119-121). A combination of estrogen and progesterone therapy is another choice that may reduce the chance of bleeding but does not seem to eliminate ectatic vessels, and tapering the regimen may cause recurrent bleeding (122, 123). Moreover, some case reports indicate the successful cessation of bleeding by thalidomide, an angiogenesis inhibitor agent, in patients with refractory lesions to endoscopic treatment (124, 125). Bevacizumab is a monoclonal antibody that has antiangiogenic effects through the inhibition of vascular endothelial growth factor A (VEGF-A) action (126). There is evidence to indicate its potential in reducing the requirement for blood transfusion and endoscopic treatment in GAVE patients (127). Tranexamic acid is also an effective choice to cease acute bleeding. It is an antifibrinolytic agent that acts by preventing fibrin degradation and preserving the structure of clots (128, 129). However, pharmacotherapy does not change the endoscopic appearance of GAVE in most cases and is not generally suggested as the sole therapy (43).

212 Comparison of portal hypertensive gastropathy and gastric antral vascular ectasia: an update



Algorithm 2. Management of GAVE.

GAVE: Gastric antral vascular ectasia; IDA: Iron deficiency anemia.

Table 1. Comparison of PHG and GAVE

	PHG	GAVE
Etiology	portal hypertension	Liver cirrhosis, autoimmune diseases (such as SSc), CKD, etc (not portal hypertension)
Clinical manifestation	Mostly asymptomatic, UGIB (chronic more than acute)	Mostly asymptomatic, UGIB (chronic more than acute)
Usual location	Body and fundus	antrum
Endoscopic appearance	Mosaic or snakeskin pattern or diffuse red to dark brown spots	Columns or stripes of ectatic vessels in the shape of watermelon or diffuse spots
Histology	Dilated submucosal and mucosal veins and ectatic capillaries, without inflammation or thrombi	Vascular ectasia with fibrin thrombi, spindle cell proliferation, fibrohyalinosis and fibromuscular hyperplasia
Management	Reduction of portal hypertension	Thromboablative therapy
Pharmacotherapy	Primary prophylaxis: NSBB Chronic bleeding: NSBB, iron supplements Acute bleeding: vasoactive agents (e.g. octreotide), antibiotics (e.g. ceftriaxone) Secondary prophylaxis: NSBB	Limited value
Endoscopic therapy	Limited value	Heater probe, Bipolar probe, APC, RFA, Nd:YAG laser, EBL
Surgical therapy	Refractory bleeding: TIPS or shunt surgery Definite treatment of cirrhosis: liver transplantation	Antrectomy, gastrectomy

Surgical treatment is another option in the treatment of GAVE, however, it is considered a last resort and salvage therapy in refractory life-threatening conditions (43, 130). Antrectomy, partial gastrectomy, total gastrectomy, and esophagogastrectomy are suggested methods applied mainly when other treatments fail (131). The laparoscopic approach is recommended in most cases and has better outcomes and fewer surgical complications (132). There is a single case report of uncontrolled bleeding that was successfully stopped by intra-arterial embolization (133).

Conclusions

PHG and GAVE may present with the same manifestations (i.e. UGIB), especially in patients with known liver cirrhosis; however, discriminating between the two is pivotal, because their fundamental pathophysiologies differ, and thus they demand different clinical approaches (Table 1).

PHG is a consequence of portal hypertension, whereas GAVE, while still not clear, seems irrelevant to portal hypertension but related to liver failure itself or other underlying medical conditions. When the endoscopic appearance of the stomach of a patient presenting with UGIB contains fine reticular lines that separate the pink mucosa into little areas, the typical PHG view is confirmed.

On the other hand, an endoscopic view showing stripes of reddish mucosa radiating from the pylorus into the antrum indicates a typical pattern of GAVE. A borderline endoscopic pattern may sometimes be seen that is reportedly related to both PHG and GAVE and hinders differentiation between them, for example, diffuse reddish or blackish spots in the field of a congested mucosa. In such situations, a clue is the site of the lesions; PHG tends to appear mainly in the fundus and body, while the antrum is the main site for GAVE formation. Nonetheless, in these equivocal cases, histological studies are helpful. GAVE is defined by its ectatic vascular nature and thrombosed capillaries in the lamina propria and the associated reactive fibromuscular hyperplasia. PHG is described as dilated veins and venules with no evidence of inflammation or thrombi. Reduction of portal blood pressure is the mainstay of the management of PHG and is achieved primarily by NSBBs.

Other possible useful agents include somatostatin analogs, vasopressin analogs, and nitrates; TIPS, thermocoagulation, and shunt surgery are considered salvage therapies. However, GAVE is mainly treated endoscopically by the utilization of APC, RFA, and EBL. A surgical approach is rarely applied as salvage therapy, and pharmacotherapy has limited value in the management of GAVE.

Conflict of interests

The authors have no conflicts of interest to declare.

References

1. Burak K, Lee S, Beck P. Portal hypertensive gastropathy and gastric antral vascular ectasia (GAVE) syndrome. *Gut* 2001;49:866-72.
2. Payen J-L, Calès P, Voigt J-J, Barbe S, Pilette C, Dubuisson L, et al. Severe portal hypertensive gastropathy and antral vascular ectasia are distinct entities in patients with cirrhosis. *Gastroenterology* 1995;108:138-44.
3. Patwardhan V, Cardenas A. The management of portal hypertensive gastropathy and gastric antral vascular ectasia in cirrhosis. *Aliment Pharmacol Ther* 2014;40:354-62.
4. Thuluvath PJ, Yoo HY. Portal hypertensive gastropathy. *Am J Gastroenterol* 2002;97:2973-8.
5. Berzigotti A, Seijo S, Reverter E, Bosch J. Assessing portal hypertension in liver diseases. *Expert Rev Gastroenterol Hepatol* 2013;7:141-55.
6. Selinger CP, Ang YS. Gastric antral vascular ectasia (GAVE): an update on clinical presentation, pathophysiology and treatment. *Digestion* 2008;77:131-7.
7. Gjeorgijevski M, Cappell MS. Portal hypertensive gastropathy: a systematic review of the pathophysiology, clinical presentation, natural history and therapy. *World J Hepatol* 2016;8:231.
8. Tiwari PS, Sudhamshu K, Sharma D, Paudel MS, Mandal A. Prevalence of portal hypertensive gastropathy in chronic liver disease and correlation with the severity of liver disease. *Cureus* 2019;11.
9. Menchén L, Ripoll C, Marín-Jiménez I, Colón A, Gómez-Camarero J, González-Asanza C, et al. Prevalence of portal hypertensive duodenopathy in cirrhosis: clinical and haemodynamic features. *Eur J Gastroenterol Hepatol* 2006;18:649-53.
10. D'Amico G, Montalbano L, Traina M, Pisa R, Menozzi M, Spanò C, et al. Natural history of congestive gastropathy in cirrhosis. *Gastroenterology* 1990;99:1558-64.
11. Merli M, Nicolini G, Angeloni S, Gentili F, Attili AF, Riggio O. The natural history of portal hypertensive gastropathy in patients with liver cirrhosis and mild portal hypertension. *Am J Gastroenterol* 2004;99:1959-65.

214 Comparison of portal hypertensive gastropathy and gastric antral vascular ectasia: an update

12. Cubillas R, Rockey DC. Portal hypertensive gastropathy: A review. *Liver Int* 2010;30:1094-102.
13. Sathar SA, Kunnathuparambil SG, Sreesh S, Narayanan P, Vinayakumar KR. *Helicobacter pylori* infection in patients with liver cirrhosis: prevalence and association with portal hypertensive gastropathy. *Ann Gastroenterol* 2014;27:48-52.
14. El-Dessouky YM, Sekeen MA, El-Morsy GZ, Elsayed AI. Relation between *Helicobacter pylori* infection and severity of portal hypertensive gastropathy in cirrhotic patients. *JRAM* 2021;2:149-57.
15. El-Toukhy N, Omar El-Farouk L, Youssef M. *Helicobacter Pylori* infection is associated with portal hypertensive gastropathy in patients with liver cirrhosis. *AEJI* 2021;11:61-8.
16. Alkhormi AM, Memon MY, Alqarawi A. Gastric antral vascular ectasia: a case report and literature review. *J Transl Int Med* 2018;6:47.
17. Gostout CJ, Viggiano TR, Ahlquist DA, Wang KK, Larson MV, Balm R. The clinical and endoscopic spectrum of the watermelon stomach. *J Clin Gastroenterol* 1992;15:256-63.
18. Bosch J, Iwakiri Y. The portal hypertension syndrome: etiology, classification, relevance, and animal models. *Hepatol Int* 2018;12:1-10.
19. De Franchis R, Primignani M. Natural history of portal hypertension in patients with cirrhosis. *Clin Liver Dis* 2001;5:645-63.
20. García-Pagán J-C, Gracia-Sancho J, Bosch J. Functional aspects on the pathophysiology of portal hypertension in cirrhosis. *J Hepatol* 2012;57:458-61.
21. Sarin SK, Sreenivas DV, Lahoti D, Saraya A. Factors influencing development of portal hypertensive gastropathy in patients with portal hypertension. *Gastroenterology* 1992;102:994-9.
22. Schouten JN, Garcia-Pagan JC, Valla DC, Janssen HL. Idiopathic noncirrhotic portal hypertension. *Hepatology* 2011;54:1071-81.
23. Khanna R, Sarin SK. Non-cirrhotic portal hypertension—diagnosis and management. *J Hepatol* 2014;60:421-41.
24. McCormack T, Sims J, Eyre-Brook I, Kennedy H, Goepel J, Johnson A, et al. Gastric lesions in portal hypertension: inflammatory gastritis or congestive gastropathy? *Gut* 1985;26:1226-32.
25. Bayraktar Y, Balkanci F, Uzunalimoglu B, Gokoz A, Koseoglu T, Batman F, et al. Is portal hypertension due to liver cirrhosis a major factor in the development of portal hypertensive gastropathy? *Am J Gastroenterol* (Springer Nature) 1996;91.
26. Curvêlo LA, Brabosa W, Rhor R, Lanzoni V, Parise ER, Ferrari AP, et al. Underlying mechanism of portal hypertensive gastropathy in cirrhosis: a hemodynamic and morphological approach. *J Gastroenterol Hepatol* 2009;24:1541-6.
27. Thuluvath PJ. Management of upper gastrointestinal hemorrhage related to portal hypertension. *Textbook of Gastroenterology* 2008:2987-3017.
28. Blendis L, Wong F. The hyperdynamic circulation in cirrhosis: an overview. *Pharmacol Ther* 2001;89:221-31.
29. Hashizume M, Tanaka K, Inokuchi K. Morphology of gastric microcirculation in cirrhosis. *Hepatology* 1983;3:1008-12.
30. Ohta M, Yamaguchi S, Gotoh N, Tomikawa M. Pathogenesis of portal hypertensive gastropathy: A clinical and experimental review. *Surgery* 2002;131:165-S70.
31. Kaur S, Kaur U, Tandon C, Dhawan V, Ganguly N, Majumdar S. Gastropathy and defense mechanisms in common bile duct ligated portal hypertensive rats. *Mol Cell Biochem* 2000;203:79-85.
32. Tsugawa K, Hashizume M, Migou S, Kishihara F, Kawanaka H, Tomikawa M, et al. Role of vascular endothelial growth factor in portal hypertensive gastropathy. *Digestion* 2000;61:98-106.
33. Muñoz J, Albillos A, Pérez-Páramo M, Rossi I, Alvarez-Mon M. Factors mediating the hemodynamic effects of tumor necrosis factor- α in portal hypertensive rats. *Am J Physiol Gastrointest Liver Physiol* 1999;276:687-93.
34. Ohta M, Tarnawski AS, Itani R, Pai R, Tomikawa M, Sugimachi K, et al. Tumor necrosis factor α regulates nitric oxide synthase expression in portal hypertensive gastric mucosa of rats. *Hepatology* 1998;27:906-13.
35. Beck PL, McKnight W, Lee SS, Wallace JL. Prostaglandin modulation of the gastric vasculature and mucosal integrity in cirrhotic rats. *Am J Physiol Gastrointest Liver Physiol* 1993;265:453-8.
36. Arakawa T, Satoh H, Fukuda T, Nakamura H, Kobayashi K. Endogenous prostaglandin E2 in gastric mucosa of patients with alcoholic cirrhosis and portal hypertension. *Gastroenterology* 1987;93:135-40.
37. Zardi EM, Ghittoni G, Margiotta D, Viera FT, Di Matteo F, Rossi S. Portal hypertensive gastropathy in cirrhotics without varices: A case-control study. *Eur J Gastroenterol Hepatol* 2015;27:91-6.
38. Perini RF, Camara PR, Ferraz JG. Pathogenesis of portal hypertensive gastropathy: translating basic research into clinical practice. *Nat Rev Gastroenterol Hepatol* 2009;6:150-8.
39. Nayeib-Hashemi H, Kaunitz JD. Gastroduodenal mucosal defense. *Curr Opin Gastroenterol* 2009;25:537-43.
40. Chung WJ. Management of portal hypertensive gastropathy and other bleeding. *Clin Mol Hepatol* 2014;20:1.
41. Ferraz JGP, Wallace JL. Underlying mechanisms of portal hypertensive gastropathy. *J Clin Gastroenterol* 1997;25:73-8.
42. Fuccio L, Mussetto A, Laterza L, Eusebi LH, Bazzoli F. Diagnosis and management of gastric antral vascular ectasia. *World J Gastrointest Endosc* 2013;5:6.

43. Hsu W-H, Wang Y-K, Hsieh M-S, Kuo F-C, Wu M-C, Shih H-Y, et al. Insights into the management of gastric antral vascular ectasia (watermelon stomach). *Therap Adv Gastroenterol* 2018;11:1756283X17747471.
44. Ward EM, Raimondo M, Rosser BG, Wallace MB, Dickson RD. Prevalence and natural history of gastric antral vascular ectasia in patients undergoing orthotopic liver transplantation. *J Clin Gastroenterol* 2004;38:898-900.
45. Quintero E, Pique JM, Bombi JA, Bordas JM, Sentis J, Elena M, et al. Gastric mucosal vascular ectasias causing bleeding in cirrhosis: a distinct entity associated with hypergastrinemia and low serum levels of pepsinogen I. *Gastroenterology* 1987;93:1054-61.
46. Spahr L, Villeneuve J, Dufresne M, Tassé D, Bui B, Willems B, et al. Gastric antral vascular ectasia in cirrhotic patients: absence of relation with portal hypertension. *Gut* 1999;44:739-42.
47. Vincent C, Pomier-Layrargues G, Dagenais M, Lapointe R, Létourneau R, Roy A, et al. Cure of gastric antral vascular ectasia by liver transplantation despite persistent portal hypertension: a clue for pathogenesis. *Liver Transplant* 2002;8:717-20.
48. Guth PH, Smith E. The effect of gastrointestinal hormones on the gastric microcirculation. *Gastroenterology* 1976;71:435-8.
49. Saperas E, Perez Ayuso RM, Poca E, Bordas JM, Gaya J, Pique JM. Increased gastric PGE 2 biosynthesis in cirrhotic patients with gastric vascular ectasia. *Am J Gastroenterol* 1990;85.
50. Charneau J, Petit R, Cales P, Dauver A, Boyer J. Antral motility in patients with cirrhosis with or without gastric antral vascular ectasia. *Gut* 1995;37:488-92.
51. Urrunaga NH, Rockey DC. Portal hypertensive gastropathy and colopathy. *Clin Liver Dis* 2014;18:389-406.
52. Primignani M, Carpinelli L, Preatoni P, Battaglia G, Carta A, Prada A, et al. Natural history of portal hypertensive gastropathy in patients with liver cirrhosis. *Gastroenterology* 2000;119:181-7.
53. Dulai G, Jensen D, Kovacs T, Gralnek I, Jutabha R. Endoscopic treatment outcomes in watermelon stomach patients with and without portal hypertension. *Endoscopy* 2004;36:68-72.
54. Swanson E, Mahgoub A, MacDonald R, Shaukat A. Medical and endoscopic therapies for angiodysplasia and gastric antral vascular ectasia: A systematic review. *Clin Gastroenterol Hepatol* 2014;12:571-82.
55. Kichloo A, Solanki D, Singh J, Dahiya DS, Lal D, Haq KF, et al. Gastric antral vascular ectasia: Trends of hospitalizations, biodemographic characteristics, and outcomes with watermelon stomach. *Gastroenterol Res* 2021;14:104.
56. Rockey DC. An update: Portal hypertensive gastropathy and colopathy. *Clin Liver Dis* 2019;23:643-58.
57. de Macedo GFS, Ferreira FG, Ribeiro MA, Szutan LA, Assef MS, Rossini LGB. Reliability in endoscopic diagnosis of portal hypertensive gastropathy. *World J Gastrointest Endosc* 2013;5:323.
58. Ripoll C, Garcia-Tsao G. The management of portal hypertensive gastropathy and gastric antral vascular ectasia. *Dig Liver Dis* 2011;43:345-51.
59. Ichikawa Y, Tarnawski A, Sarfeh IJ, Ishikawa T, Shimada H. Distorted microangioarchitecture and impaired angiogenesis in gastric mucosa of portal hypertensive rats. *Gastroenterology* 1994;106:702-8.
60. Abbasi A, Naz S, Irshad F. Portal gastropathy; Characteristic histological features of portal gastropathy in liver cirrhosis and its correlation with child-pugh score. *Professional Med J* 2018;25.
61. Ibrism D, Çevikbas U, Akyüz F, Poturoglu S, Ahshal E, Güllüoğlu M, et al. Intestinal metaplasia in portal hypertensive gastropathy: a frequent pathology. *Eur J Gastroenterol Hepatol* 2008;20:874-80.
62. Suit PF, Petras RE, Bauer TW, Petrini Jr JL. Gastric antral vascular ectasia. A histologic and morphometric study of "the watermelon stomach". *Am J Surg Pathol* 1987;11:750-7.
63. Gretz JE, Achem SR. The watermelon stomach: Clinical presentation, diagnosis, and treatment. *Am J Gastroenterol* 1998;93:890-5.
64. Northup PG, Caldwell SH. Coagulation in liver disease: A guide for the clinician. *Clin Gastroenterol Hepatol* 2013;11:1064-74.
65. Kaul V, Munoz SJ. Coagulopathy of liver disease. *Curr Treat Options Gastroenterol* 2000;3:433-7.
66. Bolliger D, Szlam F, Molinaro R, Rahe-Meyer N, Levy J, Tanaka K. Finding the optimal concentration range for fibrinogen replacement after severe haemodilution: an in vitro model. *Br J Anaesth* 2009;102:793-9.
67. O'Leary JG, Greenberg CS, Patton HM, Caldwell SH. AGA clinical practice update: Coagulation in cirrhosis. *Gastroenterology* 2019;157:34-43.
68. Al-Taei AM, Cubillan MP, Hinton A, Sobotka LA, Befeler AS, Hachem CY, et al. Accuracy of virtual chromoendoscopy in differentiating gastric antral vascular ectasia from portal hypertensive gastropathy: A proof of concept study. *World J Hepatol* 2021;13:2168-78.
69. Oho K, ed. Treatment of portal hypertensive gastroenteropathy. *Clinical Investigation of Portal Hypertension*. Berlin: Springer; 2019. p.473-7.
70. Peng M, Guo X, Yi F, Shao X, Wang L, Wu Y, et al. Endoscopic treatment for gastric antral vascular ectasia. *Ther Adv Chronic Dis* 2021;12:20406223211039696.
71. Stanley AJ, Laine L. Management of acute upper gastrointestinal bleeding. *BMJ* 2019;364.
72. Saleem S, Thomas AL. Management of upper gastrointestinal bleeding by an internist. *Cureus* 2018;10.

73. Simbrunner B, Beer A, Wöran K, Schmitz F, Primas C, Wewalka M, et al. Portal hypertensive gastropathy is associated with iron deficiency anemia. *Wien Klin Wochenschr* 2020;132:1-11.
74. Paternostro R, Kapzan L, Mandorfer M, Schwarzer R, Benedikt S, Viveiros A, et al. Anemia and iron deficiency in compensated and decompensated cirrhosis: Prevalence and impact on clinical outcomes. *J Gastroenterol Hepatol* 2020;35:1619-27.
75. Ballester-Clau R, Torres Vicente G, Cucala Ramos M, Aracil Blanch C, Miñana Calafat JM, Pijoan Comas E, et al. Efficacy and safety of treatment with ferric carboxymaltose in patients with cirrhosis and gastrointestinal bleeding. *Front Med* 2020;7:128.
76. Hosking SW, Kennedy HJ, Seddon I, Triger DR. The role of propranolol in congestive gastropathy of portal hypertension. *Hepatology* 1987;7:437-41.
77. Bosch J, García-Pagán JC. Complications of cirrhosis. I. Portal hypertension. *J Hepatol* 2000;32:141-56.
78. De Franchis R, Dell'Era A, Iannuzzi F. Diagnosis and treatment of portal hypertension. *Dig Liver Dis* 2004;36:787-98.
79. Aday AW, Mayo MJ, Elliott A, Rockey DC. The Beneficial Effect of Beta-Blockers in Patients with Cirrhosis, Portal Hypertension and Ascites. *Am J Med Sci* 2016;351:169-76.
80. Tripathi D, Hayes PC. Beta-blockers in portal hypertension: new developments and controversies. *Liver Int* 2014;34:655-67.
81. Perez-Ayuso RM, Pique JM, Bosch J, Quintero E, Valderrama R, Bordas J, et al. Propranolol in prevention of recurrent bleeding from severe portal hypertensive gastropathy in cirrhosis. *Lancet* 1991;337:1431-4.
82. Gatta A, Bolognesi M, Merkel C, Finucci G, Angeli P, Sacerdoti D, et al. Long-term effects of beta-adrenergic blockade with nadolol on hepatic and renal haemodynamics and function in cirrhotics. *Clin Physiol* 1987;7:377-87.
83. Lo GH, Chen WC, Wang HM, Yu HC. Randomized, controlled trial of carvedilol versus nadolol plus isosorbide mononitrate for the prevention of variceal rebleeding. *J Gastroenterol Hepatol* 2012;27:1681-7.
84. Bañares R, Moitinho E, Matilla A, García-Pagán JC, Lampreave JL, Píera C, et al. Randomized comparison of long-term carvedilol and propranolol administration in the treatment of portal hypertension in cirrhosis. *Hepatology* 2002;36:1367-73.
85. Merkel C, Sacerdoti D, Bolognesi M, Buonamico P, Sticca A, Amodio P, et al. Effect of chronic treatment with nadolol plus isosorbide mononitrate on liver blood flow and liver metabolic activity in cirrhosis. *Eur J Gastroenterol Hepatol* 1999;11:1221-5.
86. Zhou Y, Qiao L, Wu J, Hu H, Xu C. Control of bleeding in portal hypertensive gastropathy. Comparison of the efficacy of octreotide, vasopressin, and omeprazole in the control of acute bleeding in patients with portal hypertensive. *J Gastroenterol Hepatol* 2002;17:973-9.
87. Chandok N, Kamath P, Blei A, Bosch J, Carey W, Grace N, et al. Randomised clinical trial: The safety and efficacy of long-acting octreotide in patients with portal hypertension. *Aliment Pharmacol Ther* 2012;35:904-12.
88. Bari K, Garcia-Tsao G. Treatment of portal hypertension. *World J Gastroenterol* 2012;18:1166.
89. Liver EAfTSot. EASL Clinical Practice Guidelines for the management of patients with decompensated cirrhosis. *J Hepatol* 2018;69:406-60.
90. Gunarathe LS, Rajapaksha H, Shackel N, Angus PW, Herath CB. Cirrhotic portal hypertension: From pathophysiology to novel therapeutics. *World J Gastroenterol* 2020;26:6111.
91. Bolognesi M, Balducci G, Garcia-Tsao G, Gatta A, Gines P, Merli M, et al, eds. Session 8—complications in the medical treatment of portal hypertension. portal hypertension III: Proceedings of the Third Bavero International Consensus Workshop on Definitions, Methodology and Therapeutic Strategies. New York: Wiley Online Library; 2001.
92. Mohanty A. Peptide-based therapy in portal hypertension. *Curr Opin Endocrinol Diabetes Obes* 2020;27:22-7.
93. Bunchorntavakul C, Reddy KR. Pharmacologic management of portal hypertension. *Clin Liver Dis* 2019;23:713-36.
94. Reiberger T, Püspök A, Schoder M, Baumann-Durchschein F, Bucsics T, Datz C, et al. Austrian consensus guidelines on the management and treatment of portal hypertension (Billroth III). *Wien Klin Wochenschr* 2017;129:135-58.
95. Habib S, ed. Portal Hypertensive Gastropathy. In: Guo X, Qi X, editors. Variceal bleeding in liver cirrhosis. Singapore: Springer; 2021. p.123-40.
96. Snyder P, Ali R, Poles M, Gross SA. Portal hypertensive gastropathy with a focus on management. *Expert Rev Gastroenterol Hepatol* 2015;9:1207-16.
97. Turon F, Casu S, Hernández-Gea V, García-Pagán JC. Variceal and other portal hypertension related bleeding. *Best Prac Res Clin Gastroenterol* 2013;27:649-64.
98. Garcia-Saenz-de-Sicilia M, Sanchez-Avila F, Chavez-Tapia N-C, Lopez-Arce G, Garcia-Osogobio S, Ruiz-Cordero R, et al. PPIs are not associated with a lower incidence of portal-hypertension-related bleeding in cirrhosis. *World J Gastroenterol* 2010;16:5869-73.
99. Kamath PS, Lacerda M, Ahlquist DA, McKusick MA, Andrews JC, Nagorney DA. Gastric mucosal responses to intrahepatic portosystemic shunting in patients with cirrhosis. *Gastroenterology* 2000;118:905-11.
100. Allaire M, Walter A, Sutter O, Nahon P, Ganne-Carrié N, Amathieu R, et al. TIPS for management of portal-hypertension-related complications in patients with cirrhosis. *Clin Res Hepatol Gastroenterol* 2020;44:249-63.

101. Lo G-H. Endoscopic treatments for portal hypertension. *Hepatol Int* 2018;12:91-101.
102. El Shahawy MS, Shady ZM, Gaafar A. The efficacy of argon plasma coagulation versus carvedilol for treatment of portal hypertensive gastropathy. *Digestion* 2020;101:651-8.
103. Smith L, Morris A, Stanley A. The use of hemospray in portal hypertensive bleeding; A case series. *J Hepatol* 2014;60:457-60.
104. Han S, Chaudhary N, Wassef W. Portal hypertensive gastropathy and gastric antral vascular ectasia. *Curr Opin Gastroenterol* 2015;31:506-12.
105. Dulai GS, Jensen DM. Treatment of watermelon stomach. *Curr Treat Options Gastroenterol* 2006;9:175-80.
106. Boltin D, Gingold-Belfer R, Lichtenstein L, Levi Z, Niv Y. Long-term treatment outcome of patients with gastric vascular ectasia treated with argon plasma coagulation. *Eur J Gastroenterol Hepatol* 2014;26:588-93.
107. Chaves DM, Sakai P, Oliveira CV, Cheng S, Ishioka S. Watermelon stomach: Clinical aspects and treatment with argon plasma coagulation. *Arq Gastroenterol* 2006;43:191-5.
108. Rosenfeld G, Enns R. Argon photocoagulation in the treatment of gastric antral vascular ectasia and radiation proctitis. *Can J Gastroenterol* 2009;23:801-4.
109. Pavey DA, Craig PI. Endoscopic therapy for upper-GI vascular ectasias. *Gastrointest Endosc* 2004;59:233-8.
110. Becq A, Camus M, Rahmi G, de Parades V, Marteau P, Dray X. Emerging indications of endoscopic radiofrequency ablation. *United European Gastroenterol J* 2015;3:313-24.
111. Matsui S, Kamisako T, Kudo M, Inoue R. Endoscopic band ligation for control of nonvariceal upper GI hemorrhage: comparison with bipolar electrocoagulation. *Gastrointest Endosc* 2002;55:214-8.
112. Junquera F, Brullet E, Campo R, Calvet X, Puig-Diví V, Vergara M. Usefulness of endoscopic band ligation for bleeding small bowel vascular lesions. *Gastrointest Endosc* 2003;58:274-9.
113. Tantau M, Crisan D. Is endoscopic band ligation the gold standard for gastric antral vascular ectasia? *Endosc Int Open* 2019;7:1630-1.
114. Eccles J, Falk V, Montano-Loza AJ, Zepeda-Gómez S. Long-term follow-up in patients with gastric antral vascular ectasia (GAVE) after treatment with endoscopic band ligation (EBL). *Endosc Int Open* 2019;7:1624-9.
115. O'Morain NR, O'Donovan H, Conlon C, Shannon E, Manning D, Slattery E. Is endoscopic band ligation a superior treatment modality for gastric antral vascular ectasia compared to argon plasma coagulation? *Clin Endosc* 2021;54:548.
116. Peng M, Guo X, Yi F, Romeiro FG, Mancuso A, Qi X. Pharmacotherapy for the treatment of gastric antral vascular ectasia: A Narrative review. *Adv Ther* 2021;38(10):5065-77.
117. Soykan I, Toruner M, Idilman R, Ozden A. Reversal of iron deficiency anemia in a patient with gastric antral vascular ectasia treated with cyproheptadine. *J Clin Gastroenterol* 2003;36:183-4.
118. Lorenzi AR, Johnson AH, Davies G, Gough A. Gastric antral vascular ectasia in systemic sclerosis: complete resolution with methylprednisolone and cyclophosphamide. *Ann Rheum Dis* 2001;60:796.
119. Matsumoto Y, Hayashi H, Tahara K, Yasuda T, Tsubouchi S, Yamamoto Y, et al. Intravenous Cyclophosphamide for Gastric Antral Vascular Ectasia Associated with Systemic Sclerosis Refractory to Endoscopic Treatment: A Case Report and Review of the Pertinent Literature. *Intern Med* 2019;58:135-139.
120. Papachristos DA, Nikpour M, Hair C, Stevens WM. Intravenous cyclophosphamide as a therapeutic option for severe refractory gastric antral vascular ectasia in systemic sclerosis. *Intern Med J* 2015;45:1077-81.
121. Peterson A, Varga J. Cyclophosphamide: A novel treatment of gastric antral vascular ectasia associated with systemic sclerosis? *Curr Rheumatol Rep* 2010;12:4-7.
122. Tran A, Villeneuve J-P, Bilodeau M, Willems B, Marleau D, Fenyves D, et al. Treatment of chronic bleeding from gastric antral vascular ectasia (GAVE) with estrogen-progesterone in cirrhotic patients: An open pilot study. *Am J Gastroenterol* 1999;94:2909-11.
123. Manning RJ. Estrogen/progesterone treatment of diffuse antral vascular ectasia. *Am J Gastroenterol* 1995;90:154-56.
124. Dunne KA, Hill J, Dillon JF. Treatment of chronic transfusion-dependent gastric antral vascular ectasia (watermelon stomach) with thalidomide. *Eur J Gastroenterol Hepatol* 2006;18:455-6.
125. Aveiro M, Rodrigues T, Rabadão T, Ferreira F, Teixeira M, Oliveira A, et al. The use of thalidomide in severe refractory anaemia due to gastric antral vascular ectasia (GAVE) in Cirrhosis? *Eur J Case Rep Intern Med* 2020;7:002099.
126. Los M, Roodhart JML, Voest EE. Target practice: Lessons from phase III trials with Bevacizumab and Vatalanib in the treatment of advanced colorectal cancer. *Oncologist* 2007;12:443-50.
127. Albitar HAH, Almodallal Y, Papadakis KA, Rajan E, Kamath PS, Iyer VN. Intravenous Bevacizumab reduces transfusion requirements and endoscopic interventions in patients with gastric antral vascular ectasia and small bowel angioectasia. *Gastroenterology* 2020;158:1162-3.
128. McCormick PA, Ooi H, Crosbie O. Tranexamic acid for severe bleeding gastric antral vascular ectasia in cirrhosis. *Gut* 1998;42:750.
129. Khan S, Vaishnavi A. Pharmacotherapy for gastric antral vascular ectasia: dramatic response to tranexamic acid. *Gastrointest Endosc* 2009;70:191.
130. Novitsky YW, Kercher KW, Czerniach DR, Litwin DE. Watermelon stomach: Pathophysiology, diagnosis, and management. *J Gastrointest Surg* 2003;7:652-61.

218 Comparison of portal hypertensive gastropathy and gastric antral vascular ectasia: an update

131. Cales P, Voigt J, Payen J, Bloom E, Berg P, Vinel J, et al. Diffuse vascular ectasia of the antrum, duodenum, and jejunum in a patient with nodular regenerative hyperplasia. Lack of response to portosystemic shunt or gastrectomy. *Gut* 1993;34:558-61.

132. Sherman V, Klassen DR, Feldman LS, Jabbari M, Marcus V, Fried GM. Laparoscopic antrectomy: a novel

approach to treating watermelon stomach. *J Am Coll Surg* 2003;197:864-7.

133. Singhal S, Uthappa MC. Intra-arterial embolization as a treatment option in a case of gastric antral vascular ectasia. *J Clin Interv Radiol ISVIR* 2020;4:51-4.