

# Adjunctive Treatment of Periodontal Defects Using Fibroblast Growth Factor 2: A Review of Case Reports with Long-term Follow-up

Fazele Atarbashi-Moghadam<sup>1a</sup>, Zahra Baghani<sup>2b</sup>, Ali Ghased<sup>3c\*</sup>

<sup>a</sup>Department of Periodontics, School of Dentistry, Shahid Beheshti University of Medical Sciences, Tehran, Iran.

<sup>b</sup>Department of Periodontics, School of Dentistry, Sabzevar University of Medical Sciences, Sabzevar, Iran.

<sup>c</sup>Dental Research Center, Research Institute of Dental Sciences, Shahid Beheshti University of Medical Sciences, Tehran, Iran.

\*Correspondence to Author, Ali Ghased, Email: [alighased78@gmail.com](mailto:alighased78@gmail.com)

Submitted: 27 January 2025  
Revised: 13 April 2025  
Accepted: 14 April 2025  
Published: Summer 2025

## How to cite:

Atarbashi-Moghadam F, Baghani Z, Ghased A. Adjunctive Treatment of Periodontal Defects Using Fibroblast Growth Factor 2: A Review of Case Reports with Long-term Follow-up. *J Dent Sci* 2025;43(3):164-172.

## Abstract:

**Objective(s):** Application of fibroblast growth factor 2 (FGF2) as an adjunctive treatment in periodontal regeneration is a treatment modality. Several recent case reports describe the application of FGF-2 in different periodontal defects with detailed information and long-term follow-ups. The aim of this review was to assess the effect of FGF-2 on periodontal regeneration and patient quality of life in cases with long-term follow-up.

**Methods:** An electronic search was performed in PubMed Central, Scopus, and web of science databases from 1990 until December 2023. The search included all case reports in which FGF2 was used for periodontal defect treatment with long-term follow-up. Case series which described detailed data of their cases were also evaluated. Ten articles including 12 patients, 23 teeth, and 25 defects were included in the study.

**Results:** Most of the treated defects were infrabony defects (84%), followed by furcation defects (12%). Probing depth (PD) reduction and clinical attachment loss (CAL) gain were seen in all defects and evidence of bone fill was documented. All cases had a follow-up duration of at least 12 months, with the greatest follow-up time of 9 years. **Conclusion:** Adjunctive treatment of periodontal defects using FGF-2 is an effective and stable treatment modality that provides patients' satisfaction. However, more studies in this field are recommended.

**Keywords:** Fibroblast Growth Factor 2; Periodontal Regeneration; Periodontal Bone Defect

## Introduction

Periodontal regeneration aims to increase the periodontal attachment and bone level of severely compromised teeth, decrease pocket depth, and minimize the gingival recession. Patient-, defect-, and surgery-associated factors can affect the outcome of periodontal treatments.<sup>1</sup> Using growth factors in the periodontal regeneration modalities results in cellular responses that stimulate cellular proliferation and differentiation.<sup>2</sup> Fibroblast growth factor (FGF)-2, also known as basic fibroblast growth factor (bFGF), is a signaling molecule that plays a role in wound healing.<sup>3</sup> It has been shown that FGF-2 enhances the proliferation rate and angiogenesis of periodontal ligament stem cells *in vitro*.<sup>4-6</sup> Moreover, *in vivo* and clinical studies revealed that this growth factor could play a significant role in regenerating periodontal defects.<sup>7-9</sup> Its efficacy and safety have been approved<sup>9</sup> and since 2016, a formulation of 0.3% recombinant human FGF-2 (rhFGF-2) has been commercially available.<sup>10</sup>

Several recent case reports describe the application of FGF-2 in different periodontal defects alone or in combination with other materials, with detailed information and long-term follow-ups.<sup>11-13</sup> The aim of this review was to assess the effect of FGF-2 on periodontal

regeneration and patient quality of life in cases with long-term follow-up.

## Methods

The present review was performed after being approved by the ethic committee of Shahid Beheshti University of Medical Sciences (IR.SBMU.DRC.REC.1402.066). The search was performed using "MeSH" terms and keywords based on the elements of the PICO question:

1. Participants (P): Periodontal defects
2. Intervention (I): treatment using FGF-2
3. Comparison or control (C): Not applicable
4. Outcome measures (O): Changes in probing depth (PD) and clinical attachment loss (CAL), bone fill, mobility, as well as Quality of life

An electronic search in PubMed Central, Scopus, and Web of Science's electronic databases from 1990 until December 2023 was conducted. The following query "(fibroblast growth factor 2 OR basic fibroblast growth factor OR FGF2 OR bFGF OR rhFGF2) AND (periodontal regeneration OR periodontal defect OR furcation involvement OR furcation defect)" were used in the search strategy. The included studies were limited to English-language. All case reports in which FGF2 was used in

periodontal defect treatment with long term follow-up (at least 12 months) were included. Case series which described their cases completely were also included. Articles in which the effect of FGF2 was confounded or cases without follow-up were excluded from the study. Publications including only abstracts, reviews, letters, and book chapters were also excluded. The full title and abstract of each article were screened by two independent authors (FAM. and AGh) using predetermined inclusion and exclusion criteria. The bibliographies of the selected studies and Google Scholar were also reviewed. Any disagreement in the study selection process was resolved by discussion with a third reviewer (ZB). Finally, the researchers reviewed the full- texts of articles that were agreed upon and selected by all the authors. The data items including Patients' age, sex, type of periodontal defects, and periodontal parameters at baseline and after treatment using FGF-2, treatment modality, follow-up time, and quality of life at baseline and after treatment were summarized. To assess the risk of bias in the included studies, CARE guidelines for case reports<sup>14</sup> were used. For statistical analysis, descriptive data were expressed as percentages using SPSS software (version 15.0, SPSS Inc., Chicago, USA).

## Results

In total, ten case report articles including 12 patients, 23 teeth, and 25 defects were included in this study. The study selection flowchart is shown in Figure 1. Among the patients, eight of them (66.66%) were female, and four (33.33%) were male. The mean age of patients was  $53.33 \pm 10.06$ . All cases were periodontitis patients<sup>10-13, 15-19</sup>, except one case of cemental tear in a non-periodontitis patient.<sup>20</sup> The data of included case reports is summarized in Table 1.

The periodontal lesions included infrabony defects (84%),<sup>10-13, 15-19</sup> (Two lesions had suprabony components too)<sup>11</sup>, class II furcation defect (8%)<sup>10, 19</sup>, class III furcation defect (4%)<sup>10</sup>, and cemental tear (4%).<sup>19</sup> Thirteen defects (52%) were treated with FGF-2 alone; in four defects FGF-2 was applied after etching the root surface with EDTA (8%)<sup>10</sup> or phosphoric acid (8%)<sup>19</sup>, five defects (20%) were treated with the combination of FGF-2 and Deproteinized bovine bone mineral (DBBM)<sup>16,18</sup>; and two defects (8%) were treated with the combination of carbonate apatite with FGF-2 and placement of collagen membrane and CTG.<sup>11</sup> All cases had a follow-up duration of at least 12 months, with the greatest follow-up time of 9 years.<sup>19</sup>

PD reduction and CAL gain were seen in all defects, ranging between 2 to 8mm for both indices. All studies had radiographic assessment; however, only in five defects<sup>12, 18, 19</sup> the percentage of bone fill was reported (ranging between 40% to 120.4%). One study (two defects)<sup>11</sup> reported the bone changes in millimeters. Three teeth showed 2-degree mobility which resolved after treatment. Quality of life was reported in eight patients<sup>11, 13, 16,18</sup> and all of them improved, except for one case who did not show any improvement in her quality of life<sup>17</sup>, even though the patient's chief complaint was resolved.

Regarding the risk of bias assessment, it should be mentioned that the case report studies are low quality researches. However, all studies were assessed using CARE guidelines for case reports<sup>14</sup> and all studies followed all sections of this guideline (Table 2).

## Discussion

Although the efficacy of FGF-2 in periodontal regeneration has been shown in randomized clinical trials<sup>8,9</sup>, new case reports are still being conducted in this field because available data on the clinical application of this growth factor in periodontal treatment is still limited.<sup>17</sup>

In the present review, one of the most important aspects of the included case reports was changes in combination treatments with other substitute materials, flap designs, and long-term follow-ups. In all cases, reduction in PD and CAL gain were observed. Radiographic evidence of bone fill was also observed in all cases.

According to this review, most of the lesions treated with FGF-2 contained infrabony defects (2 to 3-walled); therefore, according to the decision tree in Cortelini et al's<sup>1</sup> study, the authors decided to use this signaling molecule alone. DBBM and carbonate apatite were used as a bone substitute which was used in combination with FGF-2 in the included studies.<sup>11, 16, 18</sup> In one study, the authors selected this combination treatment for non-contained defects<sup>16</sup>, because periodontal regeneration may not be possible in these defects without space maintenance.<sup>1</sup> Therefore, using bone graft material was recommended for space preservation to retain blood clots and promote the regenerative process.<sup>1</sup>

Root conditioning methods such as EDTA were not usually recommended in combination with FGF-2.<sup>1, 10</sup> However; Takayama et al.,<sup>10</sup> claimed to use root conditioning because of the extensive and complex furcation defects of their case. They observed that root conditioning with EDTA before application of FGF-2 had improved the differentiation of surrounding tissues mesenchymal stem

cells into cementoblasts by promoting demineralization of the root surface and exposing the collagen matrix.<sup>10</sup> In-vitro studies have shown that root conditioning with EDTA can improve PDL cell adhesion<sup>21</sup> and cementoblast differentiation of PDLSCs.<sup>22</sup> As EDTA application before FGF-2 does not affect the hemostasis, a study about its application in combination with FGF2 in periodontal defects is recommended.

Growth factors are used in periodontal treatment for enhancing periodontal regeneration; therefore, they should be used in combination with flap techniques suitable for periodontal regeneration such as papilla preservation techniques (PPTs).<sup>1, 23</sup> PPTs, from the traditional type to their modifications, aim to preserve as much as possible of soft tissue, minimize the trauma to the interdental papilla, promote early soft tissue healing, and reduce postoperative gingival recession.<sup>23</sup> The included studies that specified the flap technique in their studies, used SPPF<sup>10</sup>, MPPF<sup>15</sup>, and Modified NIPSA<sup>11</sup> in their surgeries. Ogawa et al.,<sup>11</sup> used modified NIPSA with a horizontal incision in the buccal vestibule and coronally advanced the flap after the releasing of the entire papilla from the buccal and palatal site. Thereafter, they used a connective tissue graft (CTG) under the buccal flap, as coronally as possible. The combination of coronally advanced flap and CTG was sustained using an interrupted interproximal sling suture to preserve space for tissue regeneration. Then, they applied the FGF-2 on both supra- and infra-bony components of the lesion and the space was filled with the mixture of carbonate apatite with FGF-2 and a collagen membrane placed on the graft surface. The authors claimed that this technique provides adequate space for periodontal regeneration.<sup>11</sup>

One of the important data provided with these case reports is the long-term follow-up of the cases. Ninomiya et al.,<sup>19</sup> followed their case for nine years and reported that the clinical outcomes were stable after this time. They also compared the treatment of similar lesions on another tooth of their case which was treated with enamel matrix derivatives (EMD), and concluded that the treatment with FGF-2 was more stable than EMD after 9 years. Yoshinuma et al.<sup>12</sup> explained that periodontal regeneration using FGF-2 was effective in the case of an aggressive periodontitis patient and stable even after six years.

Most of the periodontal parameters documented as successful treatment are intangible outcomes (like PD reduction or CAL gain), and may give little insight into the patient's perception of treatment<sup>18, 24</sup>; therefore, some researchers preferred to assess the quality of life using

questionnaires such as Oral Health-Related Quality of Life (OHRQL) or Patient-reported outcome measures (PROMS). All cases showed improvement in their quality of life<sup>11, 13, 15, 16, 19</sup>, except for one case who did not show any improvement in her quality of life<sup>17</sup>, even though the patient's chief complaint was resolved. Ogawa et al.,<sup>11</sup> also documented the patient's esthetic and function improvement through PROMS and showed improvement in these parameters after treatment. Consequently, reporting tangible endpoints after periodontal treatment can better reveal the patients' satisfaction with treatment. This study was limited to a review of the case reports that used FGF-2 in periodontal regeneration with long term follow-up and all studies differed in means of defect type, flap design, graft material, and application techniques. Therefore, it was not possible to pool or compare the data. However, future studies with a focus on flap techniques, root conditioning, and graft material in combination with FGF-2 are suggested.

## Conclusion

In conclusion, FGF-2 was an effective and stable adjunctive therapy for periodontal regeneration, and patients' satisfaction was documented. However, more studies in this field considering new insights in periodontal treatment are recommended.

**Acknowledgement:** None acknowledgement.

**Author Contributions:** FAM: Conceptualization, Supervision, Methodology, Writing –original draft, Writing –review & editing. ZB: Conceptualization, Methodology, Writing –review & editing. AGH: Methodology, Investigation, Data collection, Writing –original draft, Writing –review & editing.

**Funding:** None.

**Ethical Approval Code:** The study was approved by the ethic committee of Shahid Beheshti University of Medical Sciences (IR.SBMU.DRC.REC.1402.066).

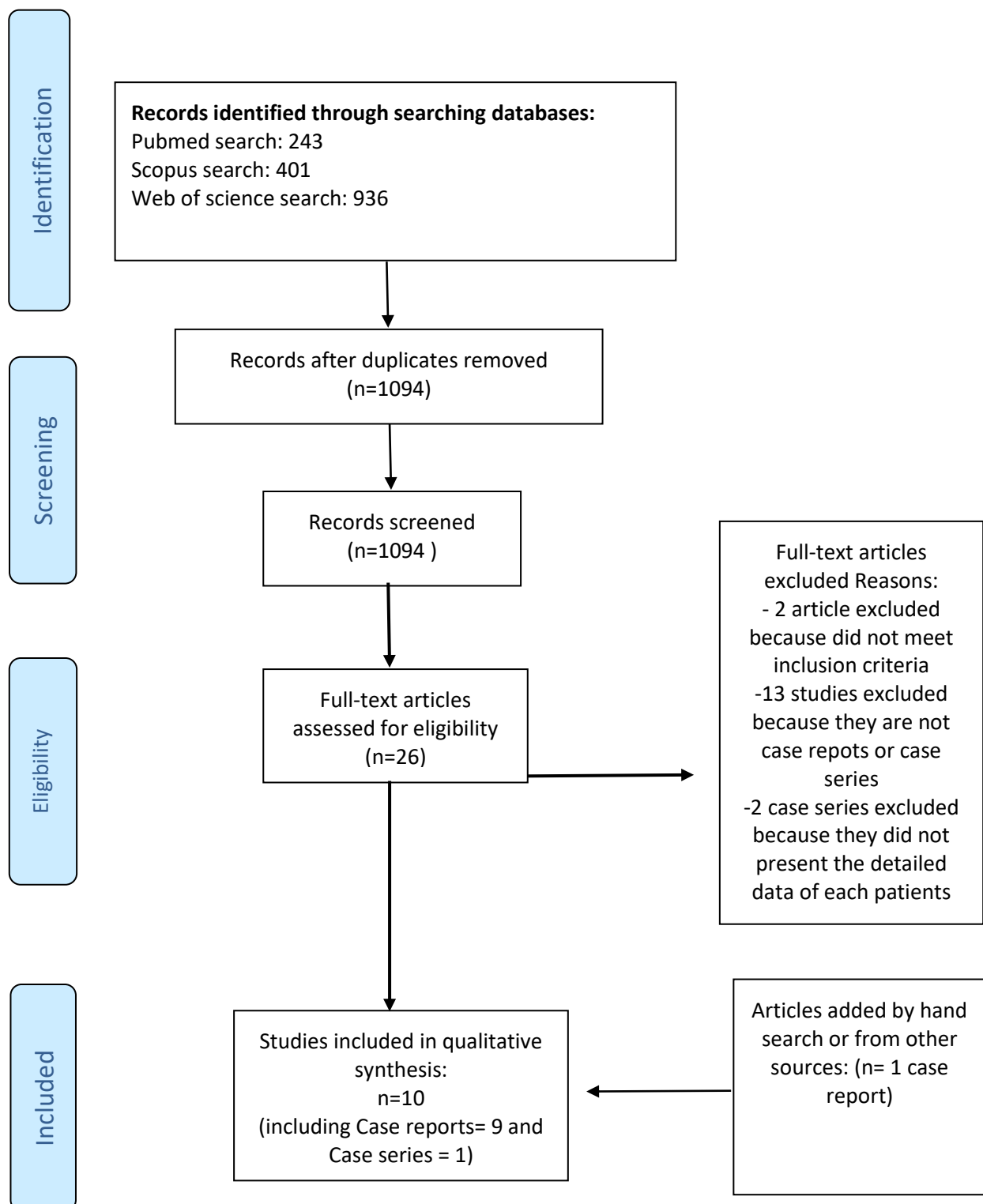
**Informed Consent Statement:** Not applicable.

**Data Availability Statement:** Data is available within the article or its supplementary materials.

**Using AI:** This manuscript was written entirely by the authors without the assistance of any AI tools or large

language models.

**Conflict of Interest:** None.



**Figure 1:** Flowchart diagram of study selection

Table 1 - Data summary of included studies

Reference	Subject			Treatment	Follow up (mo/Y)	Outcome			
	Gender (F/M)	Mean Age (years)	Site characteristics			PD reduction	Mean CAL gain (mm)	Radiographic bone fill	Other
Ogawa et al., 2023	F	53	Maxillary central incisor (intrabony & supra bony defect)	RCT of central incisor (Endo-perio lesion) + splinting	12 & 24 Mo	2	5	4.2mm	The interdental papilla height was improved 5 mm distal of lateral and 6 mm between lateral & central region  OHIP-14 QL = from 30 to 44  PROMs (masticatory function)= from 0 to 2 PROMs (esthetic )= from 0 to 3
			Maxillary lateral incisor (intrabony & supra bony defect)	Modified NIPSA + CTG + application of rhFGF2 in defect + mixture of carbonate apatite & rhFGF2 + collagen membrane		4	8	2.9 mm	
Iwaki et al., 2022	F	54	Maxillary right 1 <sup>st</sup> premolar (intrabony defect)	0.3% rhFGF2	6, 9, 12, & 24 Mo	4	4	NA	OHRQL= from 37 to 25 after 1 year
			Maxillary right 2 <sup>nd</sup> premolar (intrabony defect)			4	4		
			Maxillary left 2 <sup>nd</sup> premolar (intrabony defect)			3	3		
			Maxillary left 2 <sup>nd</sup> molar (intrabony defect)			2	2		
Nakane-Koyachi et al., 2022	M	59	Maxillary left first molar (intrabony defect)	MPPF + 0.3% rhFGF2	3,6,9,12,18, & 24 Mo	3	3	NA	OHRQL = from 17 to 4
Nagahara et al., 2022	F	75	Mandibular right central incisor	Cemental tear removal + rhFGF2	24 Mo	7	7	NA	
Bizenjima et al., 2021	M	62	Maxillary 1 <sup>st</sup> premolar	0.3% rhFGF2	18 Mo	2	2	NA	OHRQL = from 19 to 6
			Maxillary 2 <sup>nd</sup> premolar			3	3		
			Maxillary 1 <sup>st</sup> molar			3	2.5		
			Mandibular 2 <sup>nd</sup> molar,			5	3		
			Mandibular lateral incisor			5	5		
			Mandubular 2 <sup>nd</sup> premolar			4	4		
			Mandubular 2 <sup>nd</sup> molar			3	3		

Table 1 - Data summary of included studies

Reference	Subject			Treatment	Follow up (mo/Y)	Outcome			
	Gender (F/M)	Mean Age (years)	Site characteristics			PD reduction	Mean CAL gain (mm)	Radiographic bone fill	Other
Takayama et al., 2021	F	42	Mandibular 1 <sup>st</sup> molar (distal 1- to 2-wall defect, and FI CL III)  Mandibular 2 <sup>nd</sup> molar (FI CL II)	SPPT + root surfaces treatment with 24% EDTA (2 minutes) + FGF2	4, 5, 6, 7, 9, 12, and 15 Mo	D: 6 FI: 8  FI: 6	D: 6 FI: 7  FI: 5	CBCT: considerable new bone formation in the intrabony defect & FI CL II, but not in FI CL III	grade II mobility of both teeth was resolved
Matsugami et al., 2021	F	53	Mandibular left canine (distal – intrabony defect)	0.3% rhFGF2	3,6,9,12,18, & 24 Mo	5	5	NA	OHRQL = from 22 to 25 ( no improvement)
Yoshida et al., 2020	F	48	3-wall defect (5×4mm) (mesial of maxillary 1 <sup>st</sup> molar)	0.3% rhFGF2 + DBBM	3, 6, 12 Mo	3	3	40%	OHRQL = from 23 to 13
	M	52	2-3-wall defect (6×4mm) (distal of mandibular 2 <sup>nd</sup> molar)	0.3% rhFGF2 + DBBM	3, 6, 12 Mo	5	4.5	44.4%	OHRQL = from 26 to 9
	F	58	2-3-wall defect (4 ×3) (distal of maxillary canine)	0.3% rhFGF2 + DBBM	3, 6, 12 Mo	3	2	60%	OHRQL = from 33 to 20
Yoshinuma et al., 2016	M	32	Mandibular left 2 <sup>nd</sup> premolar (2- & 3-wall defect)	Smoking cease 0.3% rhFGF2	3,6,9,12 Mo / every year until 6 Y	3	5	86.9%	Smoker  Aggressive periodontitis
Ninomiya et al., 2013	F	52	Maxillary right 1 <sup>st</sup> molar ( 2-wall intrabony defect & FI CL II)	etching with 35% phosphoric acid + 200 µL FGF2	3, 9 Mo / 9 Y	2-wall defect=4 FI= 3	4  3	120.4%	Mobility grade 2 was resolved

&=And, CBCT= cone beam computed tomography, CL= Class, CTG= Connective tissue graft, D=distal, DBBM= Deproteinized bovine bone mineral, F= female, FI= Furcation involvement, M= Male, mm=millimeters, MPPT= Modified papilla preservation technique, Mo=months, NA= not available, NIPSA= Non-incisal papilla surgical approach, OHIP-14 = Oral Health Impact Profile-14 (Japanese version); OHRQL= Oral health-related quality of life, PROMs = patient-reported outcome measures, SPPT= Simplified papilla preservation technique,

Table 2- Assessment of risk of bias in included studies based on CARE case report guidelines

Reference	Title	Keywords	Abstract	Introduction	Patient information	Clinical findings	Timeline	Diagnostic assessment	Therapeutic interventions	Follow-up and outcomes	Discussion	Patient perspective	Informed consent
Ogawa et al., 2023	✓	✓	✓	✓	✓	✓	✓	✓	✓	✓	✓	✓	✓
Iwaki et al., 2022	✓	✓	✓	✓	✓	✓	✓	✓	✓	✓	✓	✓	✓
Nakane-Koyachi et al., 2022	✓	✓	✓	✓	✓	✓	✓	✓	✓	✓	✓	✓	✓
Nagahara et al., 2022	✓	✓	✓	✓	✓	✓	✓	✓	✓	✓	✓	✓	✓
Bizenjima et al., 2021	✓	✓	✓	✓	✓	✓	✓	✓	✓	✓	✓	✓	✓
Takayama et al., 2021	✓	✓	✓	✓	✓	✓	✓	✓	✓	✓	✓	✓	✓
Matsugami et al., 2021	✓	✓	✓	✓	✓	✓	✓	✓	✓	✓	✓	✓	✓
Yoshida et al., 2020	✓	✓	✓	✓	✓	✓	✓	✓	✓	✓	✓	✓	✓
Yoshinuma et al., 2016	✓	✓	✓	✓	✓	✓	✓	✓	✓	✓	✓	✓	✓
Ninomiya et al., 2013	✓	✓	✓	✓	✓	✓	✓	✓	✓	✓	✓	✓	✓

---

## References

1. Cortellini P, Tonetti MS. Clinical concepts for regenerative therapy in intrabony defects. *Periodontol* 2000;2015;68:282–307. doi: [10.1111/prd.12048](https://doi.org/10.1111/prd.12048)
2. Smith PC, Martínez C, Cáceres M, Martínez J. Research on growth factors in periodontology. *Periodontology* 2000;2015;67:234–50. doi: [10.1111/prd.12068](https://doi.org/10.1111/prd.12068)
3. Fujihara C, Kanai Y, Masumoto R, Kitagaki J, Matsumoto M, Yamada S, et al. Fibroblast growth factor-2 inhibits CD40-mediated periodontal inflammation. *J Cell Physiol* 2019;234:7149–60. doi: [10.1002/jcp.27469](https://doi.org/10.1002/jcp.27469)
4. Atarbashi-Moghadam F, Azadi A, Nokhbatolfoghahaei H, Taghipour N. Effect of simultaneous and sequential use of TGF- $\beta$ 1 and TGF- $\beta$ 3 with FGF-2 on teno/ligamentogenic differentiation of periodontal ligament stem cells. *Arch Oral Biol*. 2024;162:105956. doi: [10.1016/j.archoralbio.2024.105956](https://doi.org/10.1016/j.archoralbio.2024.105956).
5. Kono K, Maeda H, Fujii S, Tomokiyo A, Yamamoto N, Wada N, et al. Exposure to transforming growth factor- $\beta$ 1 after basic fibroblast growth factor promotes the fibroblastic differentiation of human periodontal ligament stem/progenitor cell lines. *Cell Tissue Res* 2013;352:249–63. doi: [10.1007/s00441-012-1543-0](https://doi.org/10.1007/s00441-012-1543-0)
6. Atarbashi-Moghadam F, Mahmoudian A, Taghipour N, Hakimiha N, Azadi A, Nokhbatolfoghahaei H. Enhancement of the angiogenic differentiation in the periodontal ligament stem cells using fibroblast growth factor 2 and photobiomodulation: An in vitro investigation. *Photochem Photobiol*. 2025;101(3):660-72. doi: [10.1111/php.14032](https://doi.org/10.1111/php.14032)
7. Nagayasu-Tanaka T, Anzai J, Takedachi M, Kitamura M, Harada T, Murakami S. Effects of combined application of fibroblast growth factor (FGF)-2 and carbonate apatite for tissue regeneration in a beagle dog model of one-wall periodontal defect. *Regen Ther*. 2023;23:84-93. doi: [10.1016/j.reth.2023.04.002](https://doi.org/10.1016/j.reth.2023.04.002)
8. Kitamura M, Nakashima K, Kowashi Y, Fujii T, Shimauchi H, Sasano T, et al. Periodontal tissue regeneration using fibroblast growth factor-2: randomized controlled phase II clinical trial. *PLoS One*. 2008;3(7):e2611. doi: [10.1371/journal.pone.0002611](https://doi.org/10.1371/journal.pone.0002611)
9. Kitamura M, Akamatsu M, Machigashira M, Hara Y, Sakagami R, Hirofujii T, et al. FGF-2 stimulates periodontal regeneration: Results of a multi-center randomized clinical trial. *J Dent Res*. 2011;90:35-40. doi: [10.1177/0022034510384616](https://doi.org/10.1177/0022034510384616)
10. Takayama SI, Murakami S. Efficacy of FGF-2 in Periodontal Regeneration in a Case of Severe Intrabony Defect and Furcation Involvement With 15-Month Follow-Up. *Clin Adv Periodontics*. 2021;11(2):74-79. doi: [10.1002/cap.10127](https://doi.org/10.1002/cap.10127)
11. Ogawa Y, Maekawa S, Imamura K, Ishikawa T. Supra-Alveolar Periodontal Tissue Reconstruction in a Case with Severe Periodontitis: Case Report with a 2-Year Follow-up. *Int J Periodontics Restorative Dent*. 2023;43(2):212-21. doi: [10.11607/prd.6241](https://doi.org/10.11607/prd.6241)
12. Yoshinuma N, Koshi R, Kawamoto K, Idesawa M, Sugano N, Sato S. Periodontal regeneration with 0.3% basic fibroblast growth factor (FGF-2) for a patient with aggressive periodontitis: a case report. *J Oral Sci*. 2016;58(1):137-40. doi: [10.2334/josnusd.58.137](https://doi.org/10.2334/josnusd.58.137).
13. Iwaki J, Imamura K, Tanaka K, Sugito H, Saito A. Treatment of Stage III Grade C Periodontitis with Periodontal Regenerative Therapy including Guided Tissue Regeneration (GTR) and Recombinant Human Fibroblast Growth Factor (rhFGF)-2: A Case Report. *Bull Tokyo Dent Coll*. 2023;63(4):189-98. doi: [10.2209/tdcpublication.2022-0017](https://doi.org/10.2209/tdcpublication.2022-0017)
14. Riley DS, Barber MS, Kienle GS, Aronson JK, von Schoen-Angerer T, et al. CARE guidelines for case reports: explanation and elaboration document. *J Clin Epidemiol*. 2017;89:218-35. doi: [10.1016/j.jclinepi.2017.04.026](https://doi.org/10.1016/j.jclinepi.2017.04.026).
15. Nakane-Koyachi S, Imamura K, Saito A. Treatment of Chronic Periodontitis with Periodontal Surgery Including Regenerative Therapy Using Recombinant Human Fibroblast Growth Factor-2 and Papilla Preservation Technique: A Case Report with a Two-year Follow-up. *Bull Tokyo Dent Coll*. 2022;63(2):95-103. doi: [10.2209/tdcpublication.2021-0048](https://doi.org/10.2209/tdcpublication.2021-0048).
16. Bizenjima T, Irokawa D, Tanaka K, Saito A, Tomita S. Periodontal Regenerative Therapy with Recombinant

- Human Fibroblast Growth Factor-2 and Deproteinized Bovine Bone Mineral in Patient with Chronic Periodontitis: An 18-month Follow-up Report. *Bull Tokyo Dent Coll.* 2021;62(2):107-17. doi: [10.2209/tdcpublication.2020-0034](https://doi.org/10.2209/tdcpublication.2020-0034)
17. Matsugami D, Aoki H, Saito A. Surgical Periodontal Therapy with Recombinant Human Fibroblast Growth Factor-2 in Treatment of Chronic Periodontitis: A Case Report with 2-year Follow-up. *Bull Tokyo Dent Coll.* 2021;62(2):127-34. doi: [10.2209/tdcpublication.2020-0045](https://doi.org/10.2209/tdcpublication.2020-0045).
18. Yoshida W, Takeuchi T, Imamura K, Seshima F, Saito A, Tomita S. Treatment of Chronic Periodontitis with Recombinant Human Fibroblast Growth Factor-2 and Deproteinized Bovine Bone Mineral in Wide Intrabony Defects:12-month Follow-up Case Series. *Bull Tokyo Dent Coll.* 2020;61(4):231-241. doi: [10.2209/tdcpublication.2019-0050](https://doi.org/10.2209/tdcpublication.2019-0050)
19. Ninomiya M, Azuma T, Kido J, Murakami Sh, Nagata T. Successful case of periodontal tissue repair with fibroblast growth factor-2: long-term follow-up and comparison to enamel matrix derivative. *Clin Adv Periodontics* 2013;3:215-21. doi: [10.1902/cap.2012.120014](https://doi.org/10.1902/cap.2012.120014)
20. Nagahara T, Takeda K, Inoue S, Wada K, Shiba H. Successful regenerative response of a severe bone defect in a right lower central incisor affected by a cemental tear. *Clin Case Rep.* 2022;10(11):e6472. doi: [10.1002/ccr3.6472](https://doi.org/10.1002/ccr3.6472)
21. Gamal AY, Mailhot JM. The effects of EDTA gel conditioning exposure time on periodontitis-affected human root surfaces: surface topography and PDL cell adhesion. *J Int Acad Periodontol.* 2003;5(1):11-22.
22. Song A, Cai J, Pan K, Yang P. Pre-existing root cementum may promote cementoblast differentiation of human periodontal ligament cells. *Cell Prolif.* 2012;45(3):249-58. doi: [10.1111/j.1365-2184.2012.00815.x](https://doi.org/10.1111/j.1365-2184.2012.00815.x)
23. Pei X. New surgery approaches preserving entire papilla to treat isolated interdental intrabony defects: A narrative review. *Clin Exp Dent Res.* 2021;7(5):719-25. doi: [10.1002/cre2.410](https://doi.org/10.1002/cre2.410)
24. Shah EB, Modi BB, Shah MA, Dave DH. Patient centered outcomes in periodontal treatment-an evidence based approach. *J Clin Diag Res.* 2017; 11(4): ZE05-ZE07. doi: [10.7860/JCDR/2017/24260.9631](https://doi.org/10.7860/JCDR/2017/24260.9631)