

Calcium Silicate-based Sealer Extrusion into the Bifurcation of the Mandibular Canal: A Case Report with 36-Month Follow-up

Nazanin Zargar^{1a}, Fatemeh Soltaninejad^{2b}, Seyed Sepehr Mirebeigi Jamasbi^{3c}

^aAssociate professor, Dept. of Endodontics, School of Dentistry, Shahid Beheshti University of Medical Sciences, Tehran, Iran.

^bAssistant professor, Dept. of Endodontics, School of Dentistry, Shahid Beheshti University of Medical Sciences, Tehran, Iran.

^cResearch Committee, School of Dentistry, Shahid Beheshti University of Medical Sciences, Tehran, Iran.

Correspondence to Seyed Sepehr Mirebeigi Jamasbi (Email: sepehr.mirebeigi@sbmu.ac.ir).

(Submitted: 8 June 2024 – Revised version received: 3 July 2024 – Accepted: 9 July 2024 – Published online: Summer 2024)

Objectives: The final phase of root canal therapy involves the obturation of the root canal system to prevent bacterial leakage and ensure successful outcomes. However, during this process, there is a risk of sealer extrusion into vital structures such as the mandibular canal, which can lead to sensory changes like paresthesia.

Case: This report discussed a 40-year-old female case who presented with a crown fracture and a periapical lesion on her endodontically treated mandibular left second molar. During the retreatment, bioceramic sealer was extruded into the mandibular canal. Immediate radiographic evaluation and cone beam computed tomography confirmed the sealer's presence within the sub-branches of the mandibular canal, though the main canal was unaffected. Conservative treatment with ibuprofen and dexamethasone resulted in pain relief and the patient did not experience any neurological deficits such as paresthesia. A 36-month follow-up revealed successful healing of the periapical lesion and absorption of the extruded sealer.

Conclusion: This case highlighted the importance of precise endodontic techniques to prevent sealer extrusion and demonstrated the potential of conservative management in cases of sealer extrusion into sub-branches of inferior alveolar nerve.

Keywords: Bioceramic sealer; Extrusion; Root canal retreatment; Inferior alveolar nerve

How to cite:

Zargar N, Soltaninejad F, Mirebeigi Jamasbi SS. Calcium Silicate-based Sealer Extrusion into the Bifurcation of the Mandibular Canal: A Case Report with 36-Month Follow-up. *J Dent Sch* 2024;42(3):142-146.

Introduction

The last step in root canal therapy (RCT); root canal filling, densely seals the root canal system, trapping bacteria within, and achieves ideal obturation by effectively sealing and precisely stopping at the apical foramen.¹ The success of RCT heavily relies on the effectiveness of the endodontic sealer, which not only seals the space between the dentinal wall and gutta-percha but also fills any irregularities or voids.²

Damage to the inferior alveolar nerve (IAN) is a rare but substantial complication in dental procedures. During root canal treatment, the extrusion of endodontic sealers, intracanal medicaments (e.g. calcium hydroxide), and irrigation solutions into the mandibular canal (MC), which can occur due to perforation resulting from over-instrumentation with manual or rotary instruments, may lead to injury of the IAN.³ As the largest sensory branch of the mandibular nerve and a trigeminal cranial nerve branch, the IAN provides sensory innervation to the mandibular molars and premolars while it courses the MC. It is imperative to prevent foreign material from penetrating this narrow and rigid canal to avoid potential damage to the IAN.²

Although resin-based sealers are recognized for their advantageous physical characteristics, concerns regarding their cytotoxic effects have prompted the field of endodontics to search for alternative sealers.⁴ Obturation using gutta-percha and bioceramic sealers has become popular among endodontists for its biocompatibility and ability to stimulate periapical healing, offering positive biological effects with minimal tissue injury. Recent hypotheses suggest that these

sealers may even enhance root integrity.^{4, 5} In laboratory settings, calcium silicate-based sealers (CSSs) have been found to display anti-inflammatory properties, boost cell viability, and demonstrate superior antibacterial activity compared to epoxy-based and eugenol-based sealers.² Endoseal TCS, a bioceramic sealer employed in single cone technique obturation, have consistently achieved satisfactory obturation quality in both initial endodontic treatment and retreatment, even when resin-based sealers were used in the initial treatment.⁶ However, bioceramic sealers exhibit a higher rate of extrusion compared to resin-based sealers.⁴ Multiple clinical studies have indicated that extrusion of root canal filling material can negatively impact the success of endodontic therapy by acting as a foreign object, leading to irritation of the periradicular tissues, as indicated by clinical manifestations or radiographic periradicular signs.⁷ Although minor extrusions are generally well tolerated by periapical tissues, when they extend into the inferior alveolar canal, reversible or irreversible neurosensory disturbances may result, including pain and various sensory alterations, such as dysesthesia, paresthesia, hypoesthesia, or anesthesia.^{3, 8} The detrimental effects of extruded material on nerves are intricate, involving mechanical compression, cytotoxicity, and neurotoxicity of the material, as well as the potential for local infection and thermal damage. The severity of these effects is influenced by factors such as the extension of the extrusion, the duration of contact with the nerve, and the chemical composition of the material.^{8, 9}

Management of endodontic material extrusion into the MC is a subject of debate among clinicians. While some advocate for conservative approaches involving monitoring and

administration of anti-inflammatory drugs, others advocate for surgical intervention to remove the sealer from the MC. However, surgical treatment does not ensure complete recovery and may increase the risk of secondary nerve damage. Nonetheless, there have been reports of pain resolution and a decrease or elimination of paraesthesia following non-surgical management.^{2, 3, 8}

This report aimed to describe a case with extrusion of endodontic sealer into the MC after root canal retreatment of a mandibular left second molar. Pain relief was achieved solely through pharmaceutical intervention, including anti-inflammatory drugs and corticosteroids.

Case Report

A 40-year-old female with no medical illness (ASA1) presented with a complaint of crown fracture of the mandibular second molar. Coronal decay and leakage were observed clinically. Radiographically, a periapical lesion around the roots indicated inappropriate previous root treatment and underfilling of the canals. Palpation, percussion, and mobility testing yielded normal responses. However, the presence of the radiographic lesion led to the diagnosis of previously treated pulp and asymptomatic apical periodontitis (Figure 1).

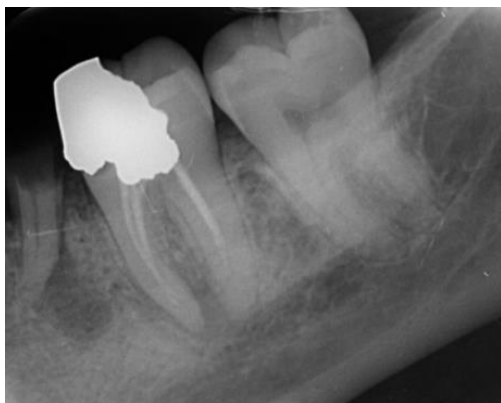

Figure 1: Initial periapical radiograph showing a radiographic lesion

The treatment plan involved endodontic retreatment. After anesthetic injection of 2% lidocaine with 1:100 000 epinephrine (Darou Pakhsh, Tehran, Iran) using the IAN block technique, the previous restoration and the underlying caries were removed and the access cavity was prepared. The canals were prepared using the crown-down technique with manual and rotary methods. The removal of gutta-percha was carried out using the Fanta AF retreatment kit (Fanta Dental, Shanghai, China), which consists of three files. In the coronal third, a size 30, 0.06 taper file was utilized, while in the middle third, a size 25, 0.08 taper file, and in the apical third, a size 20, 0.07 taper file were used. Subsequently, the canals were irrigated with 10 milliliters of normal saline, followed

by alternating use of 5.25% sodium hypochlorite (NaOCl) and 17% ethylenediaminetetraacetic acid (EDTA) for irrigation. A size 10 k-file (Mani Inc, Japan) was utilized in conjunction with an Apex Locator to determine the working length, which was further confirmed through radiography. For the mesial canals, the F2 file (Fanta Dental, Shanghai, China) was employed, while in the distal canal, both the F2 and F3 files were used up to the working length. Irrigation was performed using 5.25% NaOCl and 17% EDTA.

Due to the presence of a periapical lesion and root resorption, Endoseal bioceramic sealer (Maruchi, South Korea) was chosen because of the higher biocompatibility of bioceramic sealers and the enhanced healing facilitated by their characteristics^{2, 5, 10}. The sealer was injected into the canals using a syringe and obturation was completed using lateral condensation technique, which has been shown to yield better results than the single cone technique.¹¹ However, during obturation, sealer extrusion was observed, with the material overextruding into the space of the MC. Immediate bisect radiography confirmed sealer extrusion and the potential risk of its entering the IAN (Figure 2).

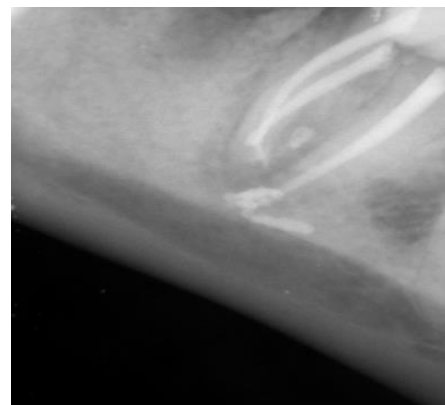

Figure 2: Immediate post-operative periapical radiograph showing sealer extrusion

Cone beam computed tomography (CBCT) was prescribed to assess the extent of sealer intrusion using the NewTom VGI CBCT scanner (QR SRL Co., Verona, Italy). The exposure parameters were set to 110 kVp, 9.5 mA, 0.100 mm voxel size, 0.125 mm axial thickness, and a 6 × 6 cm² field of view. The CBCT revealed that the sealer entered the sub-branches of the MC, but did not breach the main canal (Figure 3). Conservative management was favored over surgical intervention, with ibuprofen 400 mg every six hours and dexamethasone injection prescribed daily for three days to manage postoperative pain.^{12, 13} The patient reported severe pain (without taking analgesics) for up to three weeks and the need to take analgesics regularly, after which she had no problems and there were no reports of paresthesia. Follow-up parallel radiography after three years revealed periapical lesion healing and partial sealer absorption and transformation, indicating successful management of the

extruded sealer (Figure 4). However, the tooth lacked proper crown restoration, and the patient was advised to seek prompt

restoration from their dentist.

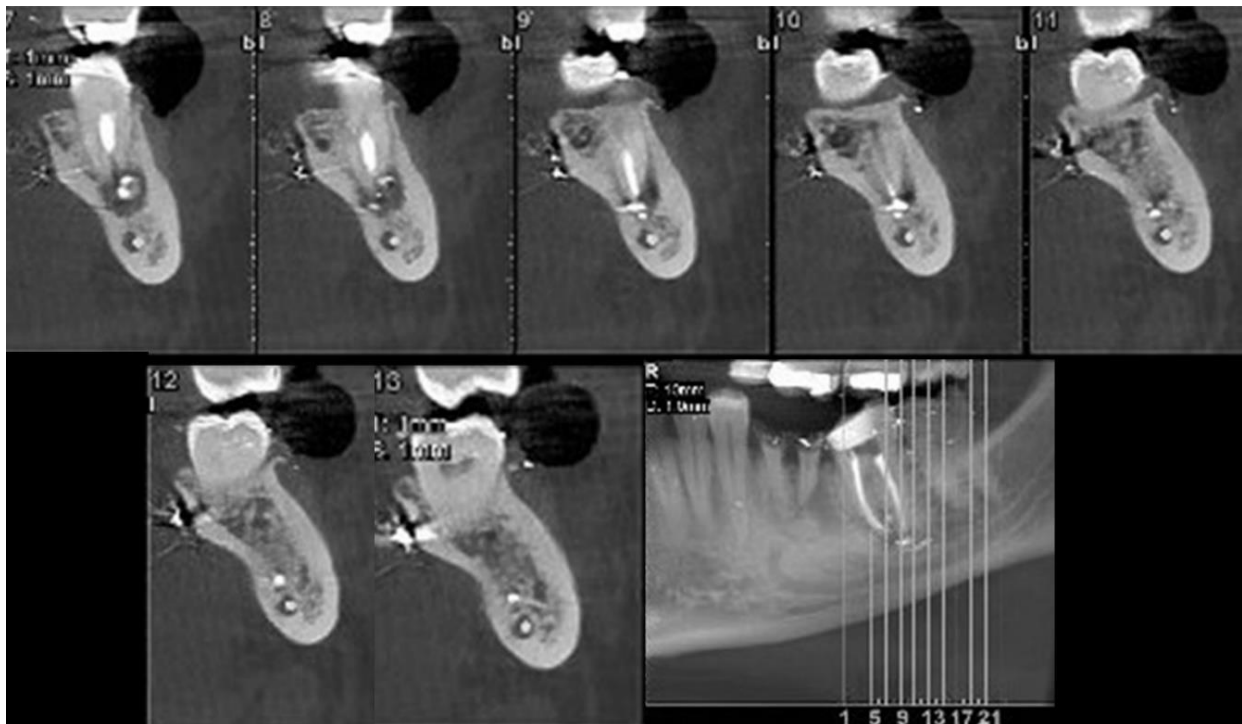


Figure 3: Post-operative CBCT images showed that sealer penetrated the sub-branches of the mandibular canal

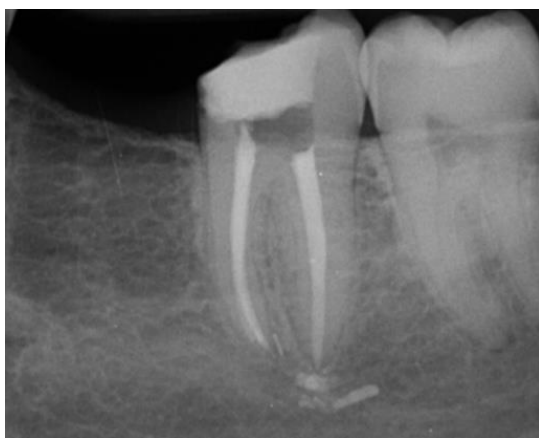

Figure 4: Thirty-six-month follow-up radiography demonstrated periapical lesion healing

Discussion

The IAN passes into the MC via the mandibular foramen after branching from the mandibular nerve². Bifid and trifid canals represent two variations of the IAN. A bifid canal occurs when the nerve splits into two branches, whereas a trifid canal is characterized by the division of the nerve into three branches.¹⁴ Studies employing computed tomography (CT) and/or CBCT imaging techniques have identified a greater prevalence of bifid mandibular canals (BMCs) compared to studies that rely on panoramic radiography.¹⁵ Shah et al. demonstrated that panoramic radiography has a

poor sensitivity of only 11% in identifying BMCs.¹⁶ Studies utilizing CBCT have indicated a broad spectrum in the prevalence of BMCs, spanning from 9.8% to 65%.¹⁴ Research conducted among an Iranian population indicated a notable occurrence of canal branching, with BMCs observed in 131 out of 300 CBCT images (43.7%), showing no side or sex differences.¹⁷

Sensory loss of the IAN and mental nerves most commonly results from surgical procedures like impacted third molar extractions, orthognathic surgeries, dental implant placements, and apical resections in the molar or premolar regions. Less commonly, such sensory deficits may arise following IAN block injections or during endodontic treatments.⁸ About 40% of patients experience postoperative pain (POP) after root canal filling.⁵ During RCT, it is optimal that the filling material stays within the root canal boundaries, as overextending or overfilling obturation of mandibular molars and premolars can potentially lead to iatrogenic damage to the IAN.³ Prior investigations have suggested that female patients exhibit root apices situated in closer proximity to the MC than male patients.¹³ A study conducted on a Brazilian population investigated the proximity and bone density between the root apices of posterior teeth and the MC in 9202 roots. They indicated that the distal root of second molars exhibited the shortest distance to the MC.¹⁸ This finding can justify the situation in the present case of mandibular second molar.

The current report described a case of bioceramic sealer extrusion into the sub-branches of the MC, resulting in temporary POP that was successfully managed conservatively without the need for surgical intervention. Accidental sealer extrusion into the MC can lead to damage caused by mechanical or chemical factors.³ The physical and chemical attributes of the sealer, such as its pH level and consistency, have a direct impact on the level of POP experienced by patients.⁵ Clinical signs indicating extrusion of endodontic material into the MC include immediate or post-treatment acute pain and neurological changes like paresthesia, anesthesia, hypoesthesia, and hyperesthesia.² Accidents involving sealer extrusion, predominantly affecting mandibular molars and resulting in irreversible paresthesia, have been reported. However, such extrusions of CSS do not consistently lead to paresthesia. *In vitro* investigations have demonstrated that CSSs exhibit superior biocompatibility and lower cytotoxicity compared to other endodontic sealers.^{2, 4} However, the physical pressure exerted by the extruded sealer can induce paresthesia, resembling the mechanism observed during dental implant placement where paresthesia can occur without direct contact between the implant and the IAN.²

Various factors contribute to sealer extrusion, including technique-related aspects, properties of the sealer, characteristics of the tooth, and bone density. Exceeding the apical foramen (over-instrumentation beyond the root canal) during the cleaning and shaping process can directly contribute to the occurrence of sealer extrusion.² Additionally, applying excessive vertical pressure during the compaction of the filling material increases the risk of extrusion.¹³ The use of lentulo spirals further increases the likelihood of sealer extrusion into the canal.¹⁹ Injecting sealer into the root canal with backpressure to attain a tight seal is a practice that significantly increases the likelihood of extrusion and should be avoided.² Appropriate sealer flow rates ensure effective filling of all root canal irregularities, while excessive fluidity raises the risk of sealer extrusion. A previous research indicated that bioceramic sealers exhibit superior flow properties compared to resin-based sealers.⁴ Tooth characteristics also play a role, with sealer extrusion being more probable in teeth exhibiting root apex absorption.¹ Bone density is also a factor, with high density serving as a protective measure against potential damage to the IAN. Conversely, low-density trabecular bone, marked by numerous lacunae, may facilitate the leakage of extruded substances toward the nerve.¹³

Preventing the overextension of filling material is important, especially in close proximity to vital anatomical structures like the IAN. Several studies have outlined various approaches to prevent this iatrogenic concern.^{7, 13, 20} A pretreatment radiograph of the mandibular teeth provides insight into the proximity of the IAN to the apices.

Throughout endodontic procedures, radiographs with files in place ensure accurate determination of the working length and mitigate the risk of apical perforation and potential harm to the IAN.²⁰ It is crucial to maintain the same working length during instrumentation, intracanal medication placement, and obturation to prevent injury to the inferior alveolar nerve (IAN).¹³ In cases of teeth with open apices, an alternative treatment option involves a technique called apexification, utilizing materials such as mineral trioxide aggregate (MTA) or calcium hydroxide.⁷ This condition may occur due to factors such as tooth immaturity or apical root resorption. It is recommended to apply gentle pressure during bioceramic sealer injection to avoid extrusion beyond the apex.⁷ Additionally, utilizing side-vented syringes for sealer delivery into the canal can help prevent overextension of the material.

The emergence of acute endodontic pain following RCT should arouse suspicion regarding the extrusion of endodontic material, necessitating timely diagnosis and management to mitigate the potential for permanent nerve injury.^{21, 22} However, addressing the issue of endodontic material extrusion into the MC remains a contentious subject, causing debate within the dental community. Many reports suggest surgical intervention to remove extruded material for alleviating neural toxic effects, notably anesthesia and paresthesia. Additionally, literature mentions adjunctive techniques like steroid use, saline solution irrigation, and supplementation with oral B₁₂ vitamins and adenosine triphosphate (ATP).⁹ Although surgical intervention does not assure complete recovery, delay in treatment may heighten the likelihood of irreversible damage to the IAN.²¹ A systematic review indicated that nonsurgical interventions were more successful in achieving complete recovery of altered sensation compared to surgical methods.¹³ This study emphasized that while there is no assurance of complete sensory restoration, surgical procedures also elevate the risk of further nerve injury. In the present case, given that the main canal remained intact, we opted for a conservative strategy involving ibuprofen, dexamethasone, and regular follow-up. Finally, the pain subsided within three weeks, obviating the need for surgical intervention.

Conclusion

This report presented a case of bioceramic sealer extrusion into the sub-branches of the mandibular canal and suggested that non-surgical management should be considered a viable option, particularly when the sealer has not breached the main mandibular canal. It is crucial for clinicians to employ meticulous techniques during root canal therapy to minimize the risk of extrusion and to consider conservative approaches for managing such complications when they occur.

Acknowledgement: No acknowledgments.

Author Contributions: Nazanin Zargar: supervision, design, data analysis, review & editing the manuscript. Fatemeh Soltaninejad: data acquisition, design, review & editing the manuscript. Seyed Sepehr Mirebeigi Jamasbi: data acquisition, data analysis, Literature search, original draft writing. All authors read and approved the final manuscript.

Funding: No funding was received for this research.

Institutional Review Board Statement: At the time of this study, an IRB approval from Shahid Beheshti University of

Medical Sciences ethics committee was not required for case reports.

Informed Consent Statement: Written informed consent was obtained from the patient for future use of the clinical data and images for scientific purposes.

Data Availability Statement: The datasets used during the current study are available from the corresponding author on reasonable request.

Conflict of Interest: No Conflict of Interest Declared ■

References

1. Li J, Chen L, Zeng C, Liu Y, Gong Q, Jiang H. Clinical outcome of bioceramic sealer iRoot SP extrusion in root canal treatment: a retrospective analysis. *Head Face Med.* 2022;18(1):28.
2. Stanley E, Strother KK, Kirkpatrick T, Jeong JW. Calcium Silicate-based Sealer Extrusion into the Mandibular Canal: 3 Different Recovery Outcomes-A Report of 3 Cases. *J Endod.* 2023;49(6):735-41.
3. Alonso-Ezpeleta O, Martín PJ, López-López J, Castellanos-Cosano L, Martín-González J, Segura-Egea JJ. Pregabalin in the treatment of inferior alveolar nerve paraesthesia following overfilling of endodontic sealer. *J Clin Exp Dent.* 2014;6(2):e197-202.
4. Fonseca B, Coelho MS, Bueno C, Fontana CE, Martin AS, Rocha DGP. Assessment of Extrusion and Postoperative Pain of a Bioceramic and Resin-Based Root Canal Sealer. *Eur J Dent.* 2019;13(3):343-8.
5. Mekhdieva E, Del Fabbro M, Alovisi M, Comba A, Scotti N, Tumedei M, et al. Postoperative Pain following Root Canal Filling with Bioceramic vs. Traditional Filling Techniques: A Systematic Review and Meta-Analysis of Randomized Controlled Trials. *J Clin Med.* 2021;10(19): 4509.
6. Jin HR, Jang YE, Kim Y. Comparison of Obturation Quality between Calcium Silicate-Based Sealers and Resin-Based Sealers for Endodontic Re-treatment. *Materials (Basel).* 2021;15(1):72.
7. Jawami A, Soo E. Iatrogenic Extrusion of Calcium Silicate Cements on Teeth Associated with Large Periapical Lesion: A Case Report with 12-Month Follow-up. *J Dent Indones.* 2022;29:154-9.
8. Szalma J, Soós B, Krajczár K, Lempel E. Piezosurgical management of sealer extrusion-associated mental nerve anaesthesia: A case report. *Aust Endod J.* 2019;45(2):274-80.
9. Froes FG, Miranda AM, Abad Eda C, Riche FN, Pires FR. Non-surgical management of paraesthesia and pain associated with endodontic sealer extrusion into the mandibular canal. *Aust Endod J.* 2009;35(3):183-6.
10. Giacomino CM, Wealleans JA, Kuhn N, Diogenes A. Comparative Biocompatibility and Osteogenic Potential of Two Bioceramic Sealers. *J Endod.* 2019;45(1):51-6.
11. Alghamdi NS, Alamoudi RA, Baba SM, Mattoo K, Abu Havi RH, Ali WN, et al. A Scanning Electron Microscopy Study Comparing 3 Obturation Techniques to Seal Dentin to Root Canal Bioceramic Sealer in 30 Freshly Extracted Mandibular Second Premolars. *Med Sci Monit.* 2023;29:e940599.
12. Alajlan N, Carrasco-Labra A, Karabucak B, Lee SM. Systemic Corticosteroid Uses in Endodontics-Part 1: Managing Postoperative Pain. *J Endod.* 2024;50(6):724-34.
13. Alves FRF, Dias MCC, Mansa M, Machado MD. Permanent Labiomandibular Paresthesia after Bioceramic Sealer Extrusion: A Case Report. *J Endod.* 2020;46(2):301-6.
14. Elnadoury EA, Gaweesh YSE, Abu El Sadat SM, Anwar SK. Prevalence of bifid and trifid mandibular canals with unusual patterns of nerve branching using cone beam computed tomography. *Odontology.* 2022;110(1):203-11.
15. von Arx T, Bornstein MM. The bifid mandibular canal in three-dimensional radiography: morphologic and quantitative characteristics. *Swiss Dent J.* 2021;131(1):10-28.
16. Shah NP, Muradha L, Brown J. Bifurcation of the inferior dental nerve canal: an anatomical study. *Br J Oral Maxillofac Surg.* 2018;56(4):267-71.
17. Khojastepour L, Nasiri MM, Hashemi K, Ahrari F. Mandibular Canal Branching Assessed With Cone-Beam Computed Tomography. *J Craniofac Surg.* 2023;34(8):e767-71.
18. Oliveira ACS, Candeiro GTM, Pacheco da Costa FFN, Gazzaneo ID, Alves FRF, Marques FV. Distance and Bone Density between the Root Apex and the Mandibular Canal: A Cone-beam Study of 9202 Roots from a Brazilian Population. *J Endod.* 2019;45(5):538-42.e2.
19. Çulha E, Tunç F. Extrusion of Root Canal Filling Materials in Molars of a Turkish Subpopulation. *Eurasian Dental Research.* 2023;1(2):35-9.
20. Abdul Haleem S. Radiographic Assessment of Post-Endodontic Pain. *Indian J Forensic Med Toxicol.* 2021; 15(2): 1641-7.
21. Kudoh K, Takaishi K, Kudoh T, Takamaru N, Kamada K, Miyamoto Y. Inferior alveolar nerve paresthesia caused by the extrusion of calcium hydroxide-based paste into the mandibular canal: A case report. *J Oral Maxillofac Surg Med Pathol.* 2020; 32(5):366-9.
22. Zawrzykraj E, Krużyński W, Radwański M, Łukomska-Szymańska M. Causes of post-operative pain related to root canal treatment. *J Stoma.* 2022; 75(3):201-5.