

Comparing the Diagnostic Accuracy of PSP Digital Intraoral Receptor Software Options in Assessment of Vertical Fractures of Mandibular Posterior Teeth

Paniz_Ranji ^a, Ladan Hafezi ^b, Fatemeh Lotfi ^c

^aAssistant Professor, Dept. of Maxillofacial Radiology, School of Dentistry, Shahid Beheshti University of Medical Sciences, Tehran, Iran.

^bAssociate Professor, Dept. of Maxillofacial Radiology, Dental Branch, Islamic Azad University, Tehran, Iran.

^cDentistry Student, School of Dentistry, Shahid Beheshti University of Medical Science, Tehran, Iran.

Correspondence to Fatemeh Lotfi (email: f.lotfi.1396f@gmail.com).

(Submitted: 27 November 2022 – Revised version received: 1 January 2023 – Accepted: 9 January 2023 – Published online: Summer 2023)

Objectives Root fracture detection may be a challenging process due to difficulties in clinical and radiographic assessments. This study compared the diagnostic efficacy of Photostimulable Phosphor (PSP) intraoral digital receptor software alternatives for detection of vertical fractures in mandibular posterior teeth.

Methods In this diagnostic research, 60 human mandibular posterior teeth were chosen. Vertical fracture was induced on half of teeth using a hammer through a random method. Thereafter, the broken pieces were glued together using a superglue, and placed inside a sheep mandible. Next, utilizing a digital intraoral technique and a PSP sensor, radiographic images of every tooth were taken. All radiographies were then subjected to computer adjustments such as sharpening, reverse-contrast, and enhancement. Three radiologists investigated the images of teeth after application of computer adjustments regarding existence of fracture. SPSS 22 was used for data analysis.

Results Among processed images, sharpness had the highest accuracy (89.3%) followed by enhancement (89%), and reverse-contrast (87%). Statistically, no significant difference was observed in diagnosis of vertical fractures of mandibular posterior teeth regarding sensitivity, specificity, accuracy, as well as positive and negative predictive value among main images (no effect) and the images on which sharpness, reverse-contrast, and enhancement by software were applied (P -value >0.05). For intra-observer agreement, Kappa value > 0.70 and for inter-observer agreement, kappa value=0.50-0.7 were found.

Conclusion Usage of sharpness, reverse-contrast, and enhancement software had no significant impact in diagnosing vertical root fracture of multi-rooted teeth (P -value >0.05).

Keywords Dental digital radiography; Tooth fracture; Image enhancement

Introduction

Radiographic diagnosis of root fracture has always been a difficult task for clinicians. Vertical/horizontal fractures of tooth root (VRF/HRF) are always considered a challenge in diagnosis; this is in terms of difficulty of their detection, and recognition on intraoral radiographs, except for cases where there are very specific clinical findings. Due to the diagnostic difficulties, tooth extractions, reduced long-term tooth prognosis, and significant bone loss would result. In general, root fractures account for 0.5–7% of all permanent tooth damages.^{1, 2} Conventional analogue or digital plain intraoral radiographies are the most common type of radiography in detecting root fractures. These fractures can be evaluated via routine dental examinations.^{1, 3}

In the science of radiology, root fractures were detected from the time when two-dimensional radiography was used in 1896 in dentistry. Today, for the detection of root fracture, Photostimulable Phosphor (PSP) is used for digital intraoral radiography.⁴ By enabling a broad variety of manual adjustments such as brightness, contrast, and other software choices to digital radiographs captured by PSP sensors, interpretation enhancement occurs.^{5, 6} A second radiography due to exposure-induced mistakes might be avoided by manually altering the contrast and density of digital images.⁷ So far, most studies were done on software improvement of images in the diagnosis of single periapical lesions and proximal caries^{8, 9}, while there is a gap of information regarding dental root fracture.

This research was performed to compare the accuracy of digital intraoral radiography (two-dimensional) with PSP sensor against software options of sharpness, reverse-contrast, and enhancement to detect presence or absence of vertical root fracture in the radiology department of dentistry unit of Islamic Azad University, Tehran, Iran.

Methods and Materials

This cross sectional in-vitro study was performed after the approval of research proposal in the research committee of faculty of dentistry of Islamic Azad University on 4 July 2013. 60 human mandibular posterior teeth, which were extracted due to orthodontic reasons, and had no crack, fracture, or canal filling, were collected.

The teeth were randomly numbered. The site of teeth were scratched with a bur for positioning and fixation of teeth in the sheep mandible. Using a random procedure and a mallet on the root of the teeth, fifty percent of the teeth were fractured. The teeth were then reintegrated to the initial form using a superglue and placed inside the socket consecutively (Figure 1).

Then, 24 images were prepared via PSP sensor (through parallel method using a film holder and by using a DIGORA OPTIM device (SORDEX Co., Finland) at $t=0.1$ s, $kvp=70$, $mA=8$, and resolution 3.14 lp/mm), and saved in the device storage. The results of this stage were recorded as the control group and further assessed by three radiologists (three oral radiology senior students)

separately and without knowing the distribution of fractures. Following a week of observation of the original radiographs, manual adjustments such as sharpening(once), reverse-contrast, and enhancement were made to each image. After applying the software changes, 96 radiography images were prepared (Figure 2), and the results obtained from investigation of images were recorded in the relevant information forms. After two weeks, each radiologist reinvestigated the results via the same method (intraobserver, interobserver). The obtained results were compared with each other for reliability. The results were analyzed using statistical indices, including specifically, sensitivity, accuracy, positive predictive value, and negative predictive value, as well as kappa coefficient. For data analysis, SPSS 22 was used.

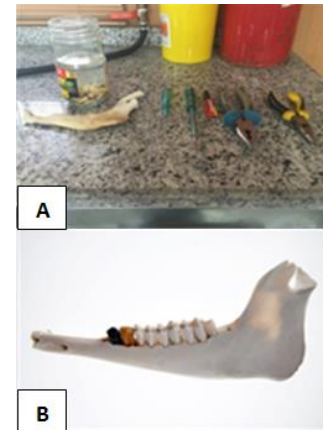


Figure 1: Creating a fracture with a hammer on the roots of the teeth (A) and placing them in the sheep's mandible with drop glue (B).

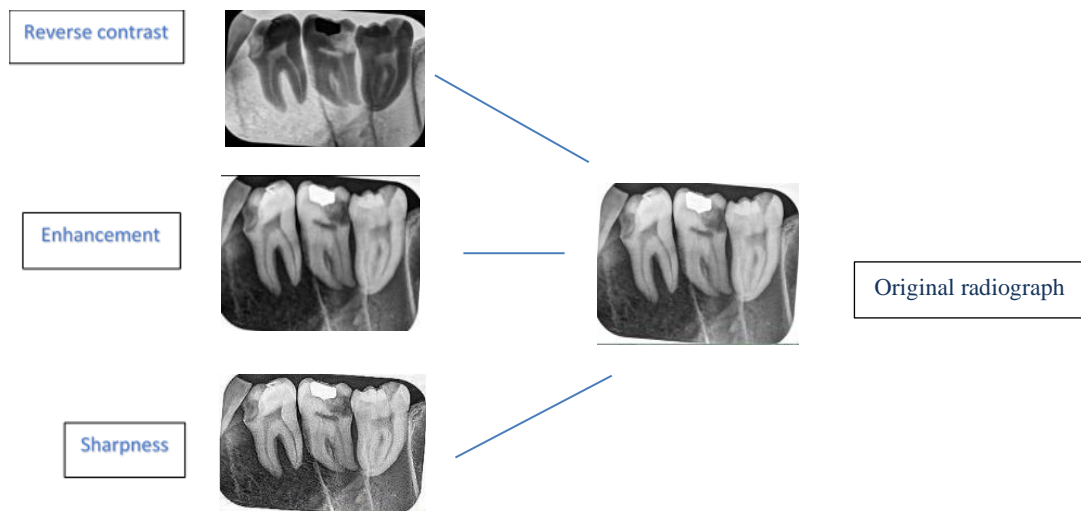


Figure 2: Applying software changes (Reverse contrast, Enhancement and Sharpness) on the original images.

Results

A total of 96 radiographic images (original images with no effect, sharpened images, reverse-contrast images and enhanced imaged) were assessed and results are reported in in Tables 1 and 2. Sharpness had the highest accuracy among the processed photos (89.3%), followed by enhancement (89%) and reverse-contrast (87%). Statistically, no significant

difference was observed in the diagnosis of vertical fracture of mandibular posterior teeth in terms of specificity, sensitivity, accuracy, positive predictive value, and negative predictive value among original images (effect free) and the images to which sharpness, reverse-contrast, and enhancement were applied by software (P-value>0.05). For intraobserver agreement, kappa value>0.7 and for inter observer agreement, kappa value=0.5-0.7 were found.

Table 1- Diagnostic results according to the 4 studied methods

Person	Method	Time	Sensitivity	Specificity	PPV	NPV	Accuracy	P value
1	No effect	first	93.3%	86.7%	87.5%	92.9%	90%	.0001
		second	93.3%	86.7%	87.5%	92.9%	90%	
		Mean	93.3%	86.7%	87.5%	92.9%	90%	
	Enhancement	first	93.3%	86.7%	87.5%	92.9%	90%	.0001
		second	93.3%	83.3%	84.8%	92.6%	88%	
		Mean	93.3%	85%	86.1%	92.7%	89%	
	Reverse contrast	first	93.3%	83.3%	84.8%	92.6%	88%	.0001
		second	93.3%	80%	82.4%	92.3 %	86%	
		Mean	93.3%	81.6%	83.6%	92.4%	87%	

(Table-1 Continued)								
2	Sharpness	first	93.3%	86.7%	87.5%	92.9 %	90%	.0001
	Sharpness	second	93.3%	86.7%	87.5%	92.9%	90%	
	Mean		93.3%	86.7%	87.5%	92.9%	90%	
	No effect	first	76.7%	70%	71.9%	75%	90%	.0001
	No effect	second	80%	73.3%	75%	78.6%	90%	
	Mean		78.3%	71.6%	73.4%	76.8%	90%	
	Enhancement	first	76.7%	70%	71.9%	75%	90%	.0001
	Enhancement	second	80%	73.3%	75%	78.6%	88%	
	Mean		78.3%	71.6%	73.4%	76.8%	89%	
	Reverse contrast	first	73.3%	70%	71%	72.4%	88%	.0001
	Reverse contrast	second	76.7%	70%	71%	75%	86%	
	Mean		75%	70%	71%	73.7%	87%	
3	Sharpness	first	76.7%	70%	71%	75%	88%	.0001
	Sharpness	second	80%	73.3%	75%	78%	88%	
	Mean		73.8%	71.6%	73%	76.5%	88%	
	No effect	first	76.7%	80%	79.3%	77.4%	90%	.0001
	No effect	second	76.7%	86.7%	85.2%	78.8%	90%	
	Mean		76.7%	83.3%	82.2%	78.1%	90%	
	Enhancement	first	76.7%	80%	79.3%	77.4%	90%	.0001
	Enhancement	second	73.3%	86.7%	85.2%	78.8%	88%	
	Mean		76.7%	83.3%	82.2%	78.1%	89%	
	Reverse contrast	first	73.7 %	76.7%	75.9%	74.2%	88%	.0001
	Reverse contrast	second	73.3%	80%	78.6%	75%	86%	
	Mean		73.5%	78.3%	77.2%	74.6%	87%	
Sharpness	first	73.3%	76.7%	75.9%	74%	90%	.0001	
Sharpness	second	73.3%	80%	78.6%	75%	90%		
Mean		73.3%	78.3%	77.2%	74.5%	90%		

Table 2- The results of observer agreement in 4 methods

Kappa Value	Method	observer	Type
0.993	No effect	first	Intra observer
0.966	Enhancement		
0.966	Reverse-Contrast		
0.933	Sharpness		
0.866	No effect	second	
0.866	Enhancement		
0.900	Reverse-Contrast		
0.866	Sharpness		
0.866	No effect	third	
0.866	Enhancement		
0.900	Reverse-contrast		
0.900	Sharpness		
0.598	No effect	First and second	Inter observer
0.614	Enhancement		
0.564	Reverse-contrast		
0.608	Sharpness		
0.535	No effect	First and third	
0.535	Enhancement		
0.536	Reverse-contrast		
0.535	Sharpness		
0.668	No effect	Second and third	
0.668	Enhancement		
0.701	Reverse-contrast		
0.651	Sharpness		

Discussion

Vertical root fractures (VRF) have always been a challenge

in dentistry because of their difficult diagnosis and detection in intraoral radiographies. This difficulty in detection would result in unnecessary dental extraction,

diminished long-term prognosis of the teeth, and extensive bone loss. Researchers have long sought for more thorough imaging techniques in light of the limitations of traditional radiography, and digital radiography now stands as an alternative to this.¹⁰ It seems that the ability of digital images, and conventional films in detecting root fracture in single-rooted teeth is the same, but the difficulty increases considerably in multi-rooted teeth.¹¹

Dr Sabaghian et al. reported that ultimately the highest sensitivity, specificity, and overall accuracy in detecting root fracture are related to average-contrast images, followed by low-contrast ones, while minimum sensitivity, specificity, and overall accuracy belong to high-contrast images. Thus, average contrast can be accepted as a processing filter to detect vertical root fractures.¹²

Dr Ghazizadeh et al. reported that reverse-contrast and color-enhancing filters cannot be used as vital methods in vertical and horizontal root under in vitro conditions.¹³

According to Dr. Choi et al., various diagnostic concerns led to differing interpretations of how the contrast of images changed. It was stated that the only reliable diagnostic technique for dental caries was average contrast. Average and relatively high contrast outperformed the original images for periapical lesions. For evaluating periodontal disease, none of the methods showed superiority over another.⁷

Dr Belem et al. reported that there was no significant difference in the diagnosis of fine demineralizations of proximal enamel surfaces between PSP digital radiography and CBCT images and while CBCT showed a partially greater accuracy compared to other methods. Therefore, these methods can be used as complement to each other, which is in line with the present study findings.¹⁴

Although Dr Tofangchiha et al. reported that there is no significant difference between original and processed images, the original images were better than those on which software effects was applied. According to their comments, using reverse-contrast and colorized digital images to identify root fractures should be seen as an additional diagnostic tool to be used in conjunction with other diagnostic techniques rather than as a primary diagnostic tool.¹⁵ In the report by Bechara et al., it was found that when comparing CBCT and PSP systems, small Field of View (FOV) images had a significantly greater accuracy and sensitivity to detect dental fractures compared to large FOV and enhanced PSP images. The specificity of PSP-enhanced images was slightly greater than that of small FOV, and considerably higher than that of large FOV images. Therefore, it was determined that small FOV images were appropriate for identifying fractures in teeth that had undergone endodontic treatment. Digital radiography of the PSP type was shown to be a low-risk technique since the images it produced had the lowest false positive rate.¹⁶ Dr Kamburoglu et al. reported that

pseudo3D, zooming, sharpness, and reverse contrast software had no effect on the outcome of VRF diagnosis in vitro, which concurs with the present study.¹⁷

Dr Kositbowornchai et al. reported that there was no significant difference in the sensitivity, specificity, as well as positive and negative predictive value of digital images when their magnifications were 2:1, 1:2 and 1:1. Thus, these three magnifications did not affect diagnosis of root fracture.¹⁸

In agreement with the current research, Dr. Sakhdari et al. found that preparing pictures with a 0° vertical angle rather than a 15° angle was more appropriate and that this improved the capacity to detect horizontal root fracture in digital reverse-contrast images.¹⁹ It seems that in spite of studying different lesions and applying different software adjustments in the above papers compared to present research, the diagnostic ability of software has been the same, and they overlap with each other in this respect. In cases where there are clear clinical symptoms for the diagnosis of root fracture, they can be used for improving the efficiency and assisting diagnosis, which would undoubtedly be influenced by the observer experience. In case of presence of differential diagnoses alongside root fracture, considering the slightly better accuracy of CBCT technique, it can be used alongside other above-mentioned methods as a complement.

Regarding features provided by digital systems in this study, we employed enhancement, reverse-contrast, and sharpness software with the minimum value. This was because so far no study was done comparing the diagnostic accuracy of vertical fracture by these software applications against the original image especially in multirouted teeth.

The results showed that among processed images, sharpness had the highest accuracy (89.3%), followed by enhancement (89%) and reverse-contrast (89%). Statistically, there was no significant difference in the diagnosis of vertical fractures of mandibular posterior teeth regarding sensitivity, specificity, accuracy, and positive predictive value between the original images (effect-free) and the images on which sharpness, reverse-contrast, and enhancement software had been applied (P-value>0.05).

The limitations of the present study were as follows:

1. Collecting extracted molar teeth without fracture and canal filling.
2. Difficulty of creating a suitable vertical fracture in teeth that have not had endodontic treatment. Since force could not be applied in a controlled manner, several teeth were subjected to horizontal or oblique fracture, which eliminated them from the experiment.

Conclusion

There were no significant differences between usage of sharpness, reverse-contrast, and enhancement software in

detection of vertical root fractures of multirooted teeth (P-value>0.05).

No Conflict of Interest Declared ■

Conflict of Interest

References

1. Edlund M, Nair Mk, Nair UP. Detection of vertical root fractures by using cone beam computed tomography: A clinical study. *J Endod.* 2011 Jun;37(6):768-72.
2. Farman AG, Farman TT. A comparison of 18 different x-ray detectors currently used in dentistry. *Oral Surg Oral Med Oral Pathol Oral Radiol Endod.* 2005 Apr;99(4):485-9.
3. Yig'it O'zer S. Detection of vertical root fractures by using cone beam computed tomography with variable voxel sizes in an in vitro model. *J Endod.* 2011 Jan;37(1):75-9.
4. Gilley DB. The Conference of Radiation control program directors (CRCPD). *Osti gov.* 2008.
5. Oshagh M, Shahidi SH, Momeni Danaei SH. Effects of image enhancement on reliability of landmark identification in digital cephalometry. *Indian J Dent Res.* 2013; 24(1):98-103.
6. Benjamin S. Phosphor plate radiography: an integral component of the filmless practice. *Dent Today.* 2010; 29(11):89.
7. Han WJ, Kim EK, Choi JW. Image enhancement of digital periapical radiographs according to diagnostic tasks. *Imaging Sci Dent.* 2014; 44(1):31-5.
8. Avant SL, Scarfe WC, Farman TT, Green DB Farman AG. In vivo comparison of Visualix-2 and Ektaspeed Plus in the assessment of periradicular lesion dimensions. *Oral Surg Oral Med Oral Pathol Oral Radiol Endod.* 1998; 85:203-9.
9. Petersson K, Rohlin M, Kullendorff B. Direct digital radiography for the detection of periapical bone lesions: a clinical study. *Endod Dent Traumatol.* 1997; 13:183-9.
10. Pharoah MJ, White SC. *Oral Radiology, Principles and Interpretation.* 5th ed. St.Louis, 2003. Page??
11. Fardi A, Giannopoulou M, Parisi N, Kondylidou-Sidira A. Detection of experimentally induced root fractures on digital and conventional radiographs: an in vitro study. *Odontology.* 2013;101(1):89-95.
12. Habibi Kia A, Dabaghi A, Javaheri MA, Sabaghian M. Evaluation of Contrast Alternation Efficacy in Diagnosis of Vertical Root Fracture in Conventional Digital Radiography (An Ex-vivo Study). *J Med Sci (Jundishapur).* 2022; 20(6):680-9.
13. Ghazizadeh M, Sheikhi M, Aminian M, Ghazizadeh MM, "Accuracy of digital image enhancement in detection of vertical and horizontal root fracture," *Dent Res J (Isfahan).* 2020; 17(4): 266-72.
14. Belém MD, Tabchoury CP, Ferreira-Santos RI, Groppo FC, Haiter-Neto F. Performance of a photostimulable storage phosphor digital system with or without the sharpen filter and cone beam CT for detecting approximal enamel subsurface demineralization. *Dentomaxillofac Radiol.* 2013; 42(5):20120313.
15. Tofangchiha M, Bakhshi M, Shariati M, Valizadeh S, Adel M, Sobouti F. Detection of vertical root fractures using digitally enhanced images: reverse-contrast and colorization. *Dent Traumatol.* 2012; 28(6):478-82.
16. Bechara B, McMahan CA, Noujeim M, Faddoul T, Moore WS, Teixeira FB, et al. Comparison of cone beam CT scans with enhanced photostimulated phosphor plate images in the detection of root fracture of endodontically treated teeth. *Dentomaxillofac Radiol* 2013; 42(7):20120404.
17. Kamburoğlu K, Murat S, Pehlivan SY. The Effects of Digital Image Enhancement on the Detection of Vertical Root Fractures. *Dent Traumatol.* 2010 Feb;26(1):47-51.
18. Kositbowornchai S, Sikram S, Nuansakul R, Thinkhamrop B. Root fracture detection on digital images: effect of the zoom function. *Dent Traumatol.* 2003; 19(3):154-159.
19. sakhdari S, mehralizadeh S, dadresanfar B, hakim M, Kharazifard M J. Accuracy of reverse contrast option of digital radiography in detection of horizontal root fracture.(in vitro). *J Res Dent Sci.* 2011; 8 (2) :68-74.

How to cite:

Ranji P, Hafezi L, Lotfi F. Comparing the Diagnostic Accuracy of PSP Digital Intraoral Receptor Software Options in Vertical Fractures of Mandibular Posterior Teeth. *J Dent Sch* 2022;40(4):138-142.