

Cutaneous Metastatic Undifferentiated Carcinoma to the Mandibular Gingiva: A Rare Case Report

Saede Atarbashi-Moghadam ^a, Ali Lotfi ^b, Fazele Atarbashi-Moghadam ^a

^aAssociate Professor, Dept. of Oral and Maxillofacial Pathology, School of Dentistry, Shahid Beheshti University of Medical Sciences, Tehran, Iran.

^bAssistant Professor, Dept. of Oral and Maxillofacial Pathology, School of Dentistry, Shahid Beheshti University of Medical Sciences, Tehran, Iran.

^cAssociate Professor, Dept. of Periodontics, School of Dentistry, Shahid Beheshti University of Medical Sciences, Tehran, Iran.

Correspondence to Fazele Atarbashi-Moghadam (email: dr.f.atarbashi@gmail.com).

(Submitted: 19 November 2022 – Revised version received: 01 December 2022 – Accepted: 03 December 2022 – Published online: Winter 2023)

Objectives Metastasis to the oral cavity is a rare phenomenon. Basal cell carcinoma (BCC) is the most common skin malignancy, followed by squamous cell carcinoma (SCC) and melanoma. Nevertheless, BCC rarely metastasizes, and most cases of cutaneous metastasis to the oral cavity include melanoma and SCC. Oral metastatic lesions are not typical differential diagnoses and may cause diagnostic challenges.

Case In this paper, we present the case of a 36-year-old female patient with a rapidly growing gingival mass. She had a history of undifferentiated skin carcinoma almost 18 months ago. An incisional biopsy was performed, and according to microscopic findings and medical history, a diagnosis of undifferentiated metastatic carcinoma was made.

Conclusion Oral metastasis needs to be considered in the differential diagnosis of lesions in patients with a history of malignancy.

Keywords Undifferentiated carcinoma; Skin; Metastasis; Oral cavity

Introduction

Oral metastasis is a rare phenomenon, which accounts for almost 1-1.5% of all oral cancers. ¹ It is a major cause of morbidity and mortality in cancer patients, which typically occurs in the jaws rather than soft tissues. ² There is a male predilection, and it is commonly reported in the fifth to seventh decade of life. ^{3,4} The most involved regions are the lungs in males and breasts in females. ⁵

Among skin malignancies, melanoma has a high potential for metastasis to other tissues. ⁶ Oral metastases commonly have a poor prognosis and are associated with widespread cancer. ² In this paper, we present the clinical, microscopic, and immunohistochemical (IHC) findings of undifferentiated cutaneous metastatic carcinoma to the oral cavity in a 36-year-old woman.

Case Report

A 36-year-old woman was referred to our center with a rapidly growing gingival mass around the buccal and distal aspects of the right mandibular second molar, extending to the first molar, measuring 2.5×1 cm² over one month. The lesion was covered with erythematous epithelium with indurated borders and firm consistency (Figure 1). Eighteen months earlier, she had undergone a wide surgical excision, radiotherapy, and dissection of inguinal lymph nodes for a cutaneous mass adjacent to the umbilicus, which was diagnosed as undifferentiated carcinoma. One lymph node was involved with metastatic deposits. An incisional biopsy with a provisional diagnosis of lymphoma and metastatic cancer was carried out. The cut surface of the lesion was

solid, creamy, and homogenous.

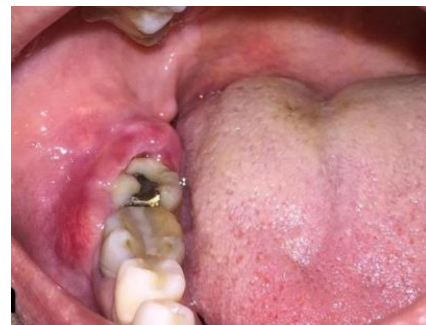

Figure 1: The image shows a gingival mass around the buccal and distal aspects of the right mandibular second molar extending to the first molar at the first visit.

Microscopic sections showed a malignant epithelial tumor, composed of sheets and islands of large polyhedral epithelial cells with large vesicular nuclei in a fibrous stroma. Prominent cellular pleomorphism, hyperchromatism, and mitosis were also observed (Figures 2 & 3). The IHC staining for cytokeratin 7 (CK7) was positive (Figure 4). Tumor cells were negative for CK20, MelanA, CD34, mucin-2 (MUC-2), carcinoembryonic antigen (CEA), and thyroid transcription factor 1 (TTF-1). A Spiral CT scan of the neck showed multiple lung masses with metastasis. The visceral component of the neck was normal, and there was no evidence of cervical lymphadenopathy. After two weeks, she returned with a large proliferative mass with an erythematous surface and ill-defined borders (Figure 5). According to the histopathological features, IHC findings, and medical history, a diagnosis of undifferentiated metastatic carcinoma was made. She was referred to an oncologist for chemotherapy.

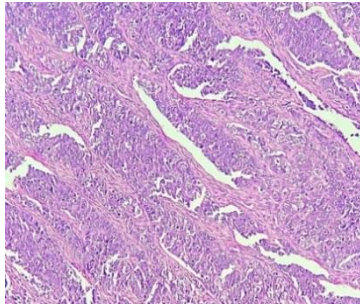


Figure 2: Microscopic sections show islands of large malignant polyhedral epithelial cells in a fibrous stroma (H&E staining, ×100 magnification).

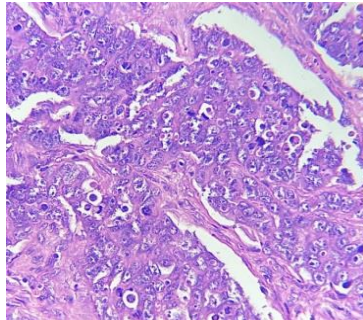


Figure 3: Malignant epithelial islands demonstrate large vesicular nuclei (H&E staining, ×400 magnification).

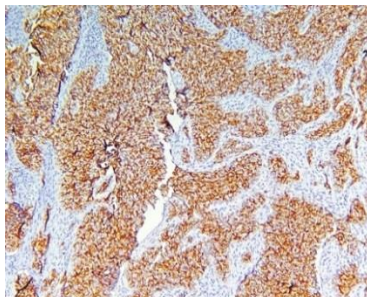


Figure 4: Diffuse expression of CK7 in the cytoplasm of tumor cells (IHC staining, ×100 magnification).

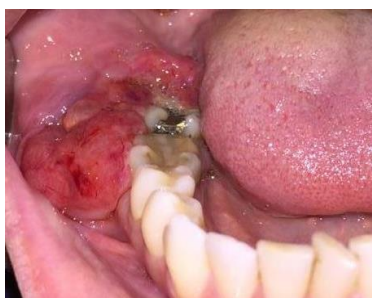

Figure 5: The image shows a large proliferative mass with an erythematous surface and ill-defined borders two weeks after the first visit.

Discussion

Oral metastatic lesions are not common differential diagnoses because of their scarcity and unusual clinicopathological characteristics, leading to diagnostic challenges.⁷ Distant metastasis is not an accidental phenomenon and is controlled by a site-specific route.² The process of metastatic spread is related to the

inherent characteristics of the tumor and the host response. Moreover, ethnic or geographic differences are known to contribute to the variability and frequency of oral metastasis.¹

Kirschnick et al.³ found that Asia accounts for the majority of oral and maxillofacial metastasis cases, followed by Europe and America. Although basal cell carcinoma (BCC) is a common skin malignancy with a locally invasive behavior, it rarely metastasizes. Lymph nodes are the most common sites of metastasis.⁸ Among skin cancers, melanoma accounts for 90% of skin metastases, and BCC is responsible for 10% of cases.⁵ Additionally, Kaplan et al.¹ found that skin metastasis to the oral cavity included melanoma, followed by squamous cell carcinoma (SCC), although metastatic cutaneous carcinosarcoma, BCC, angiosarcoma, and Merkel cell carcinoma to the oral lesion have been also reported.^{5, 8-10} It typically occurs in older adults, with a mean age of 67.7 years.¹ Kaplan et al.¹ reported that in their series, only 5% of patients were under 40 years. Our patient was in the fourth decade of life. The attached gingiva is the most common site of oral soft tissue metastasis, which usually resembles reactive lesions, such as pyogenic granuloma.⁶ However, in our patient, the lesion showed indurated borders, which evoked malignancy. Besides, within two weeks of the patient's first visit to our center, the size of the lesion nearly doubled.

Oral metastasis is frequently detected in the final stage of a malignant tumor and represents a widespread disease.² Our patient also showed a widespread disease. It is assumed that metastasis to oral regions spreads from other primary metastatic lesions, most commonly the lungs. Nevertheless, oral metastasis may be the first sign of cancer in about 30% of cases.¹ The prognosis of patients with oral metastasis is poor, with a mean survival time of seven months.³ For intraoral metastasis, palliative treatment, including chemotherapy and/or radiotherapy, is recommended. In the case of a single metastatic focus, surgical excision may be preferred for controlling the metastatic lesion.⁵

Conclusion

Oral metastasis needs to be considered in the differential diagnosis of lesions in patients with a history of malignancy. Reports of infrequent cases, such as our patient, can increase our knowledge of the characteristics of metastatic lesions to the oral cavity.

Conflict of Interest

No Conflict of Interest Declared ■

References

- 1- Kaplan I, Raiser V, Shuster A, Shlomi B, Rosenfeld E, Greenberg A, et al. Metastatic tumors in oral mucosa and jawbones: Unusual primary origins and unusual oral locations. *Acta Histochem.* 2019; 121(8):151448.
- 2- Irani S. Metastasis to the oral soft tissues: A review of 412 cases. *J Int Soc Prev Community Dent.* 2016; 6(5):393-401.
- 3- Kirschnick LB, Schuch LF, Cademartori MG, Vasconcelos ACU. Metastasis to the oral and maxillofacial region: A systematic review. *Oral Dis.* 2022; 28(1):23-32.
- 4- Hirshberg A, Shnaiderman-Shapiro A, Kaplan I, Berger R. Pathogenesis and analysis of 673 cases. *Oral Oncol.* 2008; 44(8):743–52.
- 5- Tanaka N, Hidaka S, Yamamura M, Ohyama H, Urade M. Metastatic cutaneous carcinosarcoma to the tongue. *Int J Oral Maxillofac Surg.* 2010; 39(10):1033-6.
- 6- Markman RL, Rosa GA, Cardili L, Simonato LE, Brandão TB, Ribeiro AC. Tongue metastasis of cutaneous melanoma: Report of two cases and literature review. *J Clin Exp Dent.* 2018; 10(11):e1130-4.
- 7- Titinchi F, Opperman J, Jones MD. Metastatic amelanotic melanoma to the mandible mimicking benign odontogenic neoplasm. *Oral Oncol.* 2021; 116:105141.
- 8- Blinder D, Taicher S. Metastatic basal cell carcinoma presenting in the oral cavity and auditory meatus. A case report and review of literature. *Int J Oral Maxillofac Surg.* 1992; 21(1):31-4.
- 9- Tanabe K, Masuzawa M, Aki R, Masuzawa M, Arai S, Hayakawa K, et al. Angiosarcoma of the scalp with metastasis to the gingiva. *Acta Derm Venereol.* 2008; 88(5):512-3.
- 10- Li M, Saghafi N, Freymiller E, Basile JR, Lin YL. Metastatic Merkel cell carcinoma of the oral cavity in a human immunodeficiency virus-positive patient and the detection of merkel cell polyomavirus. *Oral Surg Oral Med Oral Pathol Oral Radiol.* 2013; 115(5):e66-71.

How to cite:

Atarbashi-Moghadam S, Lotfi A, Atarbashi-Moghadam F. Cutaneous Metastatic Undifferentiated Carcinoma to the Mandibular Gingiva: A Rare Case Report. *J Dent Sch* 2022;40(1):36-38.