

# Extremely Large Mental Foramina in a Rare Case of Oral Hemangiolympangioma

Mitra Ghazizadeh Ahsaie <sup>a</sup>, Mina Iranparvar Alamdari <sup>a</sup>, Masoud Mohammadpour <sup>b</sup>

<sup>a</sup>Assistant professor, Dept. of Oral and Maxillofacial Radiology, School of Dentistry, Shahid Beheshti University of Medical Sciences, Tehran, Iran.

<sup>b</sup>Resident, Dept. of Oral and Maxillofacial Radiology, School of Dentistry, Shahid Beheshti University of Medical Sciences, Tehran, Iran.

Correspondence to Mina Iranparvar Alamdari (email: mina.iranparvar@sbm.ac.ir).

(Submitted: 26 October 2022 – Revised version received: 12 November 2022 – Accepted: 22 November 2022 – Published online: Winter 2023)

**Objectives** Hemangiolympangiomas (HLAs) are rare vascular malformations of lymphatic and blood vessels. These lesions commonly occur in the head and neck regions. In this paper, we describe a rare case of HLA, with significant effects on the mandibular bone and neurovascular canals.

**Case** A 28-year-old patient with a history of head and neck HLA was referred to an oral and maxillofacial surgeon for dental implant placement. The results of radiographic analysis and cone-beam computed tomography (CBCT) indicated the mandibular bone enlargement, sclerosis, and bone remodeling. The inferior alveolar nerve canal (IANC) and mental foramen were markedly enlarged on both sides. Additionally, multiple soft tissue calcifications were present. The patient was referred to the oral and maxillofacial surgery (OMFS) department for further dental treatment.

**Conclusion** Patients with maxillofacial vascular malformations require careful radiographic and imaging assessments before any surgical intervention, especially implant placement. Enlargement of neurovascular canals, especially IAN and mental foramen, along with the presence of sclerotic bone, should be considered as important findings, as they may significantly influence the surgical outcomes.

**Keywords** Vascular malformation; Hemangioma; Lymphangioma; Maxillofacial; Cone-beam computed tomography; Mental foramen

## Introduction

Vascular anomalies can be classified into two main categories of vascular tumors and vascular malformations.

<sup>1</sup> According to the International Society for the Study of Vascular Anomalies (ISSVA), vascular malformations are subdivided into the following categories: simple, combined, malformations of “major named vessels”, and malformations associated with other anomalies. <sup>2</sup> Hemangioma is identified as the most common benign vascular tumor. Hemangiolympangiomas (HLAs) are rare vascular malformations of lymphatic and blood vessels. These lesions are commonly diagnosed in the first two years of life. They may occur in various anatomical regions, including the colon, duodenum, vertebrae, and oral and maxillofacial regions, although the neck is the most common site for these malformations.

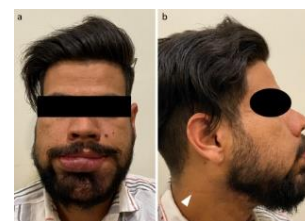In the maxillofacial region, HLAs may involve both hard and soft tissues. The soft tissue may be swollen, throbbing, or discolored to red or bluish red. Besides, calcifications, such as phleboliths, may be present throughout the enlarged soft tissue. <sup>3</sup> The imaging modality of choice for the diagnosis of HLA is contrast-enhanced multidetector computed tomography (MDCT) or conventional/magnetic resonance (MR) angiography, which can aid in differentiating vascular lesions from other jaw neoplasms. When lesions are superficial, localized, and small, complete surgical excision is the only necessary treatment. <sup>4</sup> Deeper or larger lesions may require sclerotherapy, vessel ligation, and embolization before any surgical excision. <sup>5</sup>

In this report, we present the case of a patient diagnosed

with maxillofacial HLA and describe the rare radiographic findings and imaging characteristics of this disorder in the mandibular neurovascular canals and oral region.

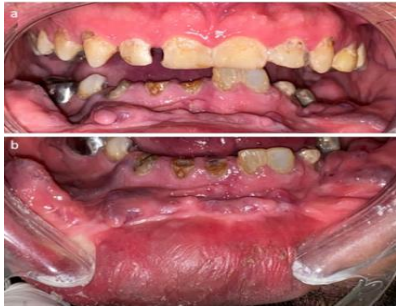## Case Report

A 28-year-old male patient was referred to the oral and maxillofacial radiology department for pre-implantation radiographic evaluations. He had a history of recurrent lesions in the left submandibular and right cervical regions, underwent biopsy, and was diagnosed with HLA histopathologically. He reported no related symptoms. His medical history was not significant, and no history of trauma was reported. His family history was also unremarkable. An extraoral examination demonstrated the enlargement of facial soft tissues, especially in the lower third of the face. The nasolabial fold was obliterated on the right side, with elevation of the nasal alae (Figures 1a-1b). Additionally, an intraoral examination revealed the patient's poor oral hygiene and the presence of multiple exophytic sessile masses in the buccal and labial mucosa, with pink to bluish color (Figures 2a-2b).



**Figure 1:** Extraoral photographs: (a) Frontal view and (b) profile view indicating the enlargement of the lower face and lip, obliteration of the nasolabial fold, and elevation of the nasal alae. The lower lip had a slightly bluish-red color. A surgical

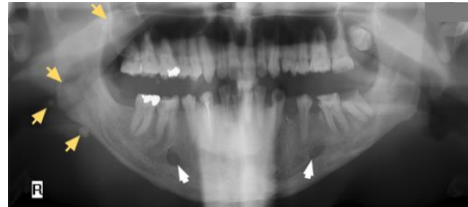
scar on the right side of the neck (white arrowhead) related to a previous surgery could be observed.



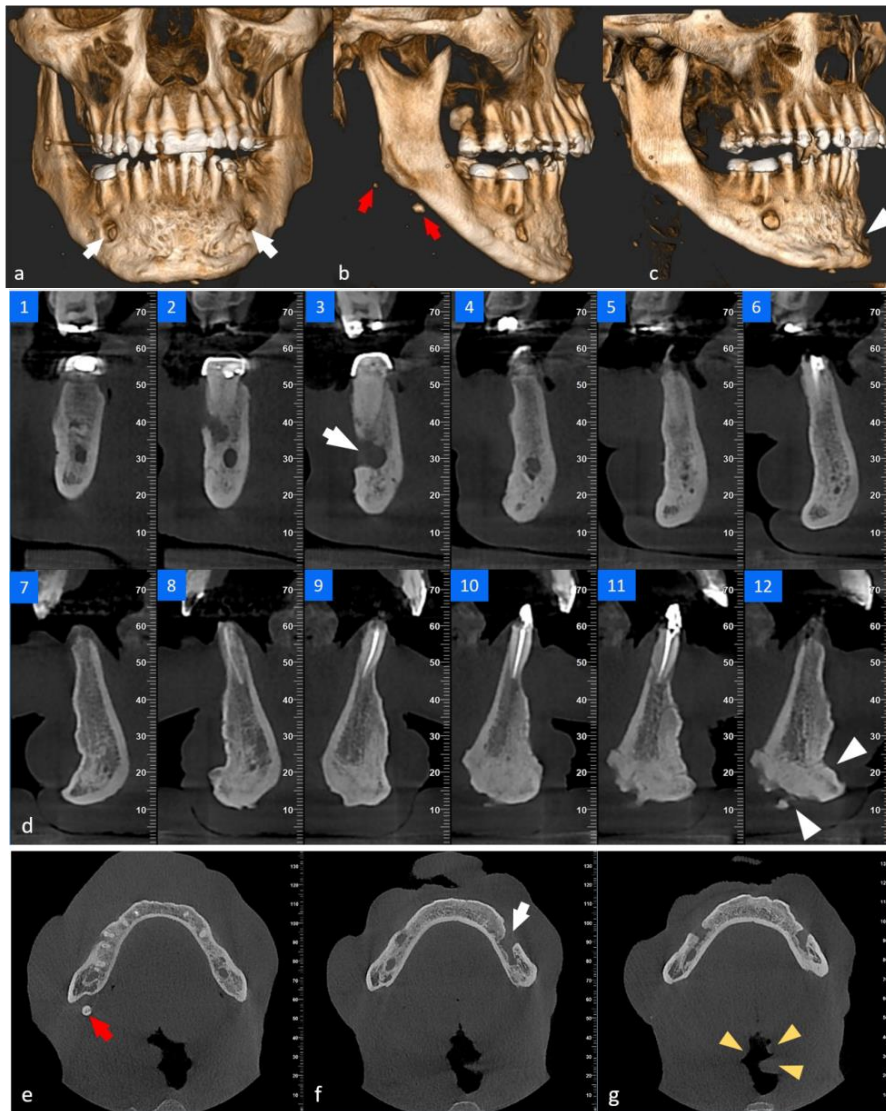
**Figure 2:** Intraoral photographs indicating exophytic masses with a pink to bluish color: (a) Centric occlusion view and (b) cropped mandibular occlusal view. Severe carious lesions could be observed due to poor oral hygiene.

The prominent findings of panoramic radiograph, acquired in the last year, were enlarged mental foramina and multiple small radiopacities near the right mandibular angle and the antegonial notch (Figure 3). To assess the

quantity and quality of the mandibular bone for dental implant placement, cone-beam computed tomography (CBCT) scan (Newtom VGi, Verona, Italy) was performed (FOV, 15×12 cm; 110 kV; 7.10 mAs). Reconstructions were performed in NNT Viewer Version 8.0, and axial, cross-sectional, and 3D views were inspected (Figures 4a-4g).



**Figure 3:** Panoramic radiograph indicating enlarged mental foramina (white arrows) and multiple small radiopacities near the right mandibular angle, near the antegonial notch, and at the level of the coronoid process (yellow arrows). The anterior mandibular bone was moderately enlarged.



**Figure 4:** Reconstructed 3D CBCT images: (a-c) Cross-sectional views and (d) axial reconstructions (e-g), demonstrating enlarged mental foramina (white arrows), soft tissue calcifications (red arrows), airway stenosis (yellow arrowheads), and irregular remodeling of labial and inferior cortices (white arrowheads). A steep mandibular angle could be observed in 3D reconstructions (b).

Soft tissue calcifications had a target-like appearance, most compatible with phleboliths. Soft tissue enlargement and airway stenosis were also detected in axial views. Mandibular enlargement, cortical thickening and sclerosis, and irregular remodeling of labial and inferior cortices (causing surface deformities) were observed in the anterior mandible. A steep mandibular angle and large mental foramina were clearly detected. The diameter of the mental foramina, measured in the cross-sectional and axial sections, was 12.4 mm on the left side and 10.0 mm on the right side. After analyzing the imaging features, the patient was referred to an oral and maxillofacial surgeon for mandibular implant placement and rehabilitation.

## Discussion

HLAs are a combination of hemangioma and lymphangioma, involving benign proliferation of blood vessels and lymphatic vessels. These lesions are benign in nature. Various studies have reported the presence of HLA in the oral cavity and maxillofacial region.<sup>6-8</sup> In this paper, we described the case of a young adult patient having HLA in the maxillofacial and neck regions, with significant effects on both soft and hard tissues. He required dental implant placement in the mandible due to multiple carious teeth with a poor prognosis. To evaluate the quality and quantity of the periodontal compartment, CBCT is highly recommended.

In this regard, Yarmand et al. diagnosed HLA in the buccal mucosa of a 26-year-old patient. The patient complained of swelling, and a sessile reddish-blue lesion was detected in the buccal mucosa. However, the lesion was localized, with no effects on the surrounding structures; it was subsequently resected via surgical excisional biopsy.<sup>9</sup> Moreover, in a study by Deliverska et al., a rare case of HLA was reported in the mandibular bone. The lesion was radiolucent and had no effects on teeth or cortical bone.<sup>10</sup>

In the present study, enlargement of IANC and mental foramen was clearly detected on both sides. A study by Von Arx et al. reported that the average diameter of the mental foramen was approximately 1.8 mm to 5.5 mm.<sup>11</sup> In another study on dried adult human mandibles, Singh et al. showed that the size of the mental foramen ranged

from 1 mm to 5 mm on the right side (average, 2.79 mm) and from 1 mm to 6 mm (average, 2.57 mm) on the left side.<sup>12</sup> However, the diameter of the mental foramina in our patient was larger than 1 cm (12.4 mm on the left side and 10.0 on the right side) in the cross-sectional and axial views.

Various studies have described neurovascular disorders as complications of implant placement into the mental foramen or IANC invasion.<sup>13</sup> Practitioners should be familiar with neurovascular canal variations to avoid injury to these anatomical structures.<sup>14</sup> In our case, mandibular enlargement, sclerosis, and bone remodeling were markedly observed. Kakimoto et al. reported bone resorption near the soft tissue, associated with vascular lesions.<sup>15</sup> Soft tissue enlargements in the oral cavity and pharynx resulted in airway constriction. Lincoln et al. reported a case of vascular anomalies, compressing the esophagus and trachea.<sup>16</sup> Overall, severe respiratory constriction and obstruction due to soft tissue enlargement should be addressed carefully.

## Conclusion

Patients with maxillofacial vascular malformations, such as hemangioma and HLA, need careful radiographic and imaging assessments before any surgical treatment, especially implant placement. Enlargement of neurovascular canals, especially IAN and mental foramen, along with the presence of sclerotic bone, should be considered as important findings, as they may significantly influence the surgical outcomes.

### *Ethical Approval*

The requirement to obtain ethical approval was waived, as no experiments were performed in this study.

### *Consent*

Written informed consent was obtained from the patient to publish this report in accordance with the journal's patient consent policy.

## Conflict of Interest

No Conflict of Interest Declared ■

## References

- Carqueja IM, Sousa J, Mansilha A. Vascular malformations: classification, diagnosis and treatment. *Int Angiol.* 2018; 37(2):127-42.
- Blei F, Nomenclature of vascular anomalies: Evolution to the ISSVA 2018 classification system. *Vascular Anomalies.* 2020; Springer:1-8.
- Mallya S, Ernest Lam. *White and Pharoah's Oral Radiology E-Book: Principles and Interpretation.* 8<sup>th</sup> Ed. Elsevier Health Sciences. 2018; Chap 24: 452-7.
- Lisboa ML, Zimmermman C, Chrun ED, Rath IB, Santos AM, Grando LJ. Clinical Success with Conservative Treatment for Hemangiolympangioma on the Tongue. *Oral Surg Oral Med Oral Pathol Oral Radiol.* 2018; 1;126(3):e98.
- Mungia AM. Pattern of occurrence, clinical presentation and management of oral and maxillofacial vascular lesions at muhimbili national hospital. *Mdent (Oral and Maxillofacial Surgery) Dissertation* 2019; Available At: <http://dspace.muhas.ac.tz:8080/xmlui/handle/123456789/2501>.
- Manickam S, Sasikumar P, Kishore BN, Joy ST.

Hemangiolympangioma of buccal mucosa: a rare case report. *J Oral Maxillofac Pathol.* 2017;21(2):282-285.

7. Ribeiro GA, Dias AM, Leite AF, Buexm LA, Lima GS, Alves AT, et al. Oral Hemangiolympangioma: a Case Report. *Oral Surg Oral Med Oral Pathol Oral Radiol.* 2018;126(3):e71.

8. Sobhana CR, Beena VT, Soni A, Choudhary K, Sapru D. Hemangiolympangioma of buccal mucosa: report of a rare case and review of literature on treatment aspect. *Natl J Maxillofac Surg.* 2012;3(2):190-4.

9. Yarmand F, Seyyedmajidi M, Shirzad A, Foroughi R, Bakhshian AA. Lymphangiohemangioma of buccal mucosa: Report of a rare case. *J Oral Maxillofac Surg Med Pathol.* 2016;28(4):358-61.

10. Deliverska E. Hemangiolympangioma of the mandible: case report. *J of IMAB.* 2019;25(4):2729-32.

11. Von Arx T, Friedli M, Sendi P, Lozanoff S, Bornstein MM. Location and dimensions of the mental foramen: a radiographic analysis by using cone-beam computed

tomography. *J Endod.* 2013; 39(12): 1522-8.

12. Singh R, Srivastav AK. Study of position, shape, size and incidence of mental foramen and accessory mental foramen in indian adult human skulls. *Int J Morphol.* 2010;28(4):1141-6.

13. Jacobs R, Quirynen M, Bornstein MM. Neurovascular disturbances after implant surgery. *Periodontol* 2000. 2014;66(1):188-202.

14. Alhassani AA, AlGhamdi AS. Inferior alveolar nerve injury in implant dentistry: diagnosis, causes, prevention, and management. *J Oral Implantol.* 2010;36(5):401-7.

15. Kakimoto N, Tanimoto K, Nishiyama H, Murakami S, Furukawa S, Kreiborg S. CT and MR imaging features of oral and maxillofacial hemangioma and vascular malformation. *Eur J Radio.* 2005;55(1):108-12.

16. Lincoln JC, Deverall PB, Stark J, Aberdeen E, Waterston DJ. Vascular anomalies compressing the oesophagus and trachea. *Thorax.* 1969;24(3):295-306.

---

**How to cite:**

Ghazizadeh Ahsaie M, Iranparvar Alamdari M, Mohammadpour M. Extremely large Mental foramina in a Rare Case of Oral Hemangiolympangioma. *J Dent Sch* 2022;40(1):39-42