

Rhinolith: An Incidental Finding in a Patient Under Orthodontic Treatment

Amirali Momeni^a, Mahkameh Moshfeghi¹ , Maryam Alizad-Rahvar¹ 

^aDentist, Dept. of Oral and Maxillofacial Radiology, School of Dentistry, Shahid Beheshti University of Medical Sciences, Tehran, Iran.

^bAssociate Professor, Dept. of Oral and Maxillofacial Radiology, School of Dentistry, Shahid Beheshti University of Medical Sciences, Tehran, Iran.

^cAssistant Professor, Razi Herbal Medicines Research Center, Dept. Oral and Maxillofacial Radiology, School of Dentistry, Lorestan University of Medical Sciences, Khorramabad, Iran.

Correspondence to Maryam Alizad-Rahvar (email:alizardmaryam@gmail.com).

(Submitted: 6 November 2022 – Revised version received: 14 November 2022 – Accepted: 19 November 2022 – Published online: Autumn 2022)

Objectives Rhinolith is an uncommon condition that results from calcification of an endogenous or exogenous nidus within the nasal cavity. It may present asymptotically or cause symptoms like headache and nasal obstruction.

Case: In this case report, we present a case of an unusual and quite big rhinolith in a 17-year-old male which was undetected for some time, and was accidentally found in the radiographic examination. It possibly originated from a retained foreign body in childhood. We discuss its clinical and radiographic features and its effect on the surrounding structures.

Conclusion Radiographic assessment and rigid endoscopy are important to evaluate the rhinolith's location.

Keywords Nose Calculi; Incidental Findings; Orthodontics

Introduction

Rhinolith is a mass resulting from the accumulation of inorganic materials such as calcium, magnesium, iron, and phosphorus salt, or organic substances such as glutamic acid and glycine, leading to the slow and progressive increase in size around an endogenous or exogenous nidus depending upon the nucleus on which the encrustation occurs within the nasal cavity.¹⁻³ It usually occurs secondary to a foreign body stuck in the nasal cavity.

The etiology of rhinolith is not always clear, and it may be exogenous (e.g., cotton, beads, fruit, stones, plastic parts, etc.), or endogenous, resulting in encrustation occurring around normal or abnormal tissues such as tooth sequestra or blood clots, dry secretions, cell lysis products, or necrotic mucosa, which serve as a foreign body.⁴

Rhinolith can remain undetected for many years, and it is often an asymptomatic condition, especially for the foreign bodies which access the site anteriorly, but when they reach the nasal cavity through the posterior choanae or a subsequent increase occurs in their size, they cause symptoms such as a nasal block, discharge, cough, or vomiting.⁵

The symptoms that strongly indicate the diagnosis of rhinolith are normally progressive unilateral nasal obstruction, foul smelling, nasal discharge, rhinorrhea, and cacosmia. If the lesion is expanding, the pressure effect may cause pain and epistaxis.⁶

Due to similar symptoms, rhinolith can be easily misdiagnosed as chronic sinusitis.³ Herein, we present a case of gross rhinolith likely arising from a retained foreign body.

Case Report

A 17-year-old male was referred to the Department of Oral and Maxillofacial Radiology to undergo cone-beam computed tomography (CBCT) as part of orthodontic treatment. The patient was not on any specific medication other than over-the-counter drugs, and he did not report any known allergies. A general physical examination was performed, and the results were observed to be within the normal limits. The patient's medical, family or psychosocial history was unremarkable.

He did not recall any history of insertion of a foreign body into the nasal fossa, only reporting a fall flat on his face five years ago.

The scans were obtained with the New Tom VGI CBCT scanner (Quantitative radiology, Verona, Italy) with exposure settings of 110 kVp and 10 mA.

The scans revealed a large, ill-defined, irregular, hyperdense mass with a well-defined and round radiolucent entity at the center (nidus) in the right anterior nasal fossa. The completely regular, round radiolucent entity with narrow central radiopacity suggested a nucleus like a bead or a button with a central hole that was entrapped and calcified (Figure 1).

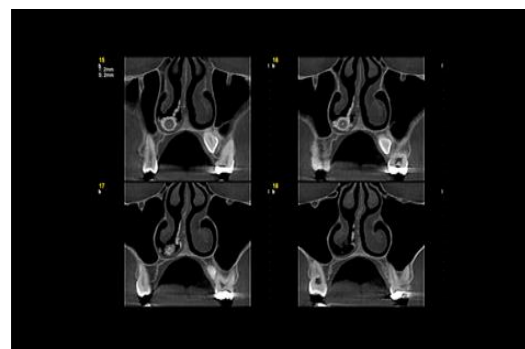


Figure 1. Coronal CBCT view. Large, ill-defined, irregular, hyperdense mass with a well-defined, and round radiolucent entity at the center (nidus) in the right anterior nasal fossa. A completely regular, round radiolucent entity with narrow central radiopacity (cut no.16) suggested a

nucleus like a bead or a button with a central hole that was entrapped and calcified.

The mass measured approximately 12 mm (width) × 8 mm (height) on the coronal view and 15 mm (width) × 8 mm (height) on the axial view in its greatest dimensions. On the coronal view, the mass was located on the floor of the nasal cavity right below the inferior turbinate and caused a thickening of the nasal mucous membrane in this region. The calcification extended to the middle of the nasal septum with no bone erosion. Obvious atrophy of the osseous and mucosal tissue of the inferior turbinate was visible. The level of the inferior turbinate from the lateral nasal wall and the height and width of the infundibulum had not been affected. The sinuses were free from any pathology (Figure 1). On the axial view, mucosal thickening of the anterior, lateral, and medial walls of the nasal fossa was seen (Figure 2).

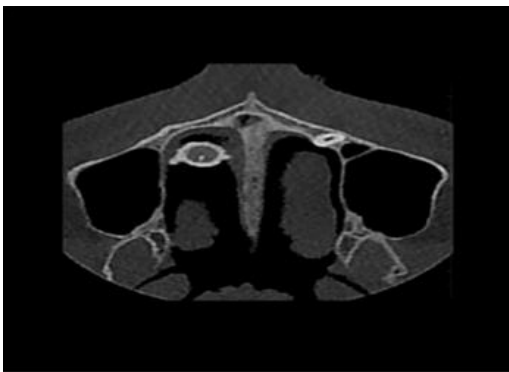

Figure 2. On this axial CBCT view, mucosal thickening of the anterior, lateral, and medial walls of the nasal fossa with central calcification of nidus and atrophic right inferior turbinate can be seen.

Based on radiographic findings, a diagnosis of benign soft tissue calcification (rhinolith) was made and an endoscopic-assisted removal was proposed.

After the evaluation of CBCT images, we talked with the patient. He admitted frequent right-sided nose blockage and difficulty in breathing. On clinical examination, without an endoscope, no mass was seen over the right nostril.

Discussion

Calcareous concretions that occur in the nose (rhinolith) arise from the slow accretion of nasal, lacrimal, and inflammatory mineral salts such as calcium phosphate, calcium carbonate, and magnesium around a nidus, and approximately take several years to form.⁷ The incidence of rhinolith is 1 in 10,000 outpatient visits.⁸ The first case of rhinolith in the literature was reported by Bartholin in 1654⁹; since then, approximately more than 800 cases have been reported.¹⁰

Its prevalence is lower in developed countries and commonly affects young adults, but it can be seen at all ages.⁹

Most patients complain of unilateral nasal discharge, nasal pain, blocked nose, halitosis, epistaxis, nasal or facial swelling, and pain, or sinusitis. Vasegh et al.¹¹ reported a rare case of large rhinolith with facial and periorbital pain, headache, upper jaw pain, nasal discharge, epistaxis, and fetid odor sensation. In rare cases, symptoms or signs of involvement or erosion of the adjacent structures, such as epiphora or oronasal fistula can occur.¹²

In some patients, rhinolith may remain asymptomatic or with only subtle signs for a long time and is found incidentally during routine ENT examinations, sinonasal CT scans, or dental radiographic examinations.¹³

In clinical examination, they have a very hard appearance (hard and stony consistency) with a crackling sensation during exploration.¹⁰ In some cases, rhinolith may affect the sinonasal cavity, which may also require treatment.¹⁴ Chatziavramidis et al.¹⁵ reported a longstanding rhinolith that led to anatomical alterations of the ipsilateral inferior nasal meatus and turbinate. Yildiz et al.¹⁶ showed that 50% of patients with rhinolith had septum and inferior turbinate destruction.

Diagnosis is usually based on a history of a foreign body inserted into the nose, physical examination, nasoendoscopy and radiographic evaluation. Rhinoscopy and endoscopic nasal examinations show a yellow-gray spiculated mass with variable size and shape at the interseptum turbinal space surrounded by granulation and inflammatory tissue. septal perforation, synechia, granuloma, and reaction polyp can be evaluated by endoscopy.¹⁰

Conventional X-ray and paranasal sinus CT or CBCT scans support the diagnosis by revealing the presence of a calcified mass in the nasal fossa. Such imaging modalities can also show small calcification deposits and possible changes in the adjacent structures and help design better treatment plans and surgical approaches.¹⁵

In many cases, the patient is not aware of the presence of rhinolith, and diagnosis is made incidentally through routine clinical examinations or by imaging performed for other reasons, such as orthodontic treatment in our case.¹⁷

The differential interpretation includes osteoma, calcified polyp, odontoma, and surgical ciliated cyst.¹⁸ Considering the radiographic features and typical calcification with radiolucent nidus, in the present case, rhinolith was our first differential diagnosis.

Patients should be referred to an otorhinolaryngologist for endonasal endoscopic surgical removal of such calcifications. In cases of giant rhinoliths, lithotripsy has been used to debulk them; external approaches may also be necessary.¹⁹ Recurrence after removal has never been reported.⁴

The main limitation of our diagnostic process was that the patient refused the next step of ENT consultation and surgical evaluation.

Ethics of case report

We obtained written informed consent from the patient and his parents for this case report, and also obtained approval

from the ethics committee of our institution.

important to evaluate the rhinolith's location.

Conclusion

Radiographic assessment and rigid endoscopy are

Conflict of Interest

No Conflict of Interest Declared ■

References

- Mohiyuddin A. Giant 'staghorn' rhinolith in a 15-year-old girl. *BMJ Case Rep* 2018; 11(1):e227587.
- Hsiao JC, Tai CF, Lee KW, Ho KY, Kou WR, Wang LF. Giant rhinolith: a case report. *Kaohsiung J Med Sci*. 2005;21(12):582-5.
- Shah FA, George S, Reghunandan N. A Case presentation of a large rhinolith. *Oman Med J*. 2010;25(3):230-1.
- CKL Shaw. Rhinolith of endogenous origin: A rare entity. *Surg Pract* 2007;11(1):48-50.
- Aljfout Q, Saraireh M, Maita A. Rhinolith misdiagnosed as allergic rhinitis: case report. *Electron Physician*. 2016;8(2):1880-3.
- Dib GC, Tangerina RP, Abreu CE, Santos Rde P, Gregório LC. Rhinolithiasis as cause of oronasal fistula. *Braz J Otolaryngol*. 2005;71(1):101-3.
- Noh KB, Sachlin IS, Gazali N, Md Shukri N. Giant rhinolith: A case report. *gypt J Ear Nose Throat Allied Sci* .2016;18(2):155-7.
- Smith M, Wong E, Ahmadi N, Singh NP. A nose out of joint: first reported case of prison-acquired marijuana-based rhinolith. *BMJ Case Rep*. 2019;12(10):e231989.
- Eliachar I, Schalit M. Rhinolithiasis. Report of eight cases. *Arch Otolaryngol*. 1970;91(1):88-90.
- Lahma J, Hejjouji R, Azzam I, Oujilal A, Essakalli L. Rhinolithiasis: about an observation of a rare condition. *Pan Afr Med J*. 2018;31:78.
- Vasegh Z, Ghazizadeh Ahsaie M. Large Rhinolith Mimicking Atypical Odontogenic Pain: Case Report and Brief Review of the Literature. *Case Rep Dent*. 2021;2021:5550187.
- Aljfout Q, Saraireh M, Maita A. Rhinolith misdiagnosed as allergic rhinitis: case report. *Electron Physician*. 2016;8(2):1880-3.
- Çakabay T, Üstün Bezin S, Tarakçioğlu MC, Koçyiğit M, Serin Keskinçe B, Giran Örtekin S. Rhinolithiasis: Mineralogical, chemical composition, clinical and radiological features of rhinoliths. *Tr-ENT* 2019;29(1):52-9.
- Hadi U, Ghossaini S, Zaytoun G. Rhinolithiasis: a forgotten entity. *Otolaryngol Head Neck Surg*. 2002;126(1):48-51.
- Chatziavramidis A, Kondylidou-Sidira A, Stefanidis A, Soldatou S. Longstanding rhinolith leading to anatomical alterations of the ipsilateral inferior nasal meatus and turbinate. *BMJ Case Rep*. 2010;2010:bcr0720103155
- Yildiz E, Kuzu S, Ulu Ş, Kahveci OK, Günebakan Ç, Bucak A.. Rhinoliths: Analysis of 24 Interesting Forgotten Foreign Body Cases. *Ear Nose Throat J*. 2021;100(8):570-3 .
- Moshfeghi M, Abedian B, Ahsaie MG, Tajdini F. Prevalence of nasal septum deviation using cone-beam computed tomography: A cross-sectional study. *Ontemp Clin Dent*. 2020;11(3):223-8.
- Prinja S, Davessar J, Singh G, Jindal S, Bali A. Bilateral concha bullosa with right sided extensive rhinolith: a case report. *Int J Otorhinolaryngol Head Neck Surg* 2019;5:1122-5.
- Heffler E, Machetta G, Magnano M. When perennial rhinitis worsens: rhinolith mimicking severe allergic rhinitis. *BMJ Case Rep*. 2014;2014:bcr2013202539.

How to cite: Momeni A, Moshfeghi M, Alizad-Rahvar M. Rhinolith: An Incidental Finding in a Patient Under Orthodontic Treatment. *J Dent Sch* 2021;39(4):146-148.