

Identification of Appropriate Probe Site in Maxillary Anterior Teeth for Electric Pulp Testing

Ali Dehghan Dehnavi ^a, Elahe Salarpour ^b, Mohammad Salarpour ^c

^aDentist, Yazd, Iran.

^bPostgraduate Student, Dept. of Orthodontics, Faculty of Dentistry, Shahid Sadoughi University of Medical Science, Yazd, Iran.

^cAssistant Professor, Dept. of Endodontic, Faculty of Dentistry, Zahedan University of Medical science, Zahedan, Iran.

Correspondence to Mohammad Salarpour (email: Dr.elahe.salarpour@gmail.com).

(Submitted: 26 June 2022 – Revised version received: 01 October 2022 – Accepted: 04 October 2022 – Published online: Autumn 2022)

Objectives This study aimed to find the appropriate probe site for electric pulp testing (EPT) in maxillary anterior teeth.

Methods Forty patients with available panoramic radiographs referred to the Endodontics Department were studied. In each patient, three intact teeth, including central incisor, lateral incisor, and canine, were selected from one quadrant of the maxillary arch. The incisal third, middle third, and cervical third of the buccal surface of the teeth were assessed. The respective teeth were isolated with rubber dam without a clamp. EPT was conducted starting with the lowest intensity, which gradually increased until the patient reported a sense of tingling, stinging, or heat. This process was repeated for all respective teeth at the three areas. Data were analyzed by the Friedman test ($P < 0.05$), ANOVA ($P < 0.001$), and Man-Whitney test ($P > 0.05$).

Results The middle third of all three maxillary anterior teeth was an appropriate site for EPT. The lateral incisor had the lowest threshold response in all three areas compared with other teeth. No significant difference was observed between male and female patients ($P > 0.05$).

Conclusion Within the limitations of this study, it may be concluded that the middle third of the buccal surface of maxillary anterior teeth is an optimal electrode placement site.

Keywords Diagnosis; Dental Pulp Test; Maxilla

Introduction

Successful endodontic treatment begins with an accurate diagnosis which is the backbone for an effectual treatment plan.¹ Precise assessment of the health status of dental pulp can be done thorough clinical and radiographic examination, and the use of special diagnostic tests.² An ideal pulp test should be simple, affordable, accurate, standardized, and objective for assessment of pulp vitality.³ Pulp tests are divided into two groups: Pulp vitality tests and pulp sensibility tests. Pulp vitality tests include laser Doppler flowmetry and pulse oximetry, that can estimate the blood flow within the pulp. Pulp sensibility tests aim to assess the neural status within the pulp, and include the thermal, electric and cavity tests.⁴ In other words, electric pulp testing (EPT) only provides information about the nerve supply of the pulp, not the vascular supply, which is the true determinant of vitality.⁵ EPT is based on stimulating the pulp sensory nerves, which requires a subjective assessment by patient.³ The response to this test is expressed in numerical values, which allows comparison between readings.⁴

Electrical stimulation induced by EPT is a low-intensity controlled stimulus such that it can only stimulate the myelinated A-delta fibers and cause a non-painful sensation called pre-pain.⁶ The electrical current generated by EPT usually does not excite the non-myelinated C-fibers due to a higher threshold.¹ EPT requires and relies on subjective assessment and feedback from the patient.¹ These can lead to false-positive and false-negative results. Nevertheless, EPT remains a critical aid, and when properly used, it is a safe clinical test that can provide helpful information regarding pulpal health or disease status.⁷⁻⁹

Several clinical considerations regarding pulp sensibility testing with EPT include isolation of the tooth, thickness of enamel and dentin, and site of placement of the tip of the probe.¹⁰ Ideally, the probe tip (electrode) should be placed over an area to overcome enamel and dentin resistance, and stimulate the myelinated sensory fibers, so the sensation would be the greatest where the density of neural distribution is the highest.³ This area has been mentioned in papers with titles such as appropriate site (optional location - perfect site).

To facilitate the response, the probe should be placed at a point on the flat surface of the crown to establish maximum contact between the probe and the tooth. Incorrect probe location may lead to a false-negative response in the vital tooth.³ Since EPT entered the field of endodontics as a diagnostic tool, probe placement has been a significant source of challenge, and such contradictions have not yet been solved.

Turedi et al. examined the correct probe tip placement site in developing incisors in 273 patients between 6-12 years. They used Digitest II pulp vitality tester along with toothpaste as the conducting medium to determine sensibility at three different sites (incisal, middle, and cervical thirds). They showed that the lowest EPT values were obtained at the incisal third, and mandibular incisors had lower mean response thresholds than their maxillary counterparts.¹¹ Jacklin et al. conducted a study on 20 dental students at Otaga University to find the most suitable probe site. This examination was performed at seven points on the buccal surface of the first molar teeth in both arches. The results showed that the lowest response threshold was obtained from the mesiobuccal cusp tip in the maxilla and mandible, and there was no significant difference between

males and females.¹² Udoeye et al. assessed the optimal probe site. This study was done on three anterior maxillary and mandibular teeth in black patients aged 18 to 71 years. They concluded that the appropriate area is the incisal edge, and the cervical third had the upper limit response threshold. In other words, as the electrode moved from the incisal edge to the cervical third, they needed to increase the intensity of the electric current to achieve a response. In both jaws, the response threshold was lower in women than men, and in all areas, the threshold was lower in the mandible than in the maxilla.¹³ Ingle et al. proposed that multi-rooted teeth may need to be tested by placing the probe tip on more than one site, because two sites on a molar may not give a response, but a response may be obtained in another area.¹⁴

Due to the widespread use of EPT among the available pulpal tests, it is important to know the proper site for probe placement. The objective of this study was to determine the optimal probe placement site and compare the effect of changing the probe's position on the response of maxillary anterior teeth.

Methods and Materials

This study was approved by the ethics committee and the research vice chancellor of Zahedan University of Medical Sciences (ethical code: IR.ZAUMS.REC.1392.900).

During one month, 40 dental patients (24 males and 16 females) aged 20-25 years (with a mean age of 22.5 ± 1.83 years) were recruited from the Endodontics Department of Zahedan Dental School. Participants signed informed consent forms before the study. Each patient had to have a panoramic radiograph visualizing intact anterior maxillary teeth (central incisor, lateral incisor and canine) at least in one side of the arch. Other inclusion criteria were no history of trauma and orthodontic treatment in the past 9 months, and no intake of narcotics, sedatives, or alcoholic drinks in the past 24 hours. The tooth to be tested was isolated with a rubber dam without a clamp. EPT was conducted according to the manufacturer's instructions with a digital electric pulp tester (Parkell, Farmingdale, NY, USA) which was a monopolar pulp tester with an anodal electrode probe tip with 2 mm² diameter. The circuit was completed when the subject rested a finger on the lip clip of the pulp tester. The tip of the electrode was lightly coated with toothpaste (Pooneh, Iran) as a conducting medium (to establish maximum contact between the tooth surface and the electrode and for easy and maximum current transmission); a gentle pulsed stimulus was applied, and it increased gradually until the patient reported a sense of tingling, stinging, warmth or heat. As mentioned earlier, the patients were instructed to release the clip on the first sense. At this time, the digital display readout of the pulp tester was defined as the threshold.

A new pair of gloves was used for each patient, and the electrode tip was disinfected with Microzed (Surface Solution 750cc; Atrine saziba, Iran). After completing the test for each tooth, the device was turned off and turned on again to test the next tooth. Three sites on the buccal surface of each anterior tooth were selected for testing: incisal third, middle third, and cervical third. The test was started with the incisal third of the central incisor and then continued in the same region of lateral incisor and canine. The test was similarly done in the middle and cervical thirds. Between the tests, the teeth were air-dried, and a recovery period of at least one minute was allowed to prevent the nerve accommodation phenomenon as described by Cooley and Robinson⁽¹⁰⁾. The threshold values were recorded in a form.

After data collection, statistical analysis was conducted using PASW® version 15 (SPSS, Chicago, IL). The Friedman test was used to compare the mean response to EPT of each tooth at the incisal, middle and cervical thirds ($P < 0.05$), ANOVA was used to compare the mean response of three types of teeth (central incisor, lateral incisor, and canine) ($P < 0.001$) and the Man-Whitney test was used to compare the mean response to EPT in males and females ($P > 0.05$).

Results

Out of 40 participants, 24 were females (60%) and 16 were males (40%) with a mean age of 22.5 years (range 20-25 years).

Multiple comparisons revealed a significant difference among the incisal, middle, and cervical thirds such that the lowest threshold values were recorded in the buccal middle third, and the highest values were seen in the buccal cervical third ($P < 0.05$). The lateral incisor had the lowest threshold, and the canine had the highest threshold in all three areas ($P < 0.001$, Figure 1). There was no significant difference between males and females in level of responses observed in the three tested areas of each tooth ($P > 0.05$, Figure 2).

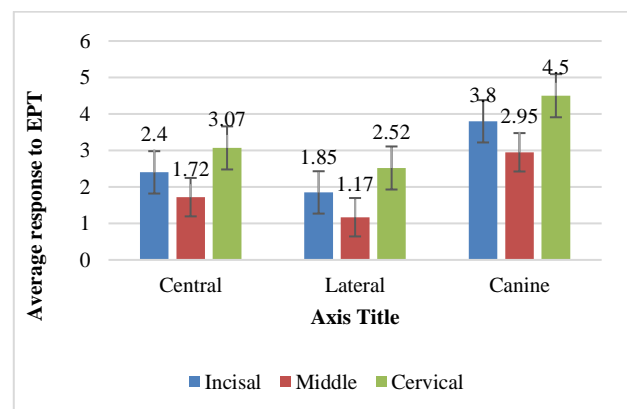


Figure 1. Comparison of electric pulp test (EPT) response by tooth type and electrode location

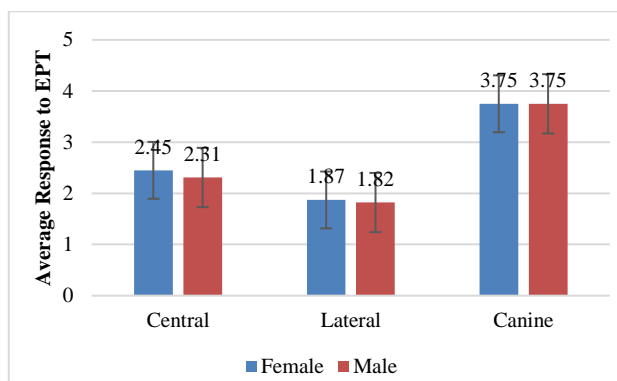


Figure 2. Comparison of electric pulp test (EPT) response by tooth type and gender

Discussion

The optimal area or proper probe placement site during EPT has always been a source of controversy. The electrode should be placed on the crown, where the pulpal nerves are stimulated earlier and quicker by the lowest threshold. At least in the anterior teeth, the palatal surface is not a suitable area to place the electrode, due to the special anatomy that causes difficulty in establishing a good electrode-to-tooth contact; this issue has led to selection of the facial surface to place the probe.¹⁵

This study aimed to determine the appropriate location of the probe in the anterior maxillary teeth. This study differed from other studies in terms of age range of patients and sample size. Contrary to several studies, we limited the age range of patients and selected only patients aged 20-25 years.^{16, 17} The rationality behind this was to eliminate two important confounding factors namely occlusal wear and dentin deposition. Secondary dentin deposition due to aging can reduce the pulp chamber size, bury nerve fibers, and increase the distance from the electrode tip to the pulp. According to Bender et al, the aging phenomenon reduces both size of the pulp chamber and number of nerve fibers; also, they reported that worn teeth had a lower threshold response⁽¹⁷⁾.

The areas assessed in the study by Udoye et al. included the incisal edge, incisal third, middle third, and cervical third in the facial surface, and Jacobson included nine facial surface areas.^{13, 15} In EPT studies, areas selected for the probe should be easily accessible, flat, and free of physical and anatomical barriers, providing the possibility of electrode stability. Thus, selection of incisal edge or palatal surface in the anterior teeth and central fossa in posterior teeth is not justified.

In the present study, we selected the incisal third, middle third, and cervical third of the facial surface to eliminate physical, anatomical, and access restrictions as much as possible. The results showed that the response threshold in the lateral incisor was much lower than other anterior teeth (faster response to lower electric current). The mean response to EPT was 1.85 for the lateral incisor, 2.4 for the

central incisor, and 3.7 for the canine tooth. It may be stated that the present results were in line with the findings of Lin et al, showing that the further we go from the front to the back of the mouth, the more significant the response threshold would be.¹²

As reported by Narhi et al, the EPT response is also affected by the thickness of dentin and enamel.¹⁸ In the present study, the lowest threshold was observed in lateral incisor and the highest in canine tooth. The lateral incisor has lower dentin and enamel thickness than the canine tooth. Thus, the present findings confirmed the hypothesis by Narhi et al, that teeth with thinner dentin and enamel have a lower threshold response.

The present results showed that in maxillary anterior teeth, three tested areas had a significant difference in the mean threshold response. A faster response to the lowest electric current in all three teeth was seen in the middle third. Perhaps the reason for this is that this area has the shortest distance from the pulp, and secondly, the middle third is entirely flat, which makes the best contact between the electrode tip and tooth, so the electrical current is wholly directed to the pulp without being wasted or degraded. In our study, all three teeth had the highest threshold response in the cervical third. This finding was consistent with the theoretical and histological foundations showing that the teeth have the lowest neural density in the cervical third.¹⁷

It also revealed that the response threshold was not different between males and females. In other words, gender did not affect the EPT response; this finding was in contrast with the results of Udoye et al, and Šimović et al.^{4,13}

These studies show that there are many variables associated with EPT. The clinician should reduce the variables as much as possible and use the same technique in all cases. Some variables are beyond clinicians' control and affect EPT results, including the patient's perception of stimulation, which itself is influenced by emotional and psychological factors.

Conclusion

Within the limitations of this study, the results showed that in the maxillary anterior teeth, different areas of the crown differed in response threshold, and the lowest threshold belonged to the middle third of the buccal surface. This area is easily accessible and flat, and facilitates electrode stability. It has no physical or anatomical limitation, and reduces the risk of conduction of electric current to the gingiva.

Recommendations

From a scientific point of view, pulp vitality depends on healthy blood vessels, not sensory fibers. Technological progresses show that in near future, the role of pulp vitality measurement will be assigned to technologies that can

genuinely monitor the blood flow. We suggest the use of EPT to assess the depth of pulpal anesthesia following injection of local anesthesia.

Acknowledgement

This study was part of a thesis and research project (Grant No.900), supported and funded by Zahedan University of Medical Sciences.

The study was designed by Mohammad Salarpour. The study data were collected by Elahe Salarpour, Ali Dehghan dehnavi, Mohammad Salarpour.

Elahe Salarpour, Ali Dehghan dehnavi, Mohammad Salarpour edited and reviewed the article.

Conflict of Interest

No Conflict of Interest Declared ■

References

- Lin J, Chandler NP. Electric pulp testing: a review. *Int Endod J.* 2008;41(5):365-74.
- Alghaithy RA, Qualtrough AJE. Pulp sensibility and vitality tests for diagnosing pulpal health in permanent teeth: a critical review. *Int Endod J.* 2017;50(2):135-42.
- Bargale SD, Padmanabh SKD. Appropriate electrode placement site of electric pulp tester for the premolars: a clinical study. *J Indian Soc Pedod Prev Dent.* 2015;33(2):138-42.
- Šimović M, Pavušek I, Ivanišević Malčić A, Jukić S, Prpić Mehičić G, Matijević J. Electric pulp test threshold responses in healthy incisors, canines, premolars and molars. *Aust Dent J.* 2018;44(1):54-9.
- Peterson K, Söderström C, Kiani-Anaraki M, Levy G. Evaluation of the ability of thermal and electrical tests to register pulp vitality. *Endod Dent Traumatol.* 1999;15(3):127-31.
- Orchardson R, Cadden SW. An update on the physiology of the dentine-pulp complex. *Dental Update.* 2001;28(4):200-9.
- Seltzer S, Bender I, Ziontz M. The interrelationship of pulp and periodontal disease. *Oral Surg Oral Med Oral Pathol.* 1963;16(12):1474-90.
- Mumford JM. Thermal and electrical stimulation of teeth in the diagnosis of pulpal and periapical disease. *Proc R Soc Med.* 1967;60(2):197-200.
- Dummer P, Hicks R, Huws D. Clinical signs and symptoms in pulp disease. *Int Endod J.* 1980;13(1):27-35.
- Cooley RL, Robison SF. Variables associated with electric pulp testing. *Oral Surg Oral Med Oral Pathol.* 1980;50(1):66-73.
- Turedi I, Ulusoy A. Evaluation of electric pulp test thresholds and correct probe tip placement site in developing incisors: a clinical study in 1200 teeth. *Eur Arch Paediatr Dent.* 23(3):449-54.
- Lin J, Chandler N, Purton D, Monteith B. Appropriate electrode placement site for electric pulp testing first molar teeth. *J Endod.* 2007;33(11):1296-8.
- Udoye CI, Jafarzadeh H, Okechi UC, Aguwa EN. Appropriate electrode placement site for electric pulp testing of anterior teeth in Nigerian adults: a clinical study. *J Oral Sci.* 2010;52(2):287-92.
- Ingle JI, Simon JH, Walton RE, Pashley DH, Bakland LK, Heithersay GS, et al. *Pulpal pathology: Its etiology and prevention.* Endodontics fifth ed Hamilton-London: BC Decker Inc. 2002:95-174.
- Jacobson J. Probe placement during electric pulp-testing procedures. *Oral Surg J. Oral Med Pathology.* 1984;58(2):242-7.
- Idon PI, Nwamba PN, Udoye CI, Jafarzadeh H. Does dental fluorosis affect electric pulp test response and/or optimum probe placement site? *Aust Endod J.* 2021;47(2):307-13.
- Bender IB, Landau MA, Fonseca S, Trowbridge HO. The optimum placement-site of the electrode in electric pulp testing of the 12 anterior teeth. *J Am Dent Assoc.* 1989;118(3):305-10.
- Närhi M, Virtanen A, Kuhta J, Huopaniemi T. Electrical stimulation of teeth with a pulp tester in the cat. *Scand J Dent Res.* 1979;87(1):32-8.

How to cite: Dehghan Dehnavi A, Salarpour E, Salarpour M. Identification of Appropriate Probe Site in Maxillary Anterior Teeth for Electric Pulp Testing. *J Dent Sch* 2021;39(4):135-138.