

Cone-Beam Computed Tomographic Assessment of Anatomical Variations of the Interforaminal Region in a Selected Iranian Population

Solmaz Valizadeh ^a, Hessam Alesheikh^b, Mina Iranparvar Alamdari ^c

^aAssociate Professor, Dept. Oral and Maxillofacial Radiology, School of Dentistry, Shahid Beheshti University of Medical Sciences, Tehran, Iran.

^bDental Student, School of Dentistry, Shahid Beheshti University of Medical Sciences, Tehran, Iran.

^cPostgraduate Student, Dept. Oral and Maxillofacial Radiology, School of Dentistry, Shahid Beheshti University of Medical Sciences, Tehran, Iran.

Correspondence to Mina Iranparvar Alamdari (email: mina.iranparvar@gmail.com).

(Submitted: 6 July 2021 – Revised version received: 29 August 2021 – Accepted: 11 September 2021 – Published online: Autumn 2021)

Objectives This study assessed the anatomical variations of the mental foramen (MF) and presence and length of the anterior loop and the incisive canal in a selected Iranian population using cone-beam computed tomography (CBCT).

Methods This descriptive, cross-sectional study evaluated CBCT scans of 256 patients (123 males, 133 females) over 18 years of age. The CBCT multiplanar reformatted panoramic images (10-mm thickness) were used to assess the anatomical position of the MF and presence/absence and length of the anterior loop. The cross-sectional images were used to assess the presence/absence and length of the incisive canal. The anatomical variations were compared in the right and left sides and between males and females using dependent and independent t-test. SPSS version 21 was used for statistical analysis.

Results The most common position of MF was adjacent to the apex of the second premolar, noted in 41.4% of the patients. The second common position of MF was between the apices of the first and second premolars (30.1% of the patients). The anterior loop was present in 44.3% of the patients. The mean length of the anterior loop and the incisive canal was 2.64 mm and 7.15 mm, respectively. No significant difference was noted between males and females or right and left sides in any variable ($P > 0.05$).

Conclusion Anatomical variations of the anterior mandible indicate the significance of 3D imaging to prevent nerve traumatization by proper treatment planning.

Keywords Anatomy; Mandible; Mental Foramen; Cone-Beam Computed Tomography

Introduction

The inferior alveolar nerve travels forward in the mandibular canal and is branched close to the mental foramen (MF) into the mental nerve that innervates the surrounding tissue and the lower lip, as well as the incisive nerve, which remains in bone, travels in the incisive canal, and innervates the anterior teeth. However, in some individuals, the terminal part of the inferior alveolar nerve may pass through the inferior border of the MF and after branching of the incisive nerve, create a loop and return back to the MF. This anatomical variation is referred to as the anterior loop of the MF. The MF can have different shapes, sizes, and anatomical positions.¹ Comprehensive knowledge on anatomical variations of the MF and its exact position, length of the incisive canal, and presence/absence of the anterior loop is imperative prior to surgical procedures in the anterior mandible.² Moreover, repeated failures during injections and high risk of injury to the vascular branches in the anterior mandible highlight the importance of knowledge about the anatomical variations in this region.³

Wide variations have been reported in the literature regarding the prevalence and length of the anterior loop; therefore, assuming a fixed distance mesially from the mental foramen will not be safe. Also, diameter of the incisive canal should be investigated for each case in order to determine the appropriate location for each individual.^{4,5} Previous studies on anatomical variations in the MF region mainly used panoramic radiography for this purpose, which is not highly accurate due to lower precision, risk of superimposition of anatomical structures due to its 2D nature, and presence of artifacts.⁶

Considering the significance of having adequate knowledge about the surgical site anatomy, and the limitations of

conventional imaging modalities, application of advanced imaging prior to treatment planning seems imperative.

Evidence shows that magnetic resonance imaging can provide reliable cross-sectional images of the jaws for preoperative assessment of bone in implant treatment.⁷ However, despite its biological safety, magnetic resonance imaging has limitations for use especially in claustrophobic patients and those with pacemakers, implantable defibrillators, artificial heart valves, cerebral aneurysm clips, or ferrous foreign bodies in the eye.⁸ Thus, it cannot be extensively used for preoperative treatment planning.

A recent study on the efficacy of ultrasound for assessment of MF showed that this modality can be effectively used for determination of the location, shape, and size of the MF as well as the flow rate of the mental artery. Nonetheless, ultrasound has lower accuracy than cone-beam computed tomography (CBCT) in assessment of the distance between MF and alveolar crest.⁹

In the recent years, CBCT has been used for precise evaluation of anatomical structures such as the MF, incisive canal, and anterior loop. CBCT has advantages over computed tomography such as lower patient radiation dose and lower cost.¹⁰

The purpose of this study was to assess the most common anatomical variations in the MF region with regard to the position of the MF, presence/absence of the anterior loop and its length, and length of the incisive canal and any significant variations noted in an Iranian sample population using CBCT.

Methods and Materials

This descriptive cross-sectional study evaluated the CBCT scans of 256 patients retrieved from the archived scans

obtained during 2017-2018. The study was approved by the ethics committee of Shahid Beheshti University of Medical Sciences (IR.SBMU.RIDS.REC.1396.572).

All CBCT scans had been obtained by NewTom VGi CBCT scanner (Verona, Italy) with the exposure settings of 110 kVp, 12 x 8 cm field of view, and 200 μ m voxel size. CBCT scans had been requested by the attending dental clinicians for diagnostic purposes not related to this study.

The inclusion criteria were CBCT scans of the mandible visualizing central and lateral incisors, canine teeth, first and second premolars, and first molars of patients over 18 years of age.

The exclusion criteria were systemic and endocrine conditions affecting the bone metabolism such as osteoporosis, hyperparathyroidism, Paget's disease, and renal osteodystrophy (determined based on patient records), local conditions affecting the bone quality and quantity in the mandible such as moderate to severe periodontitis, cysts, neoplasms, trauma or previous surgery in the region, presence of teeth with extensive amalgam restorations creating significant artifacts on the image, and presence of motion artifacts which would compromise correct interpretation of images.

After selection of eligible CBCT scans, all images were checked and their occlusal planes were parallelized to ensure the accuracy of all cross-sectional images. Cross-sectional slices were made perpendicular to the alveolar ridge in the anterior and posterior mandible at the site of central and lateral incisors, canine teeth, first and second premolars, and first molars.

This study focused on the anatomical position of the MF and presence/absence of the incisive canal and anterior loop and their lengths; thus, the following parameters were measured:

- Anatomical position of the MF in the right and left sides
- Mean length of the incisive canal in the right and left sides
- Mean length of the anterior loop in the right and left sides

All the above mentioned measurements were reported separately for males and females. All measurements were made by a senior dental student, who had been previously trained by an oral and maxillofacial radiologist. Thirty images were randomly chosen and measured again by the same observer after one month. The reliability of the measurements was examined using Kappa statistics (>0.75) and by calculating the intraclass correlation coefficient ($=85\%$). The mean difference between the measurements, calculated by paired t-test, was not statistically significant ($P>0.05$).

Anatomical position of the MF:

For assessment of the anatomical position of the MF, the MF region was divided into six areas as follows: (I) between the roots of the canine and first premolar teeth, (II) adjacent to the root apex of the first premolar tooth¹¹, between the roots of the first and second premolars, (IV) adjacent to the root apex of the second premolar tooth, (V) between the roots of the second premolar and first molar, (VI) and adjacent to the root apex of the first molar.¹

CBCT multiplanar reformatted panoramic images (10 mm thickness) were reconstructed. After finding the MF on the CBCT Panorex image, the center of the MF was marked, the cursor was fixed at the center of the MF and moved towards the cemento-enamel junction. The anatomical position of the MF relative to its adjacent teeth was determined.

Presence and length of the anterior loop:

To assess the presence of the anterior loop, the CBCT Panorex images of the MF were used. In case of presence of the anterior loop in this region, the distance between the anterior border of the MF and the anterior border of the anterior loop was measured to determine the anterior loop length. For this purpose, on Panorex images, a line was drawn tangent to the inferior border of the mandible and then two lines were drawn perpendicular to it; one of them was tangent to the anterior border of the MF and the other one was tangent to the anterior border of the anterior loop. The distance between the two lines was measured by the software ruler (Figure 1).

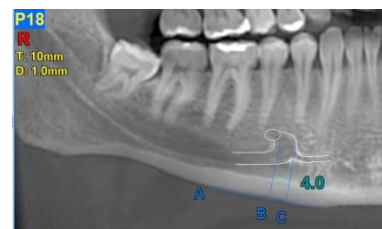


Figure 1- Schematic view of the inferior alveolar nerve anterior loop, MF and the incisive canal; A is the line tangent to the inferior border of the mandible, B is the line perpendicular to A and tangent to the anterior border of the MF, C is the line perpendicular to A and tangent to the anterior border of the anterior loop. The shortest distance between B and C, or the length of the anterior loop is 4 mm.

Presence and length of the incisive canal:

Cross-sectional CBCT images were used to assess the presence of the incisive canal. For this purpose, first, cross-sectional cut of the MF was found (discontinuation of buccal cortex at the foramen area) and then the next sections were included until a section with a round lucent region with an opaque rim, which was considered as the incisive canal, was observed. Since the slice interval and image thickness were both 1 mm, the total number of cross-sectional images that visualized the incisive canal was considered as the canal length (Figure 2).

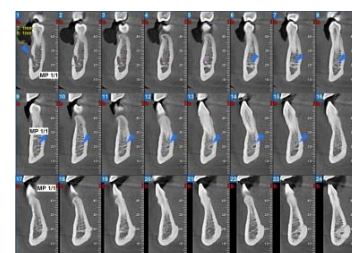


Figure 2- Cross-sectional view of the mandible visualizing the incisive canal. Since the slice interval was 1 mm and the incisive canal was seen in 10 sections, the length of the incisive canal was calculated to be 10 mm.

Statistical analysis:

Data were statistically analyzed using SPSS version 21. Measures of central dispersion were reported for the

variables. Data were compared between males and females and the right and left sides using dependent and independent t-tests.

Results

The CBCT scans of 256 patients including 123 males (48.04%) and 133 females (51.96%) were evaluated.

Figure 3 shows the position of MF in the right and left sides based on its prevalence in the six areas described earlier. As shown, the most common position for MF (41.4%) in the right and left sides in both males and females was at the second premolar region (position IV). The area between the apices of the first and second premolars was ranked next (30.1%).

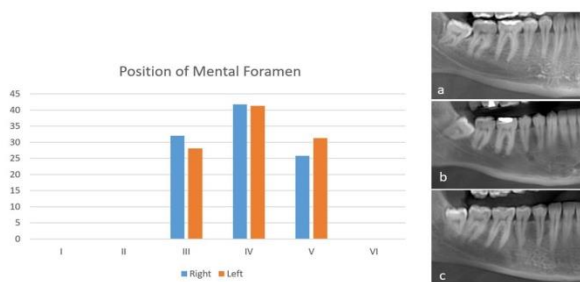


Figure 3- Position of MF in the right (blue bars) and left (orange bars) sides based on its prevalence in the six areas described earlier

The incisive canal was present in all of the patients. Table 1 shows the mean length of the incisive canal in the right and left sides in males and females. As shown, the length of the incisive canal was not significantly different in the right and left sides ($P=0.18$) or in males and females. Comparing male and female patients, the P value was 0.19 for the left side and 0.15 for the right side. The minimum, maximum and mean recorded lengths of the incisive canal in our study population were 2, 15 and 7.15 mm, respectively.

Table 1- Mean length of the incisive canal in the right and left sides in males and females

Side	Gender	Number	Mean length (mm)	P Value
Right	Male	123	7.42	0.150
	Female	133	7.19	
Left	Male	123	7.26	0.194
	Female	133	7.02	
Total	Right	256	7.22	0.182
	Left	256	7.08	

Table 2 shows the mean length of the anterior loop in the right and left sides in males and females. The mean and maximum lengths were 2.64 mm and 6.1 mm, respectively. The anterior loop was present in 44.3% of the patients (43.1% of males and 45.45% of females). Its mean length was not significantly different in the right and left sides ($P=0.62$), or between males and females ($P=0.90$ and $P=0.60$ for left and right sides respectively).

Table 2- Mean length of the anterior loop in the right and left sides in males and females

Side	Gender	Number	Mean length (mm)	P Value
Right	Male	123	2.83	0.596
	Female	133	2.53	
Left	Male	123	2.59	0.897
	Female	133	2.65	
Total	Right	256	2.68	0.624
	Left	256	2.59	

Discussion

Knowledge about the anatomy of the anterior mandible can be acquired primarily by studies on the skulls^{3,12}, and more precisely by 3D imaging modalities, particularly CBCT.

Computed tomography can three-dimensionally reveal the quality, quantity, and morphology of the available alveolar bone. In the recent years, several studies have assessed the anatomical variations of the important landmarks in the maxillofacial region for more precise treatment planning and minimizing the rate of complications. The MF is an important landmark in the mandible, which has been the topic of many previous investigations. The position of the MF changes as a result of alveolar atrophy and it is shown that the MF was situated on average 3.8 mm lower in edentulous jaws than in dentulous jaws.¹³ There are also variations in shape, opening direction and location of MF between different races.¹ This study confirmed the results of previous studies regarding high anatomical variations of the assessed landmarks. Despite the availability of several studies on this topic, the current study evaluated these landmarks in a larger Iranian population. Moreover, as mentioned earlier, the patients with a history of systemic diseases affecting the structure of bone or local conditions such as moderate to severe periodontitis, cysts, neoplasms, trauma, or previous surgery in the region, were excluded from the study.

This study assessed the anatomical variations of the MF, incisive canal, and anterior loop in a selected Iranian population using CBCT. Also, the anatomical variations were compared between right and left sides, and males and females. The current results indicated that the most common position of the MF was adjacent to the apex of the second premolar tooth (41.4%). The position of MF between the apices of the first and second premolars ranked second in terms of prevalence (30.1%). No significant difference was noted in the position of MF between the right and left sides or between males and females. The results of this study were similar to previous studies on Iranian populations using CBCT, reporting that the most common location of MF was adjacent to the second premolar apex in both sides and in both males and females.¹⁴⁻¹⁶ In the study by Safaee et al.,¹⁶ the area between the apices of the first and second premolars was the second most common location of MF.

Philips et al.¹⁷ used panoramic radiography to assess the position of mental foramen in dry adult human mandibles and reported that the average position of the mental foramen was mesial and below the apex of second premolar. Amorim

et al.¹⁸ conducted a panoramic-based study on a Brazilian population and reported that the area between the apices of premolars was the most common location of MF. Studies on the Iranian populations using panoramic radiography reported the most common location of MF to be between the two premolars or in vicinity of the second premolar.¹⁹⁻²¹ Due to limitations of 2-dimensional imaging, position of the MF on panoramic images is shown to be affected by the horizontal course of the inferior alveolar nerve.²² These results indicate the high value of CBCT for surgical procedures in the anterior mandible.

An anthropometric study of the position of MF in three different populations found that in the Chinese population, the most common location was adjacent to the second premolar apex while in the European and Indian populations, MF was between the apices of the first and second premolars in most cases.²³ Therefore, variations in the results can be attributed to racial and ethnic differences between the study populations.

In this study, the incisive canal was evaluated on cross-sectional images as a radiolucent area surrounded by an opaque rim. Our results indicated the presence of the incisive canal in 100% of our study population, which was different from the findings of Makris et al,²⁴ and Pires et al,²⁵ who reported the incisive canal on CBCT scans of 83.5% and 83.0% of their study population, respectively. In an Iranian population, incisive canal was reported in 97.5%²⁶ of the study population using CBCT. The mandibular incisive canal has a small diameter, which becomes progressively smaller as it passes to more anterior portions of the mandible. This canal is surrounded by less cortical bone compared with the mandibular canal.²⁷ These two facts could explain the differences in the reported values.

The mean length of the incisive canal was 7.15 mm in this study, which was shorter than the length reported by Rosa et al,²⁷ who reported a mean length of 9.11 mm using CBCT reformatted panoramic images in a Brazilian population. Lim et al,²⁸ in Malaysia reported the mean canal length to be 11.3 mm, using panoramic reconstructed CBCT images. A study on an Iranian population using CBCT reformatted panoramic images reported the mean length of the mandibular incisive canal to be about 10.4 mm.²⁶ The difference in the reported lengths of the incisive canal in studies could be a result of racial differences and also differences in methods of measurements. Makris et al.²⁴ used

CBCT cross-sectional scans with a similar method to the current study and reported a mean canal length of 15 mm in a Greek sample population.

In this study, the anterior loop was noted in 44.3% of the patients. Moghddam et al.²⁹ reported the presence of anterior loop in 40.6% of patients using CBCT. Other studies on the Iranian populations detected the anterior loop in 59.5%²⁶ and 32.8%⁵ of their study populations using CBCT. The frequency of anterior extension of alveolar loop was 69.7% in the study by Filo et al,³⁰ on a Swiss population using CBCT. Li et al.³¹ used spiral computed tomography and reported the prevalence of the anterior loop to be 83.1% in a Chinese population. Such variations in the reported prevalence rates for the anterior loop can be due to geographical, racial, or ethnic differences of the study populations. Application of different imaging modalities, measurement methods, and using different definitions for the anterior loop are responsible for high variability in the reported results.

In our study, the mean length of the anterior loop was 2.64 mm, which was approximately similar to the values reported in the literature.^{5, 27, 29} Future studies on different ethnic groups residing in Iran are recommended.

Variations in the location of MF, the considerable prevalence of the anterior loop, and the relatively high prevalence of the incisive canal in this study highlight the significance of requesting preoperative CBCT of the anterior mandible for precise treatment planning to prevent complications.

Conclusion

The most common location of the MF in our study population was found to be adjacent to the second premolar apex followed by between the roots of the first and second premolars. The incisive canal was observed in all patients, and the anterior loop was present in 44.3% of the population. Mean lengths of the incisive canal and anterior loop were 7.15 mm and 2.64 mm, respectively and no significant difference was observed between the right and left sides or males and females.

Conflict of Interest

No Conflict of Interest Declared ■

References

1. Sheikhi M, Karbasi Kheir M, Hekmatian E. Cone-Beam Computed Tomography Evaluation of Mental Foramen Variations: A Preliminary Study. *Radiol Res Pract.* 2015;2015:124635.
2. do Nascimento EHL, Dos Anjos Pontual ML, Dos Anjos Pontual A, da Cruz Perez DE, Figueiroa JN, Frazão MAG, et al. Assessment of the anterior loop of the mandibular canal: A study using cone-beam computed tomography. *Imaging Sci Dent.* 2016;46(2):69-75.
3. Mendonca Amorim M, Bevilacqua Prado F, Bicalho Borini C, Oliveira Bittar T, Volpato MC, Groppo FC, et al. The Mental Foramen Position in Dentate and Edentulous Brazilian's Mandible. *Int J Morphology.* 2008;26:981-7.
4. Uchida Y, Yamashita Y, Goto M, Hanihara T. Measurement of Anterior Loop Length for the Mandibular Canal and Diameter of the Mandibular Incisive Canal to Avoid Nerve Damage When Installing Endosseous Implants in the Interforaminal Region. *J Oral Maxillofac Surg.* 2007;65(9):1772-9.
5. Kheir MK, Sheikhi M. Assessment of the anterior loop of mental nerve in an Iranian population using cone beam computed tomography scan. *Dent Res J.* 2017;14(6):418-22.
6. Eren H, Orhan K, Bagis N, Nalcaci R, Misirli M, Hincal E. Cone beam computed tomography evaluation of mandibular canal

anterior loop morphology and volume in a group of Turkish patients. *Biotechnol Biotechnol Equip.* 2016;30(2):346-53.

7. Aguiar MF, Marques AP, Carvalho AC, Cavalcanti MG. Accuracy of magnetic resonance imaging compared with computed tomography for implant planning. *Clin Oral Implants Res.* 2008;19(4):362-5.
8. Demirturk Kocasarac H, Geha H, Gaalaas LR, Nixdorf DR. MRI for Dental Applications. *Dent Clin North Am.* 2018;62(3):467-80.
9. Çağlayan F, Sümbüllü MA, Akgül HM. Is ultrasonography sufficient for evaluation of mental foramen? *Dentomaxillofac Radiol.* 2019;48(3):20180252.
10. Makris N, Stamatakis H, Syriopoulos K, Tsiklakis K, Van Der Stelt PF. Evaluation of the visibility and the course of the mandibular incisive canal and the lingual foramen using cone-beam computed tomography. *Clin. Oral Impl. Res.* 2010;21(7):766-71.
11. Bateman RM, Sharpe MD, Jagger JE, Ellis CG, Solé-Violán J, López-Rodríguez M, et al. 36th International Symposium on Intensive Care and Emergency Medicine : Brussels, Belgium. 15-18 March 2016. *Crit Care.* 2016;20(Suppl 2):94.
12. Shashidhar K, Sridevi NS. Anthropometric analysis of mental foramen in dry human mandibles in Karnataka. *Natl J Clin Anat [serial online].* 2019;8(4):148-52.
13. Soikkonen K, Wolf J, Ainamo A, Qiufei X. Changes in the position of the mental foramen as a result of alveolar atrophy. *J Oral Rehabil.* 1995;22(11):831-3.
14. Harandi A, Moudi E, Gholinia H, Akbarnezhad M. A cone-beam computed tomography study of apical and mental foramen's location in mandibular premolars. *Caspian J Dent Res.* 2018;7(1):27-36.
15. Khojastepour L, Mirbeigi S, Mirhadi S, Safaee A. Location of Mental Foramen in a Selected Iranian Population: A CBCT Assessment. *Iran Endod J.* 2015;10(2):117-21.
16. Safaee A, Mirbeigi S, Ezoddini F, Khojastepour L, Navab-Azam A. Buccolingual course of the inferior alveolar canal in different mental foramen locations: A cone beam computed tomography study of an Iranian population. *Int J Appl Basic Med Res.* 2016;6(4):262-6.
17. Phillips JL, Weller RN, Kulild JC. The mental foramen: 3. Size and position on panoramic radiographs. *J Endod.* 1992;18(8):383-6.
18. Amorim MM, Borini CB, Lopes SLPdC, Haiter-Neto F, Caria PHF. Morphological Description of Mandibular Canal in Panoramic Radiographs of Brazilian Subjects: Association Between Anatomic Characteristic and Clinical Procedures. *Int. J. Morphol.* 2009;27:1243-8.
19. Haghanifar S, Rokouei M. Radiographic evaluation of the mental foramen in a selected Iranian population. *Indian J Dent Res.* 2009;20(2):150-2.
20. Dehghani M, Ghanea S. Position of the Mental Foramen in Panoramic Radiography and Its Relationship to Age in a Selected Iranian Population. *Avicenna J Dent Res.* 2016;8(1): e25459.
21. Saberi Ea, Kazemian R, Farhadmollashahi N, Mohammadi A, Alidadiani F. Location of mental foramen in a southeast Iranian population: a digital panoramic assessment. *Caspian J Dent Res.* 2017;6(2):44-7.
22. Pyun JH, Lim YJ, Kim MJ, Ahn SJ, Kim J. Position of the mental foramen on panoramic radiographs and its relation to the horizontal course of the mandibular canal: a computed tomographic analysis. *Clin Oral Impl. Res.* 2013;24(8):890-5.
23. Santini A, Alayan I. A comparative anthropometric study of the position of the mental foramen in three populations. *Br Dent J.* 2012;212(4):E7.
24. Makris N, Stamatakis H, Syriopoulos K, Tsiklakis K, van der Stelt PF. Evaluation of the visibility and the course of the mandibular incisive canal and the lingual foramen using cone-beam computed tomography. *Clin Oral Impl. Res.* 2010;21(7):766-71.
25. Pires CA, Bissada NF, Becker JJ, Kanawati A, Landers MA. Mandibular Incisive Canal: Cone Beam Computed Tomography. *Clin Implant Dent Relat Res.* 2012;14(1):67-73.
26. Panjnoush M, Rabiee ZS, Kheirandish Y. Assessment of Location and Anatomical Characteristics of Mental Foramen, Anterior Loop and Mandibular Incisive Canal Using Cone Beam Computed Tomography. *J Dent (Tehran).* 2016;13(2):126-32.
27. Rosa MB, Sotto-Maior BS, Machado Vde C, Francischone CE. Retrospective study of the anterior loop of the inferior alveolar nerve and the incisive canal using cone beam computed tomography. *Int J Oral Maxillofac Implants.* 2013;28(2):388-92.
28. Lim JTS, Kang WJ, Ajit Bapat R, Kanneppady SK, Pandurangappa R. Evaluation of Mandibular Incisive Canal using Cone Beam Computed Tomography in Malaysians. *J. Maxillofac. Oral Surg.* 2019;18(4):596-603.
29. Moghddam MR, Davoudmanesh Z, Azizi N, Rakhshan V, Shariati M. Prevalence and Length of the Anterior Loop of the Inferior Alveolar Nerve in Iranians. *J Oral Implantol.* 2017;43(5):333-6.
30. Filo K, Schneider T, Locher MC, Kruse AL, Lübbers HT. The inferior alveolar nerve's loop at the mental foramen and its implications for surgery. *J Am Dent Assoc.* 2014;145(3):260-9.
31. Li X, Jin ZK, Zhao H, Yang K, Duan JM, Wang WJ. The prevalence, length and position of the anterior loop of the inferior alveolar nerve in Chinese, assessed by spiral computed tomography. *Surgical and radiologic anatomy : Surg Radiol Anat.* 2013;35(9):823-30.

How to cite:

Valizadeh S, Alesheikh H, Iranparvar Alamdari M. Cone-Beam Computed Tomographic Assessment of Anatomical Variations of the Interforaminal Region in a Selected Iranian Population. *J Dent Sch* 2020;38(4):153-157.