

# Dimensional Distortion of Four Types of Intracanal Posts on CBCT Scans with Different Fields of View and Resolutions

Solmaz Valizadeh <sup>a</sup>, Alireza Karimi Nasab <sup>b</sup>, Mina Iranparvar Alamdari <sup>c</sup>, Zahra Vasegh <sup>d</sup>

<sup>a</sup>Associate Professor, Dept. Oral and Maxillofacial Radiology, School of Dentistry, Shahid Beheshti University of Medical Sciences, Tehran, Iran.

<sup>b</sup>Dental Student, School of Dentistry, Shahid Beheshti University of Medical Sciences, Tehran, Iran.

<sup>c</sup>Postgraduate Student, Dept. Oral and Maxillofacial Radiology, School of Dentistry, Shahid Beheshti University of Medical Sciences, Tehran, Iran.

<sup>d</sup>Assistant professor, Dept. Oral and Maxillofacial Radiology, School of Dentistry, Shahid Beheshti University of Medical Sciences, Tehran, Iran.

Correspondence to Mina Iranparvar Alamdari (email:mina.iranparvar@sbmu.ac.ir)

(Submitted: 27 Jun 2021 – Revised version received: 23 Nov 2021 – Accepted: 24 Nov 2021 – Published online: Summer 2022)

**Objectives** This study assessed the dimensional distortion of four types of intracanal posts on cone-beam computed tomography (CBCT) scans with two different fields of view (FOV) in high and standard resolution modes.

**Methods** This in vitro study evaluated 40 extracted single-rooted maxillary central incisors that underwent root canal treatment. The teeth were randomly assigned to 4 groups (n=10) for placement of non-tapered brass, silver, titanium and stainless steel (SS) intracanal posts. The diameter of the posts was measured at two reference points by a digital caliper (gold standard). The teeth underwent CBCT with 8 x 8 and 8 x 12 cm FOV with high and standard resolution modes. The post diameters were measured on axial CBCT images at the same reference points and compared with the gold standard. Data were analyzed by ANOVA, and paired and independent sample t-test.

**Results** Significant differences were noted between the radiographic diameter of the posts and their actual size (P<0.05). Titanium posts (40.25%) showed minimum percentage of dimensional distortion followed by brass (54%), silver (62.5%) and SS (70.17%) posts. High-resolution images with 8 x 8 cm FOV yielded minimum dimensional distortion (40.6%) followed by high-resolution images with 8 x 12 cm FOV (45.75%), standard-resolution images with 8 x 8 cm FOV (68.75%), and standard-resolution images with 8 x 12 cm FOV (72.1%).

**Conclusion** All metal posts showed significant dimensional distortion on CBCT scans, irrespective of the FOV size and resolution mode. SS posts yielded maximum, and titanium posts showed minimum dimensional distortion.

**Keywords** Artifacts; Cone-Beam Computed Tomography; Dimensional Measurement Accuracy

## Introduction

Post and core treatment is the restorative treatment of choice for endodontically treated teeth that have lost a large portion of their tooth structure, aiming to preserve the residual tooth structure.<sup>1</sup> Use of intracanal posts has a long history in dentistry. Radiography enables the assessment of intracanal posts and the residual tooth structure. However, two-dimensional radiography cannot provide three-dimensional diagnostic data, and valuable information may be lost in this process.<sup>2,3</sup> Thus, computed tomography (CT) and cone-beam computed tomography (CBCT) were introduced to overcome the limitations of two-dimensional radiography.<sup>4</sup> Introduction of CBCT in the late 1990 overcame many of the limitations of CT, since CBCT has lower patient radiation dose, shorter scanning time, and smaller size of equipment than CT.<sup>5-7</sup>

Despite the increasing use of CBCT as a diagnostic imaging modality, it has drawbacks such as generation of artifacts, which can compromise the diagnostic quality of images.<sup>8</sup> Artifact refers to the difference between the reconstructed image and the actual object, which decreases the quality and diagnostic value of images. Artifacts generated by metal and non-metal intracanal posts can compromise the quality of CBCT images. These artifacts can mask the tooth structure and lead to misdiagnosis. Ferreira et al, and Neves et al. reported that intracanal metal posts could significantly compromise the diagnosis of vertical root fractures (VRFs) on CBCT images.<sup>9,10</sup>

The exposure parameters, size of field of view (FOV), and resolution of CBCT scanners can affect the generation of

metal artifacts as well. Thus, this study aimed to assess the dimensional distortion of four types of intracanal posts on CBCT scans with two different FOVs and high and standard resolution modes.

## Methods and Materials

This in vitro, experimental study evaluated 40 single-rooted maxillary central incisors extracted for purposes not related to this study. The study was approved by the ethics committee of Shahid Beheshti University of Medical Sciences (IR.SBMU.RIDS.REC.1394.148). The sample size was calculated to be 10 in each group assuming  $\alpha=0.05$ , and 10% error, using Power analysis and Sample Size software.

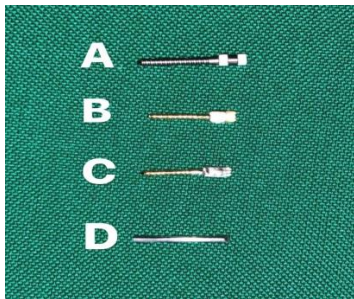
The inclusion criterion was extracted maxillary central incisors with sound roots (no root resorption or fracture). The teeth were mounted in putty impression material prior to root canal treatment, and were randomly assigned to four groups (each group had 10 teeth). Root canal treatment was performed by a senior dental student, and the root canals were obturated with gutta-percha. Next, the gutta-percha was removed from the root canals to 5 mm from the apex, and the post space was prepared with size 2 and size 3 peeso reamers (Mani, Japan). Prior to placement of intracanal posts, the diameter of the posts was measured at reference points at 2 and 4 mm from the post tip by a digital caliper (Mitutoyo, Japan) with 0.01 mm accuracy, and the mean of the measured diameters was considered as the gold standard. The teeth then received the following non-tapered intracanal posts (Figure 1): Group A: Titanium posts (Svenska Dentaroma, Sweden) with

a mean diameter of 1.17 mm

Group B: Brass posts (Nordin, Switzerland) with a mean diameter of 1.14 mm

Group C: Silver posts (Shenzhen, China) with a mean diameter of 1.12 mm

Group D: Stainless Steel wire used as post (3M Unitek, USA) with a mean diameter of 1.02 mm



**Figure 1:** Different posts used for the study: (A) titanium, (B) brass, (C) silver and (D) stainless steel

Next, each post and the respective tooth were coded. The posts were then placed in the root canals.

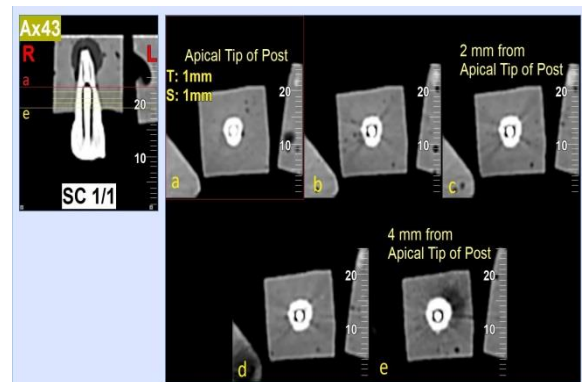
All teeth then underwent CBCT in a NewTom VGI scanner (Verona, Italy) with the most commonly used FOVs in clinical practice as follows:

- Scanning of the posts with 8 x 8 cm FOV and standard resolution (200- $\mu$ m voxel size)
- Scanning of the posts with 8 x 8 cm FOV and high resolution (100- $\mu$ m voxel size)
- Scanning of the posts with 8 x 12 cm FOV and standard resolution (200- $\mu$ m voxel size)
- Scanning of the posts with 8 x 12 cm FOV and high resolution (100- $\mu$ m voxel size)

For imaging with 8 x 12 cm FOV, 5 teeth from each group were scanned at the same time, and the teeth were placed next to each other in a U-shaped arrangement. For imaging with 8 x 8 cm FOV, 2 teeth were linearly placed next to each other for each scanning cycle. All measurements were performed using NNT software version 8.0. The measurements were made on the axial plane of CBCT images. For this purpose, after image reconstruction in the axial plane with 1 mm slice interval, the maximum post dimension on axial images at 2 and 4 mm from the apical tip of the post was measured using the software ruler, and the mean of the measured values was recorded as the post diameter on CBCT images (Figure 2).

All measurements were accomplished by a senior dental student, trained by an oral and maxillofacial radiologist. To assess the reliability of the measurements, the intraclass correlation coefficient was calculated ( $\approx 85\%$ ). The mean difference between the measurements, analyzed by paired t-test, was not statistically significant ( $P > 0.05$ ).

Data were analyzed by SPSS version 18 (SPSS Inc., IL, USA). The frequency, percentage, mean, and standard deviation of the data were reported, and comparisons were made using paired sample t-test and mixed ANOVA with one within-subject factor (scanning protocol) and one between-subject factor (post material). For pairwise comparisons, the Bonferroni test was used.



**Figure 2:** Axial CBCT images of a titanium post in 12 x 8 cm FOV with 1 mm slice interval, a: indicating the apical tip of the post, b: axial image 1 mm from the apex tip, c: measurement of the maximum post dimension at 2 mm from the apex tip, d: axial image 3 mm from the apex tip, e: measurement of the maximum post dimension at 4 mm from the apex tip

## Results

During the study, one tooth with silver post broke and was therefore excluded from statistical analysis. Significant differences were observed between the actual sizes measured by a caliper and radiographic diameter of the posts in both sizes of FOV and resolution modes in all study groups ( $P < 0.05$ ). Table 1 shows the mean diameter of the posts measured by a caliper and their mean diameter on the four types of images. As shown, the mean diameter of the posts was minimum on high-resolution images with 8 x 8 cm FOV, and maximum on standard-resolution images with 8 x 12 cm FOV.

**Table 1-** Mean diameter and standard deviation values of different posts in clinical and radiographic measurements

|                   | Titanium  |       | Brass     |       | Silver    |       | Stainless steel |       |
|-------------------|-----------|-------|-----------|-------|-----------|-------|-----------------|-------|
|                   | Mean (mm) | SD    | Mean (mm) | SD    | Mean (mm) | SD    | Mean (mm)       | SD    |
| Caliper           | 1.17      | 0.004 | 1.14      | 0.005 | 1.12      | 0.004 | 1.02            | 0.004 |
| High Res-FOV 8x8  | 1.53      | 0.086 | 1.57      | 0.075 | 1.62      | 0.081 | 1.54            | 0.067 |
| High Res-FOV 8x12 | 1.57      | 0.092 | 1.63      | 0.085 | 1.69      | 0.102 | 1.60            | 0.060 |
| Std. Res-FOV 8x8  | 1.71      | 0.091 | 1.89      | 0.097 | 1.96      | 0.129 | 1.91            | 0.133 |
| Std. Res-FOV 8x12 | 1.76      | 0.088 | 1.97      | 0.131 | 2.01      | 0.116 | 1.91            | 0.197 |

Res: Resolution; Std.: Standard; FOV: Field of view

Table 2 illustrates pairwise comparisons of the images in all groups regarding the mean diameter of the posts. As shown, in

all study groups, significant differences were observed between all image types ( $P < 0.001$ ) except for high-resolution

images with 8 x 12 cm FOV and high-resolution images with 8 x 8 cm FOV ( $P>0.05$ ), and standard-resolution images with 8 x 8 cm FOV and standard-resolution images with 8 x 12 cm FOV ( $P>0.05$ ). Maximum and minimum percentage of image

distortion in each group are shown in Table 3.

Pairwise comparisons of different intracanal posts in each scan mode are summarized in Table 4.

**Table 2-** P-values for pairwise comparisons of the measured diameters in different scan modes. Significant differences are shown by asterisk (\*).

|                   | High Res-FOV 8x8  | High Res-FOV 8x12 | Std. Res-FOV 8x8  | Std. Res-FOV 8x12 |
|-------------------|---|-------------------|---|-------------------|
| High Res-FOV 8x8  |   |                   |   |                   |
| High Res-FOV 8x12 | Titanium= 0.55<br>Brass= 0.07<br>Silver= 0.09<br>SS= 0.07 |                   |   |                   |
| Std. Res-FOV 8x8  | P<0.05*   | P<0.05*           |   |                   |
| Std. Res-FOV 8x12 | P<0.05*   | P<0.05*           | Titanium= 0.46<br>Brass= 0.10<br>Silver= 0.75<br>SS= 1.00 |                   |

Res: Resolution; Std.: Standard; FOV: Field of view; SS: Stainless steel

**Table 3-** Maximum and minimum percentage of image distortion in each study group

|                                  | Titanium post                  | Brass post                    | Silver post                    | SS post                        |
|----------------------------------|--------------------------------|-------------------------------|--------------------------------|--------------------------------|
| Maximum percentage of distortion | Std. Res-FOV 8 x 12 cm (50.6%) | Std. Res-FOV 8 x 12 cm (72%)  | Std. Res-FOV 8 x 12 cm (79.5%) | Std. Res-FOV 8 x 12 cm (79.5%) |
| Minimum percentage of distortion | High Res-FOV 8 x 12 cm (30.5%) | High Res-FOV 8 x 8 cm (36.8%) | High Res-FOV 8 x 8 cm (45%)    | High Res-FOV 8 x 8 cm (45%)    |

Res: Resolution; Std.: Standard; FOV: Field of view

**Table 4-** P-values for pairwise comparisons of different posts in different scan modes

|                 | High Res-FOV 8x8 | High Res-FOV 8x12 | Std. Res-FOV 8x8 | Std. Res-FOV 8x12 |
|-----------------|------------------|-------------------|------------------|-------------------|
| Titanium-Brass  | P=0.13           | P<0.05 *          | P<0.05 *         | P<0.05 *          |
| Titanium-Silver | P<0.05 *         | P<0.05 *          | P<0.05 *         | P<0.05 *          |
| Titanium-SS     | P<0.05 *         | P<0.05 *          | P<0.05 *         | P<0.05*           |
| Brass-Silver    | P<0.05 *         | P<0.05 *          | P=0.14           | P=0.84            |
| Brass-SS        | P<0.05 *         | P<0.05 *          | P<0.05 *         | P=0.95            |
| Silver-SS       | P=1.00           | P=1.00            | P=0.63           | P=1.00            |

Significant differences are shown by asterisk (\*). Res: Resolution; Std.: Standard; FOV: Field of view; SS: Stainless steel

## Discussion

This study assessed the dimensional distortion of four types of intracanal posts on CBCT scans with two different FOVs and high and standard resolution modes. The results showed that all metal posts experienced significant dimensional distortion on CBCT images, with significant differences with their actual dimensions. Titanium posts experienced minimum percentage of dimensional distortion, followed by brass, silver, and SS posts. Also, high-resolution images with 8 x 8 cm FOV yielded minimum dimensional distortion (40.6%) followed by high-resolution images with 8 x 12 cm FOV (45.75%), standard-resolution images with 8 x 8 cm FOV (68.75%), and standard-resolution images with 8 x 12 cm FOV (72.1%). The effect of changing the image resolution on dimensional distortion was much greater than that of changing the FOV. Although changing the FOV changed the dimensional distortion, this change was not significant. Thus, use of high-resolution mode with smaller FOV is recommended. Pairwise comparisons of different types of intracanal posts on the four types of images revealed significant differences in dimensional distortion between the titanium and SS posts. Considering the comparably optimal quality of both titanium and SS posts in terms of intracanal retention, titanium posts

can serve as a suitable alternative to SS posts when future CBCT scans may be required (in order to minimize the amount of generated artifacts).

Lira de Farias Freitas et al. evaluated the artifacts generated by intracanal materials in single-rooted teeth. They used Ni-Cr and Ag-Pd intracanal posts and compared teeth with and without intracanal posts and without root filling. They concluded that increase in the atomic number of posts as well as root filling materials increased the generated artifacts.<sup>11</sup> Considering the type of post material in the present study and the fact that the atomic number of titanium is lower than that of brass, and the atomic number of brass is lower than that of SS and silver, our results are similar to those of Lira de Farias Freitas et al. De Lima et al.<sup>12</sup>, Dutra et al.<sup>13</sup> and Ferreira et al.<sup>9</sup> reported that metal posts significantly compromised the diagnosis of VRFs. Our results confirmed their findings since the dimensional distortion of posts on CBCT images was considerable in our study, even for titanium posts that showed minimum amount of distortion. In a similar study, Safi et al. evaluated the effect of amperage and FOV on artifacts generated by intracanal metal posts, and the role of diagnostic parameters on detection of VRFs. They reported that smaller FOVs contributed to the diagnosis of VRFs, and a significant difference existed in this respect between the large and small

FOVs.<sup>14</sup> In our study, the smaller FOV caused smaller dimensional distortion, but this difference was not statistically significant. The results of Safi et al. may be due to the fact that statistically insignificant dimensional distortion can cause a significant change in diagnosis, particularly for the diagnosis of VRFs. Neves et al. pointed to the significant negative effect of intracanal metal posts on detection of VRFs. Their results were in line with our findings since the present results showed considerable distortion of metal posts on CBCT images. They also compared high-resolution and standard-resolution images, and found no significant difference between them regarding the detection of VRFs.<sup>10</sup> This result was somehow different from our findings. In the present study, the post diameter on high-resolution and standard-resolution images had significant differences with actual dimensions measured by a caliper. Absence of a significant difference in detection of VRFs on high-resolution and standard-resolution images in their study may be due to significant differences of the measurements made on both types of images with the actual values. Mohammadpour et al. evaluated the detection of VRFs in presence of titanium and SS posts, and reported the adverse effect of metal posts on detection of VRFs.<sup>15</sup> Their results were in agreement with our findings considering the

significant distortion of posts on CBCT images in our study. Moreover, they reported easier detection of VRFs in presence of titanium posts, compared with SS posts, which can be due to smaller dimensional distortion of titanium posts compared with SS posts, as shown in the present study. Estrela et al. evaluated the artifacts and dimensional distortion of gold and silver intracanal cast posts.<sup>16</sup> Similar to our study, they showed a significant difference between the post dimensions on images and their actual diameter. Future studies on different types of posts and different exposure parameters are required to better elucidate this topic.

## Conclusion

All metal posts showed significant dimensional distortion on CBCT scans, irrespective of the size of FOV and resolution. SS posts yielded maximum and titanium posts showed minimum dimensional distortion.

## Conflict of Interest

No Conflict of Interest Declared ■

## References

- Mamoun J. Post and core build-ups in crown and bridge abutments: Bio-mechanical advantages and disadvantages. *J Adv Prosthodont*. 2017;9(3):232-7.
- Nance R, Tyndall D, Levin LG, Trope M. Identification of root canals in molars by tuned-aperture computed tomography. *Int Endod J*. 2000;33(4):392-6.
- Cohenca N, Simon JH, Roges R, Morag Y, Malfaz JM. Clinical indications for digital imaging in dento-alveolar trauma. Part 1: traumatic injuries. *Dent Traumatol*. 2007;23(2):95-104.
- Patel S, Brown J, Pimentel T, Kelly RD, Abella F, Durack C. Cone beam computed tomography in Endodontics - a review of the literature. *Int Endod J*. 2019;52(8):1138-52.
- Valizadeh S, Khosravi M, Azizi Z. Diagnostic accuracy of conventional, digital and cone beam CT in vertical root fracture detection. *Iran Endod J*. 2011;6(1):15-20.
- Valizadeh S, Pournaliakbar H, Kiani L, Safi Y, Alibakhshi L. Evaluation of Visibility of Foreign Bodies in the Maxillofacial Region: Comparison of Computed Tomography, Cone Beam Computed Tomography, Ultrasound and Magnetic Resonance Imaging. *Iran J Radiol*. 2016;13(4):e37265.
- Valizadeh S, Alibakhshi L, Ghazizadeh Ahsaie M, Kazemi S, Vasegh Z. Diagnostic Accuracy of Cone Beam Computed Tomography in Identification of Foreign Bodies in the Head and Neck Region. *J Dent Sch* 2018;36(4):136-9.
- Nagarajappa AK, Dwivedi N, Tiwari R. Artifacts: The downturn of CBCT image. *J Int Soc Prev Community Dent*. 2015;5(6):440-5.
- Ferreira RI, Bahrami G, Isidor F, Wenzel A, Haiter-Neto F, Groppo FC. Detection of vertical root fractures by cone-beam computerized tomography in endodontically treated teeth with fiber-resin and titanium posts: an in vitro study. *Oral Surg Oral Med Oral Pathol Oral Radiol*. 2013;115(1):e49-57.
- Neves FS, Freitas DQ, Campos PS, Ekestubbe A, Lofthag-Hansen S. Evaluation of cone-beam computed tomography in the diagnosis of vertical root fractures: the influence of imaging modes and root canal materials. *J Endod*. 2014;40(10):1530-6.
- Lira de Farias Freitas AP, Cavalcanti YW, Costa FCM, Peixoto LR, Maia AMA, Rovaris K, et al. Assessment of artefacts produced by metal posts on CBCT images. *Int Endod J*. 2019;52(2):223-236.
- Diniz de Lima E, Lira de Farias Freitas AP, Mariz Suassuna FC, Sousa Melo SL, Bento PM, Pita de Melo D. Assessment of Cone-beam Computed Tomographic Artifacts from Different Intracanal Materials on Bicrooked Teeth. *J Endod*. 2019;45(2):209-213.e2.
- Dutra KL, Pachêco-Pereira C, Bortoluzzi EA, Flores-Mir C, Lagravère MO, Corrêa M. Influence of Intracanal Materials in Vertical Root Fracture Pathway Detection with Cone-beam Computed Tomography. *J Endod*. 2017;43(7):1170-5.
- Safi Y, Hosseinpour S, Aziz A, Bamedi M, Malekashari M, Vasegh Z. Effect of Amperage and Field of View on Detection of Vertical Root Fracture in Teeth with Intracanal Posts. *Iran Endod J*. 2016;11(3):202-7.
- Mohammadpour M, Bakhshalian N, Shahab S, Sadeghi S, Ataee M, Sarikhani S. Effect of titanium and stainless steel posts in detection of vertical root fractures using NewTom VG cone beam computed tomography system. *Imaging Sci Dent*. 2014;44(2):89-94.
- Estrela C, Bueno M, Silva J, Porto O, Leles C, Azevedo B. Effect of intracanal posts on dimensions of cone beam computed tomography images of endodontically treated teeth. *Dent Press Endod*. 2011;1(1):28-36.

### How to cite:

Valizadeh S, Karimi Nasab A, Iranparvar Alamdari M, Vasegh Z. Dimensional Distortion of Four Types of Intracanal Posts on CBCT Scans with Different Fields of View and Resolutions. *J Dent Sch* 2021;39(3):106-109.