

Clinical Management of Hypoplastic Amelogenesis Imperfecta in Pediatric Patients: A Case Report and Review of Literature

Sanaz Kamareh^a, Ghassem Ansari^{id}^b, Ali Asghar Soleymani^a, Romina Roodgarian^{id}^c, Atiye Yadegari^d

^aAssistant Professor, Dept. of Pediatric Dentistry, School of Dentistry, Shahid Beheshti University of Medical Sciences, Tehran, Iran

^bProfessor, Research Institute of Dental Sciences, Dept. of Pediatric Dentistry, School of Dentistry, Shahid Beheshti University of Medical Sciences, Tehran, Iran.

^cPostgraduate student, Dept. of Pediatric Dentistry, School of Dentistry, Shahid Beheshti University of Medical sciences, Tehran, Iran.

^dUndergraduate student, Student Research Committee, School of Dentistry, Shahid Beheshti University of Medical sciences, Tehran, Iran.

Correspondence to Romina Roodgarian (email: rominaroodgarian@gmail.com).

(Submitted: 1 February 2021 – Revised version received: 31 July 2021 – Accepted: 18 September 2021 – Published online: Autumn 2021)

Objectives Amelogenesis imperfecta (AI) refers to a group of hereditary disorders that affect the quality and/or quantity of dental enamel of both primary and permanent dentitions. Also, these patients may suffer from certain systemic disorders and other dental and skeletal defects or abnormalities.

Case: A 9-year-old female patient with hypoplastic type AI with unerupted maxillary first molars, and pulpal calcifications is reported. Her permanent anterior teeth were restored with composite veneer while the posterior teeth received stainless steel crowns.

Conclusion Hypoplastic type AI is a rather uncommon disorder. Early treatment of AI, not only prevents tooth wear, but also has a positive psychological impact on children. The possible association of AI with nephrocalcinosis can also be monitored through initial radiographic evidence of pulp stones.

Keywords Amelogenesis Imperfecta Local Hypoplastic Form; Nephrocalcinosis; Case Reports

Introduction

Enamel is the most mineralized tissue in humans and animals. Amelogenesis is a process through which the normal enamel is formed through a series of events to form a natural covering structure for the teeth. Under certain circumstances, this process is interrupted resulting in dysplasia, and in a more accurate term, hypoplasia. Certain defective genes are also known to be responsible for such massive changes in enamel formation, the result of which is a generalized discolored malformed dentition referred to as amelogenesis imperfecta (AI). This is therefore considered as a hereditary disorder that affects both the quality and/or quantity of dental enamel with effects on formation and maturation causing unusual small size, discoloration, and pits and grooves on the tooth surfaces.¹⁻² It may be passed as an autosomal dominant trait (the most common form) or autosomal recessive, X-linked, and even as a sporadic inheritance pattern.³

The disorder is well documented to affect both primary and permanent dentitions. This abnormality has been reported to cause various defects; thus producing different types of clinical forms including: thin (hypo-plastic), soft (hypo-calcified), rough, and stained enamel.⁴

Classification

Wiktop (1988)⁵ classified AI into 4 types: Type I: hypoplastic enamel, type II: hypomatured enamel, type III: hypocalcified enamel, and type IV: hypomatured - hypoplastic enamel with taurodontism. It has also been subdivided into 15 subtypes by phenotype and secondarily by the inheritance trait.⁶

Hypoplastic form of AI

Hypoplastic AI occurs mainly due to the defect in enamel matrix deposition. It is clinically characterized by thin enamel with yellowish-brown, rough or smooth, flat occlusal surfaces of posterior teeth due to attrition, and

with/without pits and grooves. The enamel is thin and well mineralized. Radiographs show thin enamel with normal radiodensity. Different types of hypoplastic AI are listed including generalized pitted, localized pitted, diffused smooth, diffused rough and enamel agenesis.^{7,8}

Syndromes associated with AI

AI has been commonly reported as an isolated finding⁹ but occasionally, AI cases are seen in association with other features as part of a known syndrome, for example, ameloncho-hypohidrotic syndrome, Morquio syndrome, trichodonto-osseous syndrome, AI with taurodontism, oculodonto-osseous dysplasia, epidermolysis bullosa hereditaria, cone-rod dystrophy, and AI and nephrocalcinosis syndrome.¹⁰

Nephrocalcinosis syndrome

Nephrocalcinosis syndrome is a rare syndrome associated with generalized hypoplastic AI, delayed permanent tooth eruption, intrapulpal calcifications, and nephrocalcinosis.^{11,12}

Nephrocalcinosis may cause renal impairment, but end-stage renal failure is rare to happen.¹³ Since nephrocalcinosis has no single cause, it should always be investigated with further cautionary measures.¹⁴ Patients who suffer from AI and nephrocalcinosis syndrome may have no renal complications until late childhood or early adulthood, with probability of recurrent urinary infections, pyelonephritis, or renal colic and the passage of a renal stone.¹¹

Other features associated with AI

AI cases may also show other signs of dental and skeletal defects or abnormalities, such as attrition, crown and root resorption, microdontia, taurodontism, delayed eruption, tooth impaction, dens in dente, pulp stones, anterior open bite, and tooth agenesis.^{15,16}

Treatment Options

In mixed dentition stage, the treatment is focused on preserving the tooth structure, maintaining tooth vitality, and

decreasing tooth sensitivity, while improving esthetics. However, rehabilitation in mixed dentition is rather complex, since the sequence of tooth eruption is different, and definitive treatment cannot be performed until complete eruption of permanent dentition. In addition, different treatment plans are recommended for unerupted teeth such as uncovering of soft tissue from the occlusal surface of the teeth with laser or surgery. In some cases, teeth cannot erupt with this treatment because roots are completed and the potential for eruption is lost; hence, in such situations, we can use orthodontic forces to accelerate or assist tooth eruption.¹⁷ For permanent molars, however, reconstruction of the crown using stainless steel crowns is often recommended as they can be sufficiently restored with stable vertical dimension. In addition, various types of cast onlays and composite resin restorations on occlusal surface of posterior teeth have also been recommended as a more conservative approach.^{18, 19} On the other hand, several treatment options have been reported for improvement of esthetics²⁰ including, direct or indirect composite veneers to mask the discolorations while re-constructing the crown morphology. Also, full-coverage adhesive composite resin or polycarbonate crowns have also been recommended for such cases.^{21, 22}

As the unpleasant aesthetic appearance is usually the chief complaint of AI patients, treatment plan is affected by several factors including age, socioeconomic status, and type and severity of the disorder.^{23, 24}

The purpose of this case presentation is to describe a patient with signs of hypoplastic AI, pulp stone and tooth impaction, with its potential relation to an enamel-renal syndrome, and to highlight the important role of dentists and pediatricians in recognizing this uncommon syndrome.

Case Report

A 9-year-old female was referred to the Department of Pediatric Dentistry, Dental School, Shahid Beheshti University of Medical Sciences, with the chief complaint of defective enamel appearance on her teeth and hypersensitivity of permanent teeth. The family history revealed that her father's teeth were also affected by the same enamel defects. She was born normally at full term after an uneventful pregnancy. Intraoral examination revealed yellow to yellowish-brown teeth with rough surfaces and reduced thickness, generalized spacing, and absence of contact points. Enamel alterations were generalized affecting both the present primary and permanent teeth (Figure 1). Clinical examination showed that she had no open bite. The orthopantomographic view revealed the structure of deciduous and permanent teeth being affected with a delayed pattern for eruption of both permanent maxillary first molars (Figure 2). There was no evidence of lower density of dentin compared with enamel. A clear layer of bone was present covering unerupted permanent maxillary molars even after complete root formation with no sign of movement. Intrapulpal

calcifications (pulp stones) were evident in all erupted and unerupted molars.

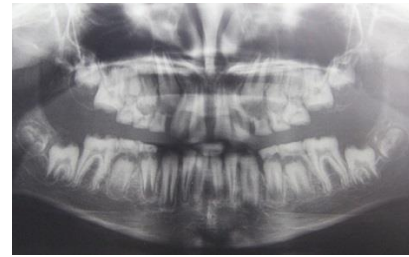


Figure 1- Orthopantomographic view

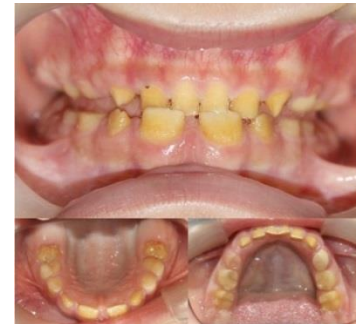

Figure 2- Pre-treatment intraoral view

Biochemical and endocrinological laboratory tests revealed no hormonal or calcium metabolism related deficiencies.

Because of hypoplastic enamel, pulp stones in permanent mandibular first molars and delayed eruption of permanent maxillary first molars, an association between AI and nephrocalcinosis was a potentially complicated issue in the current case, while a consultation with nephrologist revealed no renal pathology. However, parents were advised to have regular check-ups for possible onset of the disease at a later stage. Since the type of AI in our case was very similar to the type of AI seen in patients with nephrocalcinosis syndrome such as hypoplastic teeth, pulp stones, and delayed eruption time 11, she was referred to a nephrologist for a renal ultrasound scan. According to the final report, the renal ultrasound scan was normal, showing no sign of nephrocalcinosis.

The treatment was focused on the patient's main concerns, esthetics and hypersensitivity of permanent mandibular first molars. Due to the young age of the patient, composite veneer was an ideal treatment option for her anterior teeth; however, weak bond to the hypoplastic enamel was a major problem. To solve this problem, we used a rubber dam for all restorations, and isolation was fully observed. A universal adhesive (G-Premio Bond, GC, Japan) was also used in etch and rinse mode for more reliability. We also created tiny grooves on the tooth surface for further retention of restorations.

Full crown restorations were used for both maxillary and mandibular anterior teeth. A direct restoration technique was employed using a one-bottle universal adhesive (G-Premio Bond, GC Japan) compatible with all etching modes, to resolve hypersensitivity with composite resin (HerculiteXRV; Kerr, USA). These restorations provided functional rehabilitation as well. Similar reconstructions were also performed to restore the mandibular permanent

molars as they were extensively worn and had hypersensitivity. Six- and twelve-month recall sessions were scheduled to monitor the retention and stability of the treatments performed. Additionally, in the first follow-up session after six months, both mandibular permanent canines were restored with composite resin (Figure 3). The patient was motivated to improve her oral hygiene.

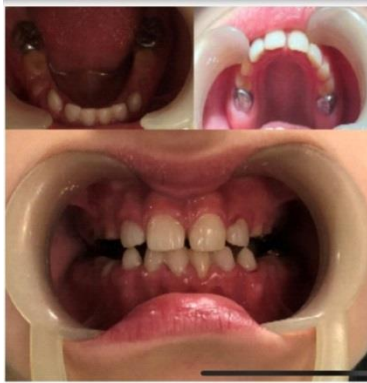

Figure 3- Post-treatment intraoral view

Discussion

AI is one of the most annoying hereditary disorders of teeth that affects normal enamel formation. Among all classes, hypoplastic type is the focus of this report.²⁵

Patients with hypoplastic AI have well mineralized enamel but the amount and thickness of enamel are reduced. Hypoplastic AI is further subdivided into rough and smooth types. In general, hypoplastic enamel appears rather thin while giving the appearance of yellowish-brown discoloration to the teeth. The texture of such teeth may be rough or smooth with a glossy surface.²⁵ The anatomical shape of the crown is changed to square shape with loss of contact points with the adjacent teeth. The rough pattern of hypoplastic type is characterized by thin, hard and rough surface of enamel. On radiographic analysis, a thin layer of enamel is seen with normal radio-density.^{26, 27}

Patients with hypoplastic AI have received various types of restorations including porcelain fused to metal or jacket crowns, composite restorations, stainless steel crowns, laminate, onlays, and even over-dentures.²⁸ Considering our patient's age, strip crowns were used to reshape the teeth with composite resin to restore the anterior teeth and reinstate aesthetics.

Temporary polycarbonate crowns can also be used as well as stainless steel crowns particularly in patients who have already lost vertical dimension to ensure optimal occlusion.²⁹ Stainless steel crowns were used for the current case in order to restore the tooth shape and structure while reestablishing the decreased vertical dimension and restoring the function of the posterior teeth. The age of the patient was a key factor in the decision to use stainless steel crowns.

In addition to the patient's esthetic demands, due to the observation of two notches on the incisal edge of lateral

incisors, composite veneer was recommended to prevent future tooth wear and universal adhesive was used to reduce tooth hypersensitivity. In order to improve adhesive bonding to enamel in patients with hypocalcified AI, another study utilized a deproteinization procedure with 5% sodium hypochlorite prior to adhesive cementation of directly manufactured resin-based composite strip crowns.³⁰ Also, due to the wear of mandibular molars which had incomplete eruption and severe hypersensitivity of exposed dentin, and in order to prevent further wear, stainless steel crowns were used for mandibular molar reconstruction, after fluoride therapy in the first visit.

Moreira et al.²⁰ treated an 11-year-old patient with hypoplastic AI with severe tooth hypersensitivity by the application of a universal adhesive for desensitization of teeth affected by AI. Resolution of tooth hypersensitivity was assessed using a visual analog scale during all reevaluations. The technique was effective for reducing tooth hypersensitivity. The result of their study was similar to the present study.

Luzzi et al.³¹ treated a 9-year-old patient with hypoplastic AI. They used direct restoration technique for anterior tooth reconstructions, similar to the present study. But their treatment plan for posterior teeth was different from ours. In their case, molars showed very excessive wear which interfered with proper isolation of the teeth for composite resin restoration. Before going ahead with the restoration, the posterior vertical height and the overjet had to be corrected, using a Frankel type orthodontic functional device. After a 10-month period of orthodontic therapy, an adequate molar extrusion was achieved that allowed the next restoration phase. Due to the enamel defect in these teeth, weak bonding of composite to defective enamel, and less importance of esthetics in molar restoration, stainless steel crown was used in the present study.

In addition, the patient was referred to an orthodontist for possible need for surgical exposure and forced eruption of unerupted maxillary molars.

Above all, it is necessary to set up a protocol for personal and professional oral hygiene including regular check-ups every 3 months, topical fluoride therapy for prophylaxis, and motivating the children for oral hygiene practice. A pediatric dentist must regularly follow such patients to ensure that the recommended procedures are being correctly and constantly applied.

In our patient, intrapulpal calcifications (pulp stones) were monitored in erupted and unerupted molars and advised were given for consultation with a urologist who ordered a renal ultra-sonography. No sign of nephrocalcinosis was detected by the specialist while the patient was advised to remain under regular supervision in case of any future onset of the disease at a later stage in life.

Conclusion

Hypoplastic type AI is a rather uncommon disorder;

however, its clinical and radiographic manifestations can cause psychological as well as functional dissatisfaction. Due to the risk of association with nephrocalcinosis, the initial radiographic signs of pulp stones should be precisely monitored.

Conflict of Interest

No Conflict of Interest Declared ■

References

- Bailleul-Forestier I, Molla M, Verloes A, Berdal A. The genetic basis of inherited anomalies of the teeth. *Clinical and molecular aspects of non-syndromic dental disorders*. *Eur J Med Genet*. 2008; 51: 273–91.
- Canger EM, Celenk P, Yenisey M, Odyakmaz SZ. Amelogenesis imperfecta, hypoplastic type associated with some dental abnormalities: a case report. *Braz Dent J*. 2010; 21: 170–4.
- Singh Sh, Chauhan R, Saxena T, Kumar N. Hypoplastic Smooth Autosomal Dominant Amelogenesis Imperfecta: A Case Report. *J Clin Diagn Res*. 2018; 6(1): 1–3.
- Kida M, Ariga T, Shirakawa T, Oguchi H and Sakiyama Y. Autosomal-dominant hypoplastic form of amelogenesis imperfecta caused by an enamel gene mutation at the exon-intron boundary. *J Dent Res*. 2002; 81:738–42.
- Witkop, C.J.J. Amelogenesis imperfecta, dentinogenesis imperfecta and dentin dysplasia revisited: Problems in classification. *J Oral Pathol Med*. 1988;17:547–53.
- Oliveira IK, Fonseca Jde F, do Amaral FL, Pecorari VG, Basting RT, França FM. Diagnosis and esthetic functional rehabilitation of a patient with amelogenesis imperfecta. *Quintessence Int*. 2011; 42(6): 463–9.
- Witkop CJ, Amelogenesis imperfecta, dentinogenesis imperfecta and dentin dysplasia revisited: problems in classification. *J Oral Pathol*. 1988; 17(9): 547–53.
- Rajendran R. Developmental disturbances of oral and paraoral structures. In: Rajendran R, Sivapathasundharam B, editors. *Shafer's Textbook of Oral Pathology*. 5th ed. New Delhi: Elsevier; 2007. p. 66–8.
- Neville BW, Damm DD, Allen CM, Bouquot JE. *Oral and Maxillofacial Pathology*. 3rd ed. Philadelphia: Elsevier; 2008.
- Ng FK, Messer LB: Dental management of amelogenesis imperfecta patients: a primer on genotype-phenotype correlations. *Pediatr Dent* 2009; 31(1): 20–30.
- Martelli-Júnior H, dos Santos Neto PE, de Aquino SN, de Oliveira Santos CC, Borges SP, Oliveira EA et al. Amelogenesis Imperfecta and Nephrocalcinosis Syndrome: A Case Report and Review of the Literature. *Nephron Physiol* 2011;118(3):62–5.
- Paula LM, Melo NS, Silva Guerra EN, Mestrinho DH, Acevedo AC. Case report of a rare syndrome associating amelogenesis imperfecta and nephrocalcinosis in a consanguineous family. *Arch Oral Biol*. 2005;50(2):237–42.
- Dellow EL, Harley KE, Unwin RJ, Wrong O, Winter GB, Parkins BJ. Amelogenesis imperfecta, nephrocalcinosis, and hypocalciuria syndrome in two siblings from a large family with consanguineous parents. *Nephrol Dial Transplant*. 1998 ;13(12):3193–6.
- Vervaeet BA, Verhulst A, D'Haese PC, De Broe ME: Nephrocalcinosis: new insights into mechanisms and consequences. *Nephrol Dial Transplant*. 2009; 24: 2030–5.
- Hoppe B, Kemper MJ: Diagnostic examination of the child with urolithiasis or nephrocalcinosis. *Pediatr Nephrol*. 2010; 25: 403–13.
- Poulsen S, Gjrup H, Haubek D, Haukali G, Hintze H, Lqvschall H, et al. Amelogenesis imperfecta - A systematic literature review of associated dental and oro-facial abnormalities and their impact on patients. *Acta Odontol Scand*. 2008;66(4):193–9.
- Koruyucu M, Bayram M, Tuna EB, Gencay K, Seymen F. Clinical findings and long-term managements of patients with amelogenesis imperfecta. *Eur J Dent*. 2014;8:546–52.
- Bedi R. The management of children with Amelogenesis imperfecta. *Rest Dent* 1989; 5(2):28–34.
- Harley KE, Ibbeston RJ. Dental anomalies: Are adhesive casting the solution? *Br Dent J*. 1993; 174(1):15–22.
- Moreira RF, Figueiredo RG, Oliveira HE, Fonseca AC, Miranda MS. Immediate Desensitization in Teeth Affected by Amelogenesis Imperfecta. *Braz Dent J*. 2016;27(3):359–62.
- Kwok-Tung L, King NM. The restorative management of Amelogenesis imperfecta in the mixed dentition. *J Clin Pediatr Dent* 2006; 31(2):130–5.
- Sapir S, Shapira J. Clinical solutions for developmental defects of enamel and dentin in children. *Pediatr Dent*. 2007; 29(4):330–6.
- Mehta DN, Shah J, Thakkar B. Amelogenesis imperfecta: Four case reports. *J Nat Sci Biol Med*. 2013; 4(2): 462–5.
- Chaudhary M, Dixit S, Singh A, Kunte S. Amelogenesis imperfecta: Report of a case and review of literature. *J Oral Maxillofac Pathol* 2009;13:70–77.
- Canger EM, Celenk P, Yenisey M, Odyakmaz SZ. Amelogenesis imperfecta, hypoplastic type associated with some dental abnormalities: a case report. *Braz Dent J*. 2010; 21(2): 170–4.
- Crawford PJ, Aldred M, Bloch-Zupan A. Amelogenesis imperfecta. *Orphanet J Rare Dis* 2007; 4: 7.
- Lam E (2009) Dental Anomalies. In: White SC, Pharooh MJ (Eds). *Oral Radiology: Principles and Interpretation*. Elsevier: India. pp: 303–337.
- Rajendran R (2009) Developmental disturbances of oral and paraoral structures. In: Rajendran R, Shivapathasundharam B (Eds). *Shafer's textbook of oral pathology*. New Delhi, India: Elsevier. pp: 3–80.
- Bouvier D, JP Duprez, D Bois. Rehabilitation of young patients with amelogenesis imperfecta: a report of two cases. *ASDC Journal of Dentistry for Children* 1996; 63: 443–7.
- Ergun G, Kaya BM, Egilmez F, Cekic-Nagas I. Functional and esthetic rehabilitation of a patient with amelogenesis imperfecta. *Journal of Canadian Dental Association* 2013; 79: d38.
- Luzzi V, Bossu M, Cavalle E, Ottolenghi L, Polimeni A. Case report: clinical management of hypoplastic amelogenesis imperfecta. *Eur J Paediatr Dent*. 2003;4(3):149–54.

How to cite: Kamareh S, Ansari G, Soleymani AS, Roodgarian R, Yadegari A. Clinical Management of Hypoplastic Amelogenesis Imperfecta in Pediatric Patients: A Case Report and Review of Literature. *J Dent Sch* 2020;38(4):169-171.