

# Report of an Uncommon Case of Huge Neurofibroma in the Buccal Mucosa

Fatemeh Mashhadiabbas <sup>a</sup>, Rooholla Safarpour <sup>b</sup>, Maryam Mohammadalizadeh Chafjiri <sup>b</sup>

<sup>a</sup>Associate Professor, Department of Oral & Maxillofacial Pathology, School of Dentistry, Shahid Beheshti University of Medical Sciences, Tehran, Iran.

<sup>b</sup>Postgraduate Student, Department of Oral & Maxillofacial Pathology, School of Dentistry, Shahid Beheshti University of Medical Sciences, Tehran, Iran..

Correspondence to Maryam Mohammadalizadeh Chafjiri (email: dr.maryam.malizadeh@sbmu.ac.ir).

(Submitted: 16 January 2021 – Revised version received: 17 February 2021 – Accepted: 3 April 2021 – Published online: Summer 2021)

**Objectives** Neurofibroma (solitary or multiple) is a benign neurogenic jaw tumor with peripheral nerve origin. It is commonly found in the skin and the head and neck region but its occurrence in the oral cavity is rare.

**Case:** This report presents a case of huge solitary neurofibroma in the maxillary vestibular mucosa in a 60-year-old male without any medical or family history of neurofibromatosis type 1. The diagnosis was made based on histopathological findings and IHC staining for the S-100 protein. No recurrence was noted at the 6-month follow-up after surgical excision of the lesion.

**Conclusion** We reported a case of neurofibroma, which is a relatively rare benign tumor of the oral cavity, in the buccal mucosa in an elderly man based on histopathological and immunohistochemical findings. The propensity of neurofibromas to progress to neurofibromatosis or the primary disease undergoing malignant transformation (6-29%) has been reported in the literature. Therefore, a close follow-up of patients presenting initially only with neurofibroma is necessary.

**Keywords** Diagnosis; Neurofibroma; Neurofibromatoses; Mouth Mucosa

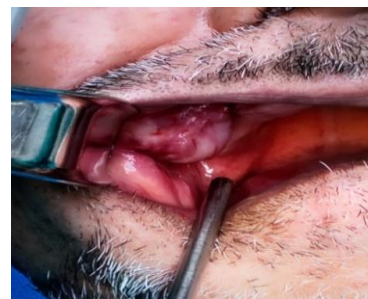## Introduction

Neurofibroma is a benign tumor with peripheral nerve origin composed of Schwann cells admixed with variable numbers of perineurial-like cells, transitional cells, and fibroblasts. Neurofibromas have a higher prevalence in the skin and head and neck region but are rarely detected in the oral cavity.<sup>1-7</sup> They may manifest in patients with or without hereditary neurofibromatosis.<sup>8</sup> Approximately 4% to 7% of patients with neurofibromatosis display oral manifestations.<sup>9</sup> On the other hand, 20% to 60% of oral neurofibromas are associated with neurofibromatosis.<sup>10</sup> Neurofibromas are most common in the third decade of life; however, their occurrence has also been reported in patients between 10 months and 70 years of age. Controversy exists regarding the sex predilection of neurofibromas.<sup>11</sup> Intra-oral neurofibromas may present as a sessile nodule or a pedunculated mass that vary in size from small to large. However, they are slow-growing lesions that are often painless but may be painful due to pressure effects.<sup>7, 12</sup> The most common sites of involvement include the tongue and buccal mucosa. However, they may occur at any site like the palate (soft or hard) or floor of the mouth.<sup>12, 13</sup> On rare occasions, the tumor can arise centrally within bone, where it may produce a well-demarcated or poorly defined unilocular or multilocular radiolucency.<sup>7</sup> On rare occasions, intraosseous location has been described in the mandible.<sup>14</sup> Herein, we report a case of huge neurofibroma of the right-side buccal mucosa without syndromic neurofibromatosis I in an elderly male patient.

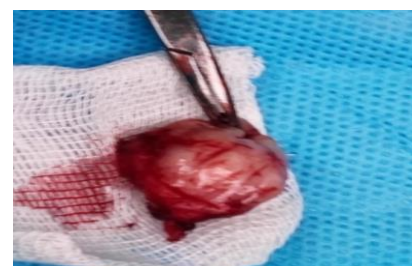## Case Report

A 60-year-old male patient was referred to the Department of Oral and Maxillofacial Pathology, School of Dentistry, Shahid Beheshti University of Medical Sciences, Tehran, Iran, with the chief complaint of a swelling in his right buccal mucosa since one year ago. The patient did not

complain of any difficulty in swallowing, chewing or breathing. No history of pain, discharge, or bleeding was associated with the swelling. He had complete maxillary denture and no adverse oral habit. On physical examination, the patient appeared healthy. Family history did not show a similar complaint in immediate or distant relatives. Intra-oral examination revealed the presence of a well-circumscribed, pale pink, oval, single, soft to firm, sessile, non-tender, slightly mobile nodule, measuring about 3.0 cm × 2.0 cm on the maxillary vestibular mucosa which extended to the buccal mucosa. The surface of the lesion was lobulated, and the overlying mucosa was non-ulcerated (Figure 1). Based on clinical examination and history given by the patient, the growth was thought to be a benign soft-tissue neoplasm. Under local anesthesia, excisional biopsy of the lesion was performed and it was submitted for histopathological examination (Figure 2).



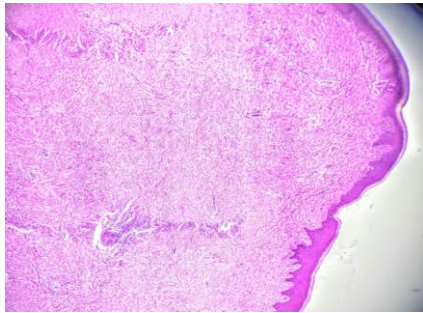
**Figure 1-** Intraoral view showing a large nodule in the maxillary vestibule that extended to buccal mucosa.



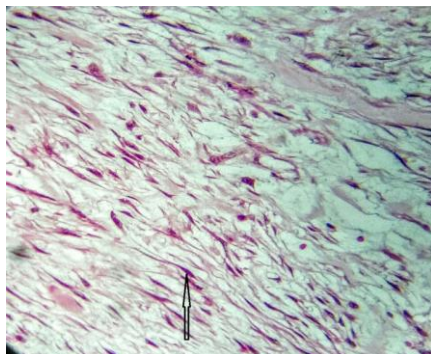
**Figure 2-** Tissue excised for biopsy.

Histopathological sections showed a polypoid mass composed of spindle to polygonal cells with wavy nuclei in a dense to myxoid matrix, which invaded the striated muscle and adipose tissue in some areas. Few mast cells, scattered infiltration of chronic inflammatory cells, hemorrhage and nerve bundles were also seen. The lesion was covered with hyperplastic to thin parakeratinized stratified squamous epithelium. There was no evidence of malignancy (Figures 3 and 4).

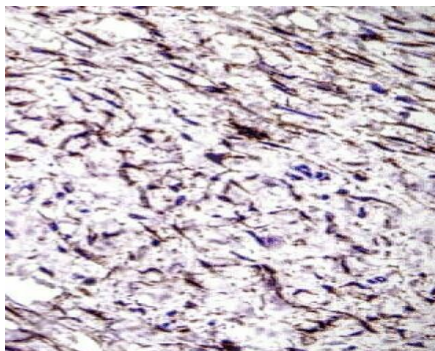
For precise diagnosis, immunohistochemical (IHC) staining for S-100 was performed, which was positive (Figure 5).



**Figure 3- Histopathological findings: cellular matrix containing fibroblasts, Schwann cells, and collagen (×100 magnification, H&E).**



**Figure 4- Spindle-shaped cells with wavy nuclei(arrow) (×400 magnification, H&E)**



**Figure 5- Immunohistochemical staining shows scattered S-100 protein positive immunoreactivity (IHC,original magnification ×400).**

There was no relevant family history and no evidence of neurofibromatosis, such as cafe-au-lait spots, Lisch nodules, or axillary freckling. The patient showed normal physical and mental development. Due to the clinical, histological, and immunohistochemical findings, the final diagnosis of neurofibroma was made. No recurrence was

seen in the follow-up session 6 months later.

## Discussion

Neurofibroma (solitary or multiple) is a benign neurogenic jaw tumor. Schwannoma (also known as neurinoma or neurilemoma) and neuroma (amputation neuroma or traumatic neuroma) are other types of neurogenic tumors.<sup>15</sup> Neurofibromas are peripheral nerve sheath tumors that consist of Schwann cells, perineural cells, and myofibroblasts.<sup>22</sup> The etiology of solitary neurofibroma is unknown. It is assumed that solitary neurofibroma is a hyperplastic hamartomatous malformation rather than a neoplastic disease. Solitary tumors are most common in young adults<sup>16</sup>, and in the third decade of life.<sup>11</sup> However, controversy exists regarding their sex predilection.<sup>12</sup> Disability or immunodeficiency are not known as predisposing factors.<sup>11</sup> Multiple neurofibromas are commonly observed as part of neurofibromatosis type 1 syndrome or type III multiple endocrine neoplasia syndrome.<sup>17-21</sup> Solitary intraoral neurofibroma not accompanied by neurofibromatosis type 1 is very rare in the oral cavity.<sup>17, 19</sup> It was first described by Bruce in 1954.<sup>21</sup> Clinically, it manifests as a submucosal, slow growing, soft, sessile, and usually painless lesion that may vary in size from a small nodule to a large mass.<sup>19</sup> The tumors range from 0.1 to 2.0 cm in maximum dimension (mean of 0.5 cm).<sup>23</sup> Our patient was a 60-year-old man with a swelling on his buccal mucosa, which is in accordance with the literature as this is an uncommon intraoral site for the occurrence of neurofibroma not associated with neurofibromatosis. The size of lesion was 3×2×1 cm which was larger than the commonly reported range. This case was unique as the presentation of the lesion was sporadic without any associated family history. Since sporadic neurofibromas do not cause unusual symptoms that can be distinguished from other tumors such as the ganglion cyst, giant cell tumor of the tendon sheath, epidermal inclusion cyst, lipoma, neuroma, fibroma, and glomus tumor, the differential diagnosis is necessary.<sup>24</sup> However, in our case, based on the clinical examination and history given by the patient, the growth was thought to be a benign soft tissue neoplasm.

Intraoral lesions of neural tissues mainly originate from the branches of the fifth, seventh, and rarely ninth cranial nerves.<sup>21</sup> In our case, it involved the maxillary branch of the fifth nerve.

A minority of patients have reported dysphagia, dysphonia, or respiratory difficulty, which correlated with tumors affecting the base of the tongue.<sup>23</sup> But in our case, because the location of the lesion was in the buccal mucosa, the patient did not complain of any difficulty in swallowing, chewing or respiration.

Histological examination is necessary for a definitive diagnosis, and IHC staining is important.<sup>24</sup> Histologically, most neurofibromas are well-circumscribed but non-encapsulated tumors and consist of elongated fibroblasts

with bent, wavy, and serpentine nuclei separated by abundant fine collagen fibers. Mast cells are typically found and contribute to fibroblastic proliferation and growth of neurofibroma.<sup>7</sup> In our case, we found a polypoid mass composed of spindle to polygonal cells with wavy nuclei in a dense to myxoid matrix with few mast cells and nerve bundles. Sporadic neurofibromas may become malignant, although it is extremely infrequent. Malignant transformation is commonly seen with multiple neurofibromas and those associated with von Recklinghausen disease (neurofibromatosis type 1) or MEN-III syndrome.<sup>19, 20, 25, 26</sup>

Although recurrence of solitary neurofibroma is rare, but it has been reported that there is a higher rate of recurrence in the head and neck region. Also, tumors which have been excised several times have a higher risk for malignancy.<sup>27</sup> Pain, neurological symptoms, large size, and/or functional disability are indications for surgical removal. However, most benign nerve sheath tumors are asymptomatic.<sup>24</sup> The preferred treatment option for neurofibroma is surgical removal. However, the tumor size and its vascularization can often affect the surgical procedure. The preoperative

histological evidence can influence the surgical approach being conservative or aggressive.<sup>28</sup> Our patient was treated by excisional biopsy which was in accordance with the treatment protocol for solitary neurofibroma.<sup>18, 20, 27</sup> No signs of recurrence or neurofibromatosis type 1 were noted over a follow-up period of 6 months.

## Conclusion

We reported a case of neurofibroma, which is a relatively rare benign tumor of the oral cavity, in the buccal mucosa in an elderly man based on histopathological and IHC findings. The propensity of neurofibromas to progress to neurofibromatosis or the primary disease undergoing malignant transformation (6-29%) has been reported in the literature.<sup>14</sup> Therefore, close follow-up of patients presenting initially only with neurofibroma is necessary.

## Conflict of Interest

No Conflict of Interest Declared ■

## References

- do Nascimento GJ, de Albuquerque Pires Rocha D, Galvao HC, de Lisboa Lopes Costa A, de Souza LB. A 38-year review of oral schwannomas and neurofibromas in a Brazilian population: clinical, histopathological and immunohistochemical study. *Clin Oral Investig* 2011;15(3):329-35.
- Campos MS, Fontes A, Marocchio LS, Nunes FD, de Sousa SC. Clinicopathologic and immunohistochemical features of oral neurofibroma. *Acta Odontol Scand* 2012;70(6):577-82.
- Chen SY, Miller AS. Neurofibroma and schwannoma of the oral cavity. A clinical and ultrastructural study. *Oral Surg Oral Med Oral Pathol*. 1979;47(6):522-8.
- Jones AV, Franklin CD. An analysis of oral and maxillofacial pathology found in adults over a 30-year period. *J Oral Pathol Med* 2006; 35(7):392-401.
- Salla JT, Johann AC, Garcia BG, Aguiar MC, Mesquita RA. Retrospective analysis of oral peripheral nerve sheath tumors in Brazilians. *Braz Oral Res* 2009; 23(1):43-8.
- Cherrick HM, Eversole LR. Benign neural sheath neoplasm of the oral cavity: report of thirty-seven cases. *Oral Surgery Oral Med Oral Pathol* 1971;32(6):900-9.
- Textbook Neville BW, Damm DD, Allen CM, Bouquot JE. *Oral and Maxillofacial Pathology*. 4th Ed. Philadelphia: W.B. Saunders Co., 2016; Chap 12:494.
- Hillier JC, Moskovic E. The soft tissue manifestations of neurofibromatosis type 1. *Clin Radiol* 2005;60:960-7.
- Narwal A, Saxena S, Rathod V, Bansal P. Intraoral solitary neurofibroma in an infant. *J Oral MaxilloFac Pathol* 2008;12(2):75-8.
- Bekisz O, Darimont F, Rompen EH. Diffuse but unilateral gingival enlargement associated with von Recklinghausen neurofibromatosis: a case report. *J Clin Periodontol* 2000;27(5):361-5.
- Gomez-Oliveira G, Fernandez-Alba Luengo J, Martin-Sastre R, Patino-Seijas B, Lopez-Cedrun-Cembranos JL. Plexiform neurofibroma of the cheek mucosa. A case report. *Med Oral* 2004;9(3):263-7.
- Sinha R, Paul R, Sen I, Sikdar B. A solitary huge neurofibroma of the soft palate. *J Laryngol Otol* 2002;116(8):637-8.
- Dongjie L, /niu K, Yuan T, Zhu W, Yin W. A rare case report of a solitary neurofibroma in postcricoid region of hypopharynx. *Medicine (Baltimore)* 2021;100(1):e24017.
- Vivek N, Manikandhan R, James PC, Rajeev R. Solitary intraosseous neurofibroma of mandible. *Indian J Dent Res* 2006;17(3):135-8.
- Richards D. Neurofibroma of the oral cavity. *Br J Oral Surg*. 1983;21(1):36-43.
- Ait Ali H, Zerouh B, Egyir Ebo U, Serji B, Elharroudi T. Solitary and complicated neurofibroma of small Bowel: A case report. *Int J Surg Case Rep* 2021;78:126-9.
- Kodiya AM, Ngamdu YB, Sandabe MB, Isa A, GarandawaHI. Solitary isolated neurofibroma of the soft palate. *J Surg Case Rep* 2013; 2013(1):rjs029.
- Meyer U, Kleinheinz J, Handschel J, Kruse-Losler B, Weingart D, Joos U. Oral findings in three different groups of immunocompromised patients. *J Oral Pathol Med* 2000;29(4):153-8.
- Ohno J, Iwahashi T, Ozasa R, Okamura K, Taniguchi K. Solitary neurofibroma of the gingiva with prominent differentiation of Meissner bodies: a case report. *Diagn Pathol* 2010;5:61.
- Depprich, Rita, et al. Solitary submucous neurofibroma of the mandible: review of the literature and report of a rare case. *Head & Face Medicine*, 2009, 5.1: 1-4.
- Oliveira GG, Luengo JFA, Sastre RM, Seijas BP, Cembranos JLLC. Plexiform neurofibroma of the cheek mucosa: a case report. *Med Oral* 2004;9(3):263-7.
- Thompson LDR, Koh SS, Lau SK. Sporadic Neurofibroma of the Tongue Unassociated with Neurofibromatosis Type I: A Clinicopathologic Study of Ten Cases. *Head Neck Pathol* 2020;14(2):374-80.
- Kim KS, Lee DG, Lee DH, Hwang JH, Lee SY. Slowly growing solitary neurofibroma of the thumb: A case report. *Medicine (Baltimore)* 2021;100(2):e23611.
- Suramya S, Shashikumar P, Shreeshyla HS, Sheela Kumar G. Solitary plexiform neurofibroma of the gingiva: unique presentation in the oral cavity. *J Clin Diagn Res* 2013;7(9):2090-2.
- Maruyama M, Fushiki H, Watanabe Y. Solitary neurofibroma of the floor of the mouth: a case report. *Case Rep Otolaryngol*

2011;2011:967896.

26. Thompson LDR, Koh SS, Lau SK. Sporadic Neurofibroma of the Tongue Unassociated with Neurofibromatosis Type I: A Clinicopathologic Study of Ten Cases. *Head Neck Pathol* 2020;14(2):374-80.

27. Kallen ME, Hornick JL. The 2020 WHO Classification: What's new in soft tissue tumor pathology. *Am J Surg Pathol* 2021;45(1):e1-

23.

28. Al-Omran MK, Al-Khamis ANK, Malik AK. Solitary neurofibroma of the floor of the mouth. *Neurosciences* 2006;11(1):5-55.

29. Bharath TS, Krishna YR, Nalabolu GR, Pasupuleti S, Surapaneni S, Ganta SB. Neurofibroma of the palate. *Case Rep Dent* 2014; 2014:898505.

---

**How to cite:**

Mashhadiabbas F, Safarpour R, Mohammadalizadeh Chafjiri M. Report of an Uncommon Case of Huge Neurofibroma in the Buccal Mucosa. *J Dent Sch* 2020;38(3):130-133.