

Evaluation of Pulp Tissue Following Direct Pulp Capping with Propolis versus Calcium Hydroxide: A Clinical Trial

Zohreh Ahangari ^a, Fatemeh Mashhadiabbas ^b, Mojgan Feli ^c, Zeinab Jafari ^d, ⁵Saeede Zadsirjan ^a

^aProfessor, Dept. of Endodontics, School of Dentistry, Shahid Beheshti University of Medical Sciences, Tehran, Iran.

^bAssociate Professor, Dept. of Oral and Maxillofacial Pathology, School of Dentistry, Shahid Beheshti University of Medical Sciences, Tehran, Iran.

^cPostgraduate student of Endodontics, Dept. of Endodontics, School of Dentistry, Shahid Beheshti University of Medical Sciences, Tehran, Iran.

^dEndodontist

^eAssistant Professor, Dept. of Endodontics, School of Dentistry, Shahid Beheshti University of Medical Sciences, Tehran, Iran.

Correspondence to Saeede Zadsirjan (email: S_sirjani@yahoo.com).

(Submitted: 23 November 2020 – Revised version received: 12 July 2021 – Accepted: 28 July 2021 – Published online: Autumn 2021)

Objectives Direct pulp capping may result in formation of a dentinal bridge and preservation of pulp vitality. This randomized controlled clinical trial sought to histologically assess and compare pulp tissue following pulp capping with propolis and calcium hydroxide.

Methods In A cavity was prepared at the center of the occlusal surface of 10 third molars scheduled for extraction by using a cylindrical bur. The pulp chamber was exposed with a round bur. Samples were randomly divided into two groups (5 teeth in each group). The first group underwent direct pulp capping with propolis and the second group with calcium hydroxide. Auto-polymerizing glass ionomer was then applied to seal the cavity. The teeth were extracted after 45 days, and histologically evaluated. The obtained data were analyzed using the Fisher's exact test.

Results The quality ($P=0.048$) and quantity ($P=0.008$) of dentinal bridge were significantly different between the two groups. Propolis resulted in formation of a continuous dentinal bridge with irregular tubular dentin; whereas, calcium hydroxide resulted in formation of osteodentin (low quality dentin).

Conclusion Propolis induced the formation of tubular dentin with higher quality compared with calcium hydroxide.

Keywords Calcium Hydroxide; Dental Pulp Capping; Propolis

Introduction

Vital pulp therapy is used for preservation of pulp tissue in case of its accidental exposure as a result of trauma. This treatment aims at induction of reparative dentin formation to preserve tooth vitality.^{1,2}

Dentin is considered a physiological barrier that protects the dental pulp from direct interaction with potential exogenous tissue-damaging stimuli. The thickness of the dentin barrier can be increased via formation of tertiary dentin in response to different harmful stimuli.³ At its periphery, dental pulp hosts the cells responsible for dentinogenesis, namely odontoblasts. Severe external stimuli, such as deep carious lesions, can trigger and destroy these cells; consequently, the progenitor cells are recruited, which may differentiate into odontoblast-like cells.⁴

Calcium hydroxide has been recommended for years as the standard pulp capping material due to its compatibility with pulp tissue and optimal antibacterial properties.⁵ It was previously believed that calcium hydroxide induces the reparative dentin formation but new theories state otherwise. Based on a recent study, calcium hydroxide cannot induce dentin formation; its antimicrobial activity is temporary, it lacks optimal physical properties, is highly soluble and results in microleakage.⁶ Several studies have histologically assessed the human dental pulp following direct pulp capping with different materials.^{7,8} Mali et al. reported that Biodentine may be considered as the best alternative to mineral trioxide aggregate for pulp capping in human teeth.⁷ Parolia et al. concluded that the pulp tissue response to propolis as a pulp capping agent was comparable to mineral trioxide aggregate and Dycal.⁸

Propolis, which is extracted from the honey beehives, is a resinous mixture collected by honeybees from botanical sources and is considered as an herbal resin. Propolis is made

of wax, resin, fatty acids, and amino acids.^{9,10} It has more than 180 constituents. Propolis is rich in flavonoids and apigenin. Quercetin, pinostrobin, pinocembrin, luteolin, kaempferol and galangin are among its other constituents. It possesses anti-inflammatory, anti-spastic, anti-allergic, anti-oxidant and anti-mutagenic properties (10-12). Another major constituent of propolis is caffeic acid phenethyl ester which has anti-cancer and anti-inflammatory properties.¹³⁻¹⁶ The success rate of direct pulp capping is variable based on the technique and type of material used.^{17,18} Many studies have evaluated the efficacy of different pulp capping agents with respect to pulp vitality, radiographic findings, dentinal bridge formation, inflammation, and presence of bacteria.¹⁸⁻²⁰ However, histological analysis is the gold standard for assessment of dental pulp status and dentinal bridge formation.²¹

This randomized controlled clinical trial sought to histologically assess and compare dental pulp response following pulp capping with calcium hydroxide and propolis.

Methods and Materials

The propolis used in this study was the Azerbaijan's brown propolis. It was primarily solid and was diced into small pieces; 10 g of it was poured into an Erlenmeyer flask containing 100 cc of 96° ethanol. The Erlenmeyer flask was then placed in a shaker for 24 hours. The undissolved particles were removed by filtration using a paper filter (CA-20/25). Another 100 cc of alcohol was added to the remaining propolis solution, and the mixture was placed in the shaker for another 24 hours. This step was repeated three times, and the final solution was transferred to a vacuum distiller apparatus to obtain the ethanolic extract of propolis. This extract had resinous consistency and the pH of propolis

was 5.38 as measured by a pH meter (3310; Jenway, England).

This randomized controlled clinical trial was conducted on 10 third molars of patients presenting to the Maxillofacial Surgery Department of School of Dentistry, Shahid Beheshti University of Medical Sciences to extract their teeth. Patients were 20-28 years old. The Ethics Committee of Shahid Beheshti Medical University approved the protocol of this study and it was also registered in the Iranian Registry of Clinical Trials (IRCT 2013031712832N1). The study process and potential complications were thoroughly explained to the patients and written informed consent was obtained from them. The first author (Z.S) performed the diagnostic tests and enrolled the participants. All teeth were evaluated clinically and radiographically (SOREDEX™ DIGORA™ Optime Intraoral X-ray, Germany) to ensure absence of traumatic, carious, and periapical or periodontal lesions. Pulp vitality was evaluated by the cold (Roeko EndoFrost; Coltene Whaledent, Langenau, Germany) and heat (heated gutta-percha applied on the tooth surface) tests as well as electric pulp test (Sybron Endo Vitality Scanner model 2006; Kerr, Glendora, CA, USA). All the teeth were vital and had closed apices. The patients were assigned to the test and control groups by sequential randomized sampling and each patient received a random number to be assigned to one of the two groups. One of the investigators (A.Z) allocated the patients randomly into one of the two arms by drawing a sealed, opaque envelope. Each patient was randomly given a sealed envelope containing a card displaying calcium hydroxide (group 1) or propolis (group 2). The data collection was performed by a single investigator (F.M) who remained masked about the type of pulp capping agent used. The course of study was three months.

Another investigator (J.Z) performed the clinical procedures. The teeth were disinfected with 0.2% chlorhexidine (Iran Najo, Tehran, Iran). Local anesthesia was induced by using 2% lidocaine with 1:80,000 epinephrine (Persocaine, Darupakhsh, Tehran, Iran), rubber dam was placed, and an occlusal cavity was prepared using a sterile cylindrical diamond bur and high speed hand piece with air-water spray. The prepared cavity measured 3-3.5 mm in depth, 4-4.5 mm in mesiodistal width, and 3-3.5 mm in buccolingual width. The mentioned measurements were made by a periodontal probe. The pulp chamber was exposed at the center of the chamber roof using a round diamond bur (ISO 010 Diamond-Horico) with air-water spray. Hemostasis was achieved with mild pressure of sterile cotton pellet dipped in saline at the exposure site. The exposure site was then completely dried with a dry cotton ball. This procedure was repeated until achieving complete hemostasis. If hemostasis was not achieved after 5 minutes of using a cotton ball, the tooth would be excluded from the study. The teeth were randomly divided into two groups of 5 samples each. The exposure site in group 1 was covered with pure calcium hydroxide mixed with sterile water (to become packable) (Cinabartar, Tehran, Iran). In the propolis group, resinous

propolis delivered by a Dycal applicator was used for pulp capping. The teeth were restored with glass ionomer (GC Gold Label Universal Restoration II; GC Corporation, Tokyo, Japan). All teeth were followed up clinically during the study period (24 hours, 15 days, 30 days, 45 days) before extraction. The patients were asked about any pain sensation. Clinical examination included sensitivity testing to percussion and palpation as well as pulp vitality tests, and the results were recorded. The teeth had no sign or symptoms and were extracted 45 days later. The roots were horizontally sectioned by a cutting machine (Non-stop; Bego, Germany) and diamond disc (Gota) in half to allow the penetration of fixator. The samples were fixed in 10% formalin for 24 hours and decalcified in 10% formic acid for 7 weeks. Next, 4- μ m sections of each tooth were made in longitudinal direction at the defect site (location of calcium hydroxide and propolis). A minimum of 3 slides with pulp that could be examined were prepared by the Leica microtome machine and placed on glass slides and stained routinely (H&E staining). They were then histologically examined under a light microscope (CH2; Olympus, Japan) at the defect site at x40, x100, and x400 magnifications in blind manner. Presence of inflammation, its severity, formation of dentinal bridge, its quality and quantity, and presence of odontoblast-like cells were all assessed. This process was similar for each patient.

Inflammation. The following scoring system was used for the severity of inflammation at x400 magnification:

Score 0: No inflammation	Inflammatory cells <10%
Score 1: Mild inflammation	Inflammatory cells= 10-30%
Score 2: Moderate inflammation	Inflammatory cells= 30-50%
Score 3: Severe inflammation	Inflammatory cells >50%

Quantity. The following scoring system was used for the quantity of the formed dentinal bridge at x100 magnification:

- 0: No dentinal bridge
- 1: Continuous dentinal bridge
- 2: Interrupted dentinal bridge

Quality. The following scoring system was used for the quality of the formed dentinal bridge:

- 1: Tubular dentin
- 2: Osteodentin

Odontoblasts. The following scoring system was used for presence of odontoblast-like cells:

- 0: Absence of odontoblast-like cells
- 1: Presence of odontoblast-like cells

The obtained data were analyzed using the Fisher's exact test. The analyses were carried out using SPSS version 24.0 (IBM Corp., Armonk, NY, USA). The level of significance was set at $\alpha < 0.05$.

Results

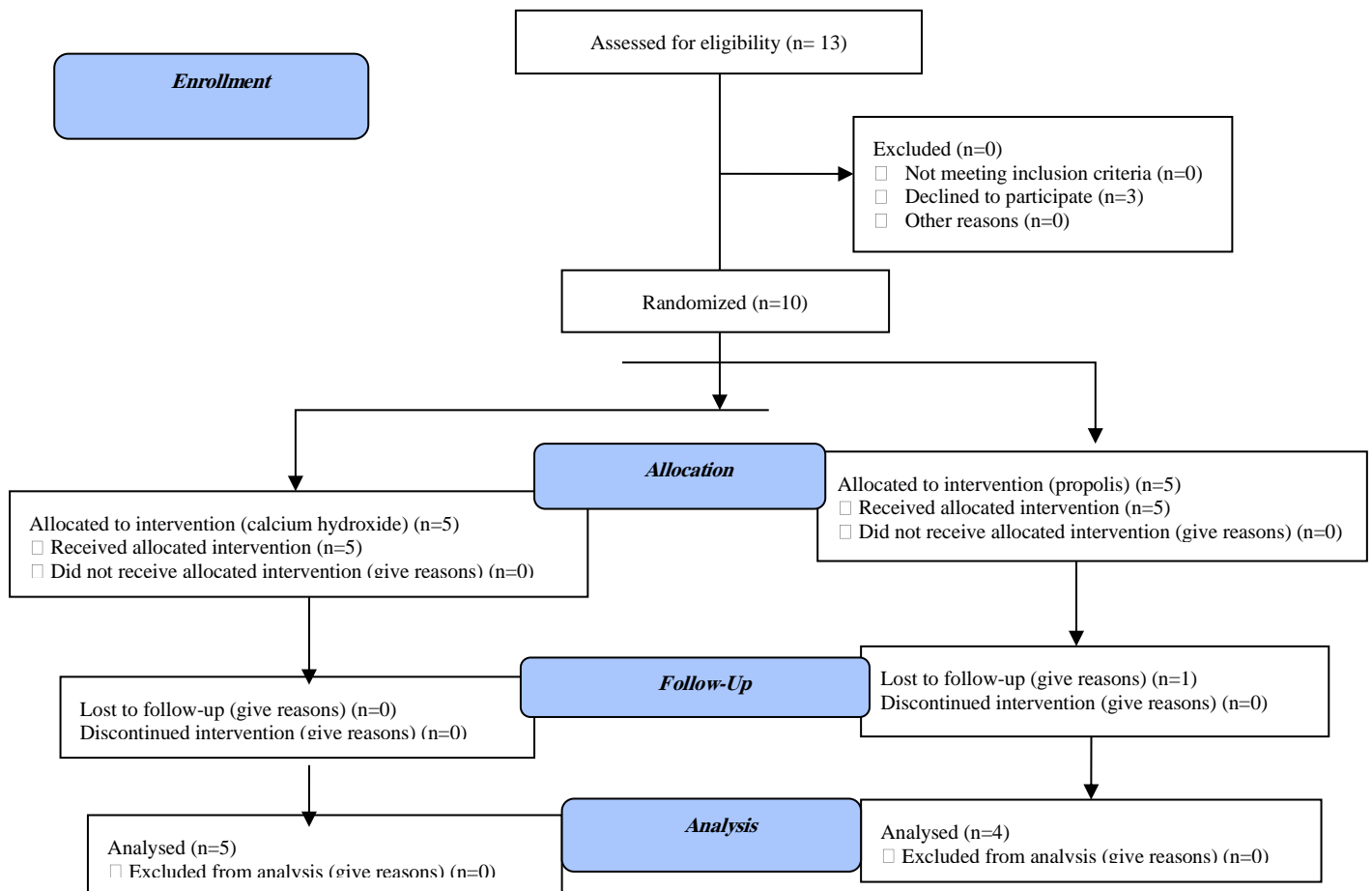
A total of 10 third molars from 10 patients were randomly capped with propolis or calcium hydroxide as a pulp capping agent. One of the patients from the propolis group was lost to follow-up (Fig. 1).

Quality of the newly formed dentin:

In terms of quality, two completely different types of dentin were observed. The first type was completely irregular with spaces filled with loose connective tissue and blood vessels with a bone-like appearance (osteodentin). The second type was smooth dentin containing irregular tubules with no voids or connective tissue (irregular tubular dentin) with a quality equal to that of primary dentin. In the propolis group, all five

samples (100%) demonstrated irregular tubular dentin (Fig. 2A). In the calcium hydroxide group, osteodentin formed in two samples (40%) (Fig. 2B), dentinal bridge did not form in two other samples (40%), and in the remaining one, irregular tubular dentin was observed. The difference in this regard between the two groups was statistically significant ($P=0.048$).

CONSORT
TRANSPARENT REPORTING OF TRIALS
CONSORT 2010 Flow Diagram

**Quantity of the newly formed dentin:**

In the propolis group, the newly formed dentinal bridge was continuous in all five samples (100%); while, in the calcium hydroxide group, it was interrupted in three (60%) and did not form in the remaining two samples. The difference in this regard was statistically significant between the two groups ($P=0.008$).

Severity of inflammation:

In the propolis group, inflammation was less than 10% in five samples (100%); whereas, in the calcium hydroxide group, pulp necrosis (inflammation more than 50%) was detected in two samples (40%) (Fig. 2C) and inflammation less than 10% and between 10-30% was detected in one (20%) and two (40%) samples, respectively. The difference was statistically significant ($P=0.048$).

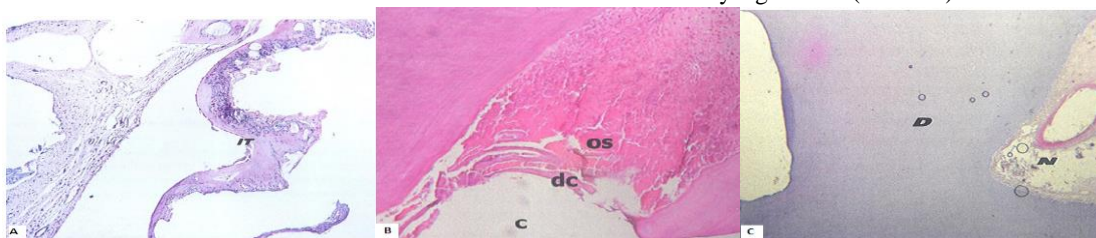


Figure 2- (A) Propolis group: Irregular tubular dentin (IT); (B) calcium hydroxide group: cavity (C), dentin chips (DC), osteodentin (OS); (C) calcium hydroxide group: necrotic pulp (N), dentin (D)

Presence of odontoblast-like cells:

In the propolis group, odontoblast-like cells were present in all samples (100%); while these cells were noticed in three

samples (60%) in the calcium hydroxide group. The difference in this respect between the two groups was not statistically significant ($P=0.44$, Table 1).

Table 1- Histopathological findings

Variables	Quality of newly formed dentin			Quantity of newly formed dentin			Severity of inflammation			Presence of odontoblast-like cells	
	No bridge	Osteodentin	Tubular	No dentin	Incomplete dentin	Complete dentin	Less than 10%	10-30%	More than 50%	Absent	Present
Propolis	0	0	4 (100%)	0	0	4 (100%)	4 (100%)	0	0	0	4 (100%)
Calcium hydroxide	2 (40%)	2 (40%)	1 (20%)	2 (40%)	3 (60%)	0	1 (20%)	2 (40%)	2 (40%)	2 (40%)	3 (60%)
P-value		0.048			0.008			0.048			0.44

Discussion

In the present study, propolis was compared with calcium hydroxide, which is the most commonly used dental material for vital pulp capping. Propolis showed superior properties compared with calcium hydroxide in terms of not causing inflammation, quantity of newly formed dentin, and presence of odontoblast-like cells. All samples in the propolis group showed inflammation less than 10% after 45 days (100%); while, in the calcium hydroxide group, inflammation was less than 10% in only one sample (20%).

Propolis suppresses the production of prostaglandins and leukotrienes by inhibiting the expression and activity of cyclooxygenases (COX-1 and COX-2) and lipoxygenases.²² Flavonoids and caffeic acid present in propolis play an important role in reducing the inflammatory response. Flavonoids present in propolis may induce reparative dentin formation. Furthermore, by stimulating the production of transforming growth factor-beta 1, they may delay pulp inflammation and induce collagen synthesis by dental pulp cells.^{22, 23} Parolia et al, histologically evaluated and compared dental pulp following pulp capping with propolis and calcium hydroxide and reported lower rates of inflammation in the propolis group.⁸ Propolis decreases the number of neutrophils and level of prostaglandin E2. Thus, it can reduce inflammation especially in the acute phase.¹⁶ The present results confirmed this statement.

In the present study, calcium hydroxide was used as the conventional gold standard pulp capping agent. High pH of calcium hydroxide (12.5) leads to development of liquefactive necrosis at the most superficial pulp layer adjacent to the pulp capping agent.²⁴⁻²⁶ It seems that calcium hydroxide toxicity is neutralized in deeper layers of the pulp tissue leading to development of coagulation necrosis at the interface of necrotic tissue and vital pulp. This is attributed to the mild pulp irritation at the deeper layers. This mild irritation triggers an inflammatory response which, in absence of microorganisms, results in repair and transformation of pulp tissue to a hard tissue.^{24, 26, 27} Hard-setting calcium hydroxide does not cause necrosis of the superficial layers of the pulp tissue but leads to pulp tissue repair by formation of hard tissue.^{28, 29}

In the present study, we used third molars which have anatomical variations. Pulp necrosis was observed in two samples in the calcium hydroxide group. In both the mentioned samples, the pulp chamber was small and considering the aforementioned statements, may be responsible for pulp necrosis.

Bretz et al. evaluated and compared direct pulp capping with propolis and calcium hydroxide and found that the two materials were almost the same in terms of reorganization of normal pulp tissue, not increasing its vascularity, low level of inflammation, and triggering the formation of reparative dentin.³⁰ According to the present findings, calcium hydroxide induced reparative dentin formation with a low quality dentin with voids that resembled bone tissue called osteodentin; but, the newly formed dentin induced by propolis was a high quality dentin containing tubules that can act as a barrier against the invasion of microbial pathogens and prevent pulpal damage.

In this study, in cases where dentinal bridge had formed in both groups, odontoblast-like cells were present but the type of formed dentinal bridge was different in the two groups. In 100% of the samples in the propolis group, the newly formed dentin was irregular tubular dentin while in the calcium hydroxide group, dentinal bridge formed in two samples made of osteodentin. In both the aforementioned samples, pulp inflammation was greater than 10% which may explain the formation of this type of dentin. Interestingly, one sample in this group formed irregular tubular dentin which had inflammation below 10%. Therefore, a material that can better control inflammation can result in formation of dentin of higher quality. Our study results were in accord with those of Ahangari et al.³¹ Calcium hydroxide under restorative materials undergoes dissolution and can lead to interfacial failure as the result of forces applied while packing the final restorative material.³²⁻³⁴

Conclusion

The present study showed successful application of propolis for vital pulp therapy. It did not cause inflammation, infection or pulp necrosis and induced the formation of high quality tubular dentin.

Conflict of Interest

No Conflict of Interest Declared ■

References

- Ingle JI. PDQ endodontics: PMPH USA; 2019.chap;27;P:886.
- Ricucci D, Siqueira Jr JF, Li Y, Tay FR. Vital pulp therapy: histopathology and histobacteriology-based guidelines to treat teeth with deep caries and pulp exposure. *J Dent.* 2019Jul;86:41-52.
- Kawashima N, Okiji T. Odontoblasts: Specialized hard-tissue-forming cells in the dentin-pulp complex. *Congenit Anom (Kyoto).* 2016;56(4):144-53.
- Didilescu AC, Cristache CM, Andrei M, Voicu G, Perlea P. The effect of dental pulp-capping materials on hard-tissue barrier formation: A systematic review and meta-analysis. *J Am Dent Assoc.* 2018;149(10):e903-17.
- Sahebi S, Nabavizadeh M, Dolatkah V, Jamshidi D. Short term effect of calcium hydroxide, mineral trioxide aggregate and calcium-enriched mixture cement on the strength of bovine root dentin. *Iran Endod J. Spring* 2012;7(2):68-73.
- Fuks A, Bielik S, Chosak A. Clinical and radiographic assessment of direct pulp capping and pulpotomy in young permanent teeth. *Pediatr Dent.* 1982; 4(3):240-4.
- Mali SR, Mangala T. Histological Analysis Of Reparative Dentin Formation Using Bio Dentine And Mta As Pulp Capping Agent: An In Vivo Study. *J Crit Rev.* 2020;7(7):653-7.
- Parolia A, Kundabala M, Rao N, Acharya S, Agrawal P, Mohan M, et al. A comparative histological analysis of human pulp following direct pulp capping with Propolis, mineral trioxide aggregate and Dycal. *Aust Dent J.* 2010;55(1):59-64.
- Martinotti S, Ranzato E. Propolis: a new frontier for wound healing? *Burns trauma.* 2015;3(1):1-7.
- Kapare HS, Sathiyarayanan L. Nutritional and Therapeutic potential of Propolis: A Review. *Research J. Pharm. and Tech.* 2020; 13(7): 3545-9.
- Almuhayawi MS. Propolis as a novel antibacterial agent. *Saudi J Biol Sci.* 2020;27(11): 3079-86.
- Santiago de Sousa AR, Cruz de Moraes SZ, Barbosa Viana-Júnior A, Divino de Araujo E. Toward a Novel Pharmacology and Therapeutic Understanding of Brazilian Propolis: A Meta-Analytical Approach. *Pharmacogn Rev.* 2020;14(27):1-7.
- Galeotti F, Capitani F, Maccari F, Mantovani V, Volpi N. Capillary Electrophoresis Separation of Artepillin C: Determination in Brazilian Green Propolis. *J Chromatogr Sci.* 2021;59(10):994-1003.
- Boufadi MY, Soubhye J, Van Antwerpen P. Anti-inflammatory, antioxidant effects, and bioaccessibility of Tizgirt propolis. *J. Food Biochem.* 2021; 45(1):e13663.
- Ardekani MR, Houshmand B, Razavi SM. The effect of aloe vera on apoptosis of periodontal ligament cells. *Eurasia J BioSci.* 2020;14(1):195-200.
- Gjertsen AW, Stothz KA, Neiva KG, Pileggi R. Effect of propolis on proliferation and apoptosis of periodontal ligament fibroblasts. *Oral Surg Oral Med Oral Pathol Oral Radiol Endod.* 2011;112(6):843-8.
- Cushley S, Duncan H, Lappin M, Chua P, Elamin A, Clarke M, et al. Efficacy of direct pulp capping for management of cariously exposed pulps in permanent teeth: a systematic review and meta-analysis. *Int Endod J.* 2021;54(4):556-71.
- Ali H, Raslan N. Direct pulp capping (DPC) in primary molars using (3Mix-MP) and the characteristics of the carious lesion as predictor factors for its success: a randomized controlled trial. *Eur Arch Paediatr Dent.* 2021;22(4):633-642.
- Çalışkan MK, Güneri P. Prognostic factors in direct pulp capping with mineral trioxide aggregate or calcium hydroxide: 2- to 6-year follow-up. *Clin Oral Investig.* 2017;21(1):357-367.
- Kang C-M, Sun Y, Song JS, Pang N-S, Roh B-D, Lee C-Y, et al. A randomized controlled trial of various MTA materials for partial pulpotomy in permanent teeth. *J Dent.* 2017;60:8-13.
- Hilton TJ. Keys to clinical success with pulp capping: a review of the literature. *Oper Dent.* 2009;34(5):615-25.
- Farooqui T, Farooqui AA. Beneficial effects of propolis on human health and neurological diseases. *Front Biosci (Elite Ed).* 2012;4:779-93.
- Awawdeh L, AL-Beitawi M, Hammad M. Effectiveness of propolis and calcium hydroxide as a short-term intracanal medicament against *Enterococcus faecalis*: A laboratory study. *Aust Endod J.* 2009;35(2):52-8.
- Mohanty D, Miglani D, Patro D. VITAL PULP THER APY: A Literature Review Of The Material Aspect. *Eur. J. Mol. Clin. Med.* 2021;7(3):849-56.
- Farhad A, Mohammadi Z. Calcium hydroxide: a review. *Int Dent J.* 2005;55(5):293-301.
- Bonsor SJ. Contemporary strategies and materials to protect the dental pulp. *Dental Update.* 2017;44(8):731-41.
- Schroder U. Early reaction of intact human teeth to calcium hydroxide following experimental pulpotomy and its significance to the development of hard tissue barrier. *Odont Revy.* 1971;22:379-96.
- Tronstad L. Reaction of the exposed pulp to Dycal treatment. *Oral Surg Oral Med Oral Pathol.* 1974;38(6):945-53.
- Reddy S, Prakash V, Subbiya A, Mitthra S. 100 Years of Calcium Hydroxide in Dentistry: A Review of Literature. *Indian J Forensic Med Toxicol.* 2020;14(4):1203.
- Bretz WA, Chiego DJ Jr, Marcucci MC, Cunha I, Custódio A, Schneider LG. Preliminary report on the effects of propolis on wound healing in the dental pulp. *Z Naturforsch C J Biosci.* 1998;53(11-12):1045-8.
- Ahangari Z, Naseri M, Jalili M, Mansouri Y, Mashhadiabbas F, Torkaman A. Effect of propolis on dentin regeneration and the potential role of dental pulp stem cell in Guinea pigs. *Cell J.* 2012;13(4):223-8.
- Via Jr WF. Evaluation of deciduous molars treated by pulpotomy and calcium hydroxide. *J Am Dent Assoc.* 1955;50(1):34-43.
- Cox CF, Suzuki S. Re-evaluating pulp protection: calcium hydroxide liners vs. cohesive hybridization. *J Am Dent Assoc.* 1994;125(7):823-31.
- Roelianto M, Wahjuningrum DA, Pamungkas YB, Zubaidah N, Permatasari RI, Dianti E. In vivo Study of Sealing Capability of Raw Propolis Extract and Calcium Hydroxide on Dentin Surface. *Clin Cosmet Investig Dent.* 2020;12:335-41.

How to cite:

Ahangari Z, Mashhadiabbas F, Feli M, Jafari Z, Zadsirjan S. Evaluation of Pulp Tissue Following Direct Pulp Capping with Propolis versus Calcium Hydroxide: A Clinical Trial. *J Dent Sch* 2020;38(4):134-138.