

# Intraosseous Primary Leiomyosarcoma of the Mandible: A Rare Case Report

Fatemeh Mashhadiabbas <sup>a</sup>, Reza Tabrizi <sup>b</sup>, Mostafa Alam <sup>c</sup>, Sanaz Gholami Toghchi <sup>d</sup>

<sup>a</sup>Associate Professor, Dept. of Oral & Maxillofacial Pathology, School of Dentistry, ShahidBeheshti University of Medical Sciences, Tehran, Iran.

<sup>b</sup>Associate Professor, Dept. of Oral & Maxillofacial Surgery, School of Dentistry, ShahidBeheshti University of Medical Sciences, Tehran, Iran.

<sup>c</sup>Assistant Professor, Dept. of Oral & Maxillofacial Surgery, School of Dentistry, ShahidBeheshti University of Medical Sciences, Tehran, Iran.

<sup>d</sup>Assistant Professor, Dept. of Oral & Maxillofacial Pathology, School of Dentistry, ShahidBeheshti University of Medical Sciences, Tehran, Iran.

Correspondence to SanazGholamiToghchi (email: drsanazgholami@gmail.com).

(Submitted: 09August2020 – Revised version received: 04October2020 – Accepted: 05October2020– Published online: Winter2021)

**Objectives** Spindle-shaped lesions, which include a wide range of reactive lesions from malignant to very invasive, are among the most challenging head and neck pathologies. Herein, we report a case of leiomyosarcoma (LMS) of the mandible for which, immunohistochemistry was performed to find out whether it was a primary or a metastatic tumor.

**Case** This case report presents a 23-year-old female with a 3-month history of pain and mild swelling in the anterior mandible. Panoramic radiography and cone-beam computed tomography revealed an osteodestructive lesion in the mandible. The tumor was composed of interlacing fascicles of spindle-like cells with pleomorphism, hyperchromatism, and atypical mitotic figures. Immunohistochemical (IHC) staining revealed that the tumor cells were positive for vimentin, smooth muscle actin (SMA), desmin, and P53 and had negative reactivity for estrogen receptor (ER) and S100. The patient underwent hemi-mandibulectomy with immediate reconstruction via a microvascular fibula flap. The patient died 15 months after surgery due to metastasis to the right pleura.

**Conclusion** Primary LMS of the jaws is rare and can be confirmed by IHC staining.

**Keywords** Leiomyosarcoma; Mandible; Immunohistochemistry

## Introduction

Leiomyosarcoma (LMS) is a malignant smooth muscle tumor that is usually seen in the gastrointestinal tract, retroperitoneal space, and uterus.<sup>1</sup>LMS accounts for approximately 3-10% of all sarcomas in the head and neck region. LMS of the oral cavity and jaws is rare. The sources of smooth muscle in the oral cavity and the jaws include the primitive mesenchyme cells, blood vessels, circumvallate papilla, and myoepithelial cells of the salivary glands.<sup>2, 3</sup> Based on the available literature, there have been around 38 cases of primary jawbone LMSs since the 1944.

LMS more commonly occurs in females in a wide age range; however, primary LMS of the jaw has almost equal sex predilection.<sup>4</sup>The clinical features are not specific, and include an enlarged mass with/without pain, ulceration of the oral mucosa, lymphadenopathy, and dysesthesia.<sup>3,5</sup>

Differential histopathological diagnosis of LMS from benign spindle cell tumors is difficult. The histopathological features such as cellularity, necrosis, atypia, and number of mitoses per high-power field appear to be the best criteria for malignancy.<sup>6</sup>Immunohistochemical (IHC) staining for smooth muscle actin (SMA), desmin, and vimentin is used for definite diagnosis of LMS.<sup>7</sup>

The prognosis of head and neck LMS is poor. The survival rate of patients with LMS of the oral cavity and sinonasal area is around 32-43%. Approximately, 45% of the cases have high rate of recurrence, and distant metastasis occurs in 17-35%.<sup>7, 8</sup>The most common sites of metastasis include the lungs, bone, brain, and lymph nodes.<sup>9</sup>

This case report describes a case of primary LMS of the mandible in a 23-year-old female, who underwent IHC staining of tumor cells and surgical tumor resection.

## Case

A 23-year-old female was referred to the Maxillofacial Department of Shahid Beheshti University of Medical Sciences in January 2018 with the chief complaint of pain and mild intraoral swelling in the anterior mandible extending from tooth #35 to tooth #45 (Figure 1).

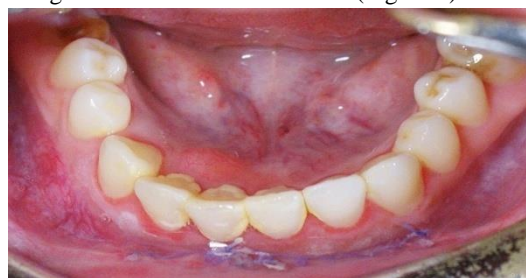

Figure 1- Intraoral view of the mild swelling in the anterior mandible

The patient had first noticed the swelling 3 months earlier. The alveolar mucosa was normal and severe mobility of teeth #35 to #45 was seen. No cervical lymphadenopathy was present. Panoramic radiographic examination revealed an ill-defined radiolucent lesion, extending from tooth #35 to #45 (Figure 2). Cone-beam computed tomography confirmed an aggressive osteolytic lesion that had caused destruction of the mandibular buccal and lingual cortices (Figure 3). Computed tomography (CT) scan of the abdomen and chest X-ray were normal.

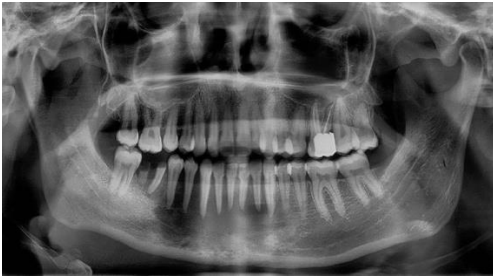

Figure 2- Panoramic radiograph showing an ill-defined radiolucent lesion in the anterior mandible, extending from tooth #35 to #45

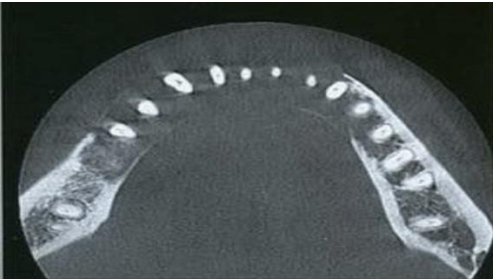


Figure 3- Cone-beam computed tomography revealing an osteolytic lesion causing destruction of mandibular buccal and lingual cortices

According to clinical and radiographic findings, soft tissue sarcoma, odontogenic myxoma, and intrabony non-Hodgkin's lymphoma were considered at the top of the list of differential diagnosis.

An incisional biopsy was performed under local anesthesia. The specimen was fixed in formalin, embedded in paraffin, and stained with hematoxylin and eosin. Microscopic assessment revealed a malignant mesenchymal tumor composed of interlacing fascicles of spindle-like and epithelioid cells with pleomorphism, hyperchromatism, and atypical mitotic figures (27 per 10 high-power fields). Spindle cells had blunt-ended, cigar-shaped nuclei and abundant eosinophilic cytoplasm (Figure 4A and 4B). No tumoral necrosis was seen. Sections of nerve bundles, giant cells, hemorrhage, and resorbed bone were also seen.

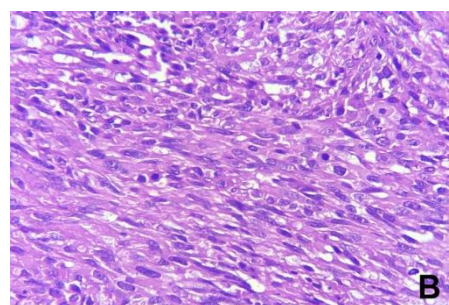
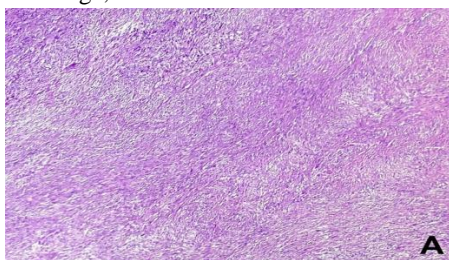


Figure 4. (A) Photomicrograph showing fascicle arrangement of spindle-shaped cells (H&E stain, x40). (B) Photomicrograph showing spindle cells with pleomorphism, blunt-ended, cigar-shaped nuclei, and abundant eosinophilic cytoplasm (H&E stain, x400)

Considering the histopathological findings, differential diagnosis of spindle-cell sarcoma consisted of LMS, sarcomatoid carcinoma, malignant peripheral nerve sheath tumor, and fibrosarcoma. Thus, for definite diagnosis, IHC staining for vimentin, SMA, P53, estrogen receptor (ER) and S100 was performed. The IHC results showed positive reactivity for vimentin, SMA, Desmin, and P53, and negative reactivity for ER and S100 (Figure 5A-E)

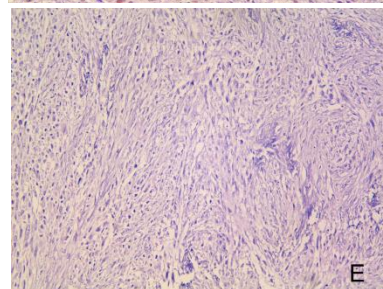
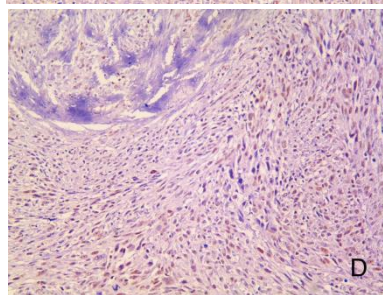
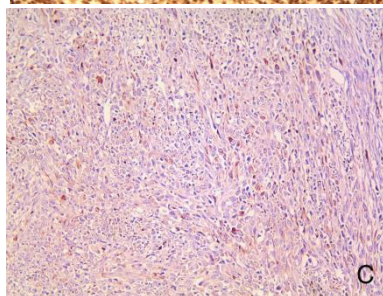
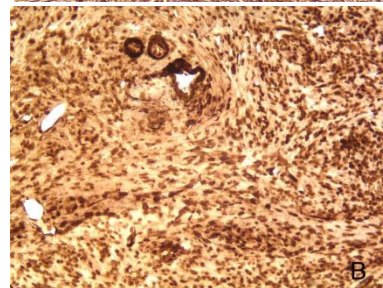
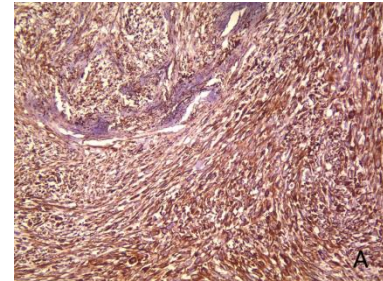
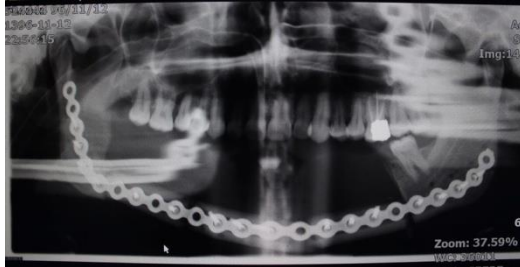


Figure 5. Photomicrographs show reactivity of tumor cells for (A) vimentin, (B) SMA (C) desmin, (D) P53 and (E) ER (IHC stain, x200)

Therefore, the diagnosis of primary LMS was confirmed. Based on the diagnosis of LMS, the patient was scheduled for surgery. General anesthesia was induced by

endotracheal tube, and the aseptic protocol was strictly followed. A partial resection of the mandible with conservation of both condyles was performed with immediate reconstruction using microvascular fibula flap empowered with a reconstruction plate with 2.4 mm diameter and 16 screws (Figure 6).



**Figure 6. Panoramic radiograph 1.5 months after partial resection of the mandible with bone reconstruction by a titanium plate**

The surgical specimen measured 12 x 4.5 x 3 cm and fixed in 10% formalin. Histopathological assessment of the excisional biopsy specimen confirmed the diagnosis of primary LMS.

The follow-up CT scan after 6 months revealed right pleural effusion and thickened diaphragmatic surface. Development of a 7 mm nodule in the right upper lobe was also noted. The patient refused further therapy and died of disease 15 months after the initial surgery. Informed consent was obtained from the patient's parents for publishing her clinical photographs and radiographs.

## Discussion

Intraoral LMS is a very rare neoplasm with an incidence rate of <0.06%.<sup>10</sup> The most common intraoral sites of LMS include the cheeks, mandible, gingiva, maxilla, floor of the mouth, tongue, and soft and hard palate mucosa.<sup>11</sup> Approximately 50% of LMS cases occur in the jaws, especially in the mandible and substantially originate from the vascular smooth muscles.<sup>2, 12</sup> A systematic review by vilos et al reported that LMS has two peak age ranges of 10 to 30 years, and 60 to 70 years.<sup>13</sup>

The definite diagnosis of spindle-cell tumors can be very difficult and it should be differentiated from other tumors.<sup>14</sup> Histopathological features such as atypical necrosis and number of mitoses per high-power field are correlated with malignancy but the main criteria of malignancy depend on the anatomical location of the lesion.<sup>10</sup> In the past, Masson's trichomestaining and

periodic acid-Schiff were used to identify smooth muscle fibers; but at present, IHC staining of SMA, desmin, and vimentin can be helpful for LMS diagnosis.<sup>15</sup> P53 expression can be useful in prediction of high recurrence rate and short survival rate, and for differentiation between malignant and benign smooth muscle tumors.<sup>11</sup>

In the present case, IHC staining was performed for the incisional and excisional biopsy samples, which was positive for vimentin, SMA and P53. Negative ER indicates that the origin of intraoral LMS is different from the origin of LMS of other soft tissues, because ER is the diagnostic marker in uterine and female retroperitoneal LMS.<sup>16</sup>

With regard to management of LMS, combined therapy comprising of surgical treatment with adjuvant radiotherapy and chemotherapy would be effective.<sup>10</sup> Elective radical neck dissection is unnecessary, unless metastasis to lymph nodes or clinical lymphadenopathy is present.<sup>6</sup> Microscopic findings of free surgical margins are the best predictor of good prognosis.<sup>17</sup>

In this case, the choice of treatment was partial resection of the mandible with conservation of both condyles, which was performed with immediate reconstruction using microvascular fibula flap. The patient died 15 months after the initial surgery due to metastasis to the right lung.

## Conclusion

In conclusion, LMS is an aggressive tumor, and its prognosis depends on early diagnosis, which is possible with the help of imaging, histopathological assessment, IHC staining, and total tumor resection. Although the surgical margins may be microscopically free, LMS can be treated or alternatively, result in local or distant metastasis.

Negative ER expression in LMS of the jaw indicates that it is a primary tumor and not a metastatic lesion secondary to uterine LMS in women.

## Acknowledgments

The authors thank all those who contributed in writing of this paper.

## Conflict of Interest

No Conflict of Interest Declared ■

## References

1. Ruka W, Rutkowski P, Krzakowski M, Grzesiakowska U, Ptaszyński K, Jeziorski A, et al. Soft tissue sarcoma-diagnosis and treatment. *Onkol Prak Klin*. 2009;5(5):198-210.
2. Lo Muzio L, Favia G, Mignogna MD, Piattelli A, Maiorano E. Primary intraoral leiomyosarcoma of the tongue: an immunohistochemical study and review of the literature. *Oral Oncol*. 2000;36(6):519-24.
3. Amarapala H, Tilakaratne WM. Leiomyosarcoma of the oral cavity: report of seven cases and review of literature. *Oral Oncol Extra* 2006;42(1):14-7.
4. Mendonça EF, Martins da Silva C, Meneghini AJ, Silva GB, Filho JA, Batista AC. Low-grade gingival leiomyosarcoma in a child. *J Dent Child (Chic)* 2008;75(3):301-5.

5. Choi YS, Almansoori AA, Jung TY, Lee JI, Kim SM, Lee JH. Leiomyosarcoma of the jaws: case series. *J Korean Assoc Oral Maxillofac Surg*. 2020 46(4):275-81.
6. Wertheimer-Hatch L, Hatch GF 3rd, Hatch B S KF, Davis GB, Blanchard DK, Foster RS Jr, et al. Tumors of the oral cavity and pharynx. *World J Surg* 2000;24(4): 395-400.
7. Izumi K, Maeda T, Cheng J, Saku T. Primary leiomyosarcoma of the maxilla with regional lymph node metastasis. Report of a case and review of the literature. *Oral Surg Oral Med Oral Pathol Oral Radiol Endod* 1995; 80(3):310-9.
8. Kuruvilla A, Wenig BM, Humphrey DM, Heffner DK. Leiomyosarcoma of the sinonasal tract. A clinicopathologic study of nine cases. *Arch Otolaryngol Head Neck Surg* 1990;116(11):1278-86.
9. Schenberg ME, Slootweg PJ, Koole R. Leiomyosarcomas of the oral cavity. Report of four cases and review of the literature. *J Craniomaxillofac Surg* 1993;21(8):342-7.
10. Lewandowski B, Brodowski R, Pakla P, Stopyra W, Gawron I. Leiomyosarcoma in the mandible: A rare case report. *Medicine (Baltimore)* 2016;95(27):e4011.
11. Nikitakis NG, Lopes MA, Bailey JS, Blanchaert RH Jr, Ord RA, Sauk JJ. Oral leiomyosarcoma: review of the literature and report of two cases with assessment of the prognostic and diagnostic significance of immunohistochemical and molecular markers. *Oral Oncol* 2002;38(2):201-8.
12. Kang BC, Jang DD, Lee SK. Oral leiomyosarcoma in a woodchuck (*Marmota monax*). *J Vet Med Sci* 2005;67(3):353-5.
13. Vilos GA, Rapidis AD, Lagogiannis GD, Apostolidis C. Leiomyosarcomas of the oral tissues: clinicopathologic analysis of 50 cases. *J Oral Maxillofac Surg*. 2005;63:1461-77.
14. Lloria-Benet M, Bagán JV, Lloria de Miguel E, Borja-Morant A, Alonso S. Oral leiomyoma: a case report. *Med Oral* 2003;8(3):215-9.
15. Lack EE, Graham CW, Azumi N, Bitterman P, Rusnock EJ, O'Brien W, et al. Primary leiomyosarcoma of adrenal gland. Case report with immunohistochemical and ultrastructural study. *Am J Surg Pathol* 1991;15(9):899-905.
16. Zhang Q, Kanis MJ, Ubago J, Liu D, Scholtens DM, Strohl AE, et al. The selected biomarker analysis in 5 types of uterin smooth muscle tumors. *Hum Pathol* 2018;76:17-27.
17. Rege IC, Costa NL, Batista AC, da Silva CM, Meneghini AJ, Mendonça EF. High-grade primary leiomyosarcoma in the mandible: diagnosis and treatment. *Head Neck* 2013;35(2):E44-8.

**How to cite:**

Fatemeh Mashhadiabbas, Reza Tabrizi, Mostafa Alam, Sanaz Gholami Toghchi. Intraosseous Primary Leiomyosarcoma of the Mandible: A Rare Case Report. *J Dent Sch* 2020;38(1):37-40.