

Cephalometric Measurements on Conventional Posteroanterior Radiographs versus CBCT Images: A Comparative Study

Hoorieh Bashizadeh Fakhari^a, Milad Soleimani^b

^aAssociate Professor, Department of Dentomaxillofacial Radiology, Faculty of Dentistry, Tehran University of Medical Sciences, Tehran, Iran.

^bAssistant Professor, Department of Orthodontics, School of Dentistry, Alborz University of Medical Sciences, Karaj, Iran.

Correspondence to Milad Soleimani (email: miladsoleimani91@gmail.com).

(Submitted: 18 July 2020 – Revised version received: 8 December 2020 – Accepted: 4 January 2021 – Published online: Summer 2021)

Objectives Facial asymmetry in orthodontic treatments can be evaluated by both posteroanterior (PA) cephalograms and cone-beam computed tomography (CBCT) images. This study aimed to assess the agreement between CBCT and two-dimensional PA images in terms of cephalometric measurements.

Methods In this descriptive analytical study, CBCT and PA radiographs were taken from nine human dry skulls. Two observers marked the bilateral landmarks including CO (orbit center), J (jugale), 6C, 6A, 1A, 1C, GO (gonial angle), AG (antegonion), AR (articular) and Ma (mastoidal). The distance between two identical points on both sides was measured on both the PA and CBCT images. The differences were calculated and the agreement between the two modalities was checked by using intraclass correlation coefficient (ICC).

Results The mean differences between CBCT and PA measurements were as following: for CO=1.48, J=11.64, U6C=0.75, U6A=1.8, L6C=13.33, L6A=3.0, U1C=0.96, U1A=0.62, L1C=0.22, L1A=0.45, GO=0.87, AG=6.67 and AR=0.71 mm. The agreement was the highest for GO (ICC=0.931) and CO (ICC=0.902), and the lowest for U6A (ICC=-0.041) and J (ICC=0.038) landmarks.

Conclusion Given the negligible differences between the two modalities, conventional PA cephalograms can be as competent as CBCT in detecting maxillofacial asymmetry with lower patient radiation dose.

Keywords Cephalometry; Cone-Beam Computed Tomography; Facial Asymmetry

Introduction

Two-dimensional (2D) posteroanterior (PA) cephalometry is a cost-effective, easily available, and reliable method for evaluation of facial asymmetry in orthodontic treatment planning.^{1,2} Meanwhile, the three-dimensional (3D) cone beam computed tomography (CBCT) images provide comprehensive and inclusive information in cases with craniofacial anomaly such as asymmetric cases.²⁻⁶ CBCT provides accurate true-size images of hard and soft tissues, and the respective software facilitates the measurements.⁷⁻⁹ The volumetric data in CBCT allow reconstruction of images in sagittal and coronal views.¹⁰ Yet, CBCT should be cautiously prescribed due to the high patient radiation dose. Therefore, if CBCT and conventional PA cephalograms do not have major differences, CBCT would not be sufficiently justified. This study aimed to compare the cephalometric measurements based on cranial CBCT images versus conventional 2D PA cephalograms.

Methods and Materials

This comparative analytical study was performed on nine dentate dry human skulls. Conventional PA cephalograms were taken by using ProMax imaging unit (Planmeca ProMax; Helsinki, Finland) at 4 mA, 58 kVp and 12 s time (Figure 1). The Frankfurt plane was horizontally adjusted, and the skulls were mounted on the unit, with the magnification factor set on 1. The images were analyzed by Romexis software (Planmeca Romexis; Helsinki, Finland). Ten bilateral landmarks were marked on each image (Table 1). The distance between identical landmarks on the right

and left sides was measured by using the measuring tool of the software (Figure 2).

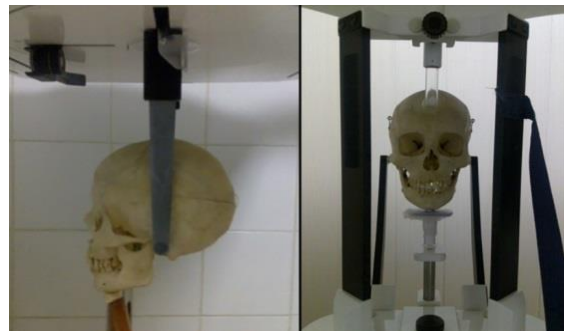


Figure 1- Stereophotography in a two-dimensional and three-dimensional technique (178×69 mm, 300 DPI)

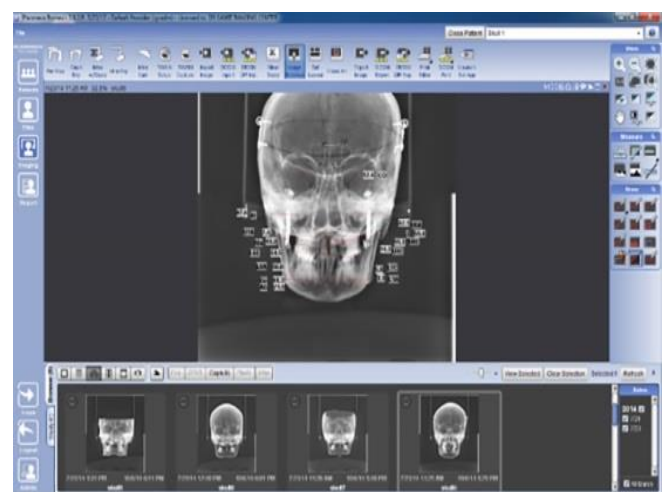

Figure 2- Distance measurement on conventional 2D posteroanterior image by Romexis software for two-dimensional images

Table 1- Definition of the studied landmarks

Landmarks	Definition
CO	Central orbit
J	Jugular
6C	Distal point of the alveolar bone at the site of maxillary and mandibular first molars
6A	Final point on the buccal surface of the root of the first maxillary (mesiobuccal) and mandibular (mesial) molars
1C	Distal point of the alveolar bone at the site of maxillary and mandibular central incisors
1A	Apex tip of maxillary and mandibular central incisors
GO	Gonion; the most inferior, posterior, and lateral point on the angle of the mandible
AG	Antegonion; the most inferior extent of the cortical bone at the point of maximum concavity from the gonial angle of the mandible to the body of the mandible
AR	Articulare; the point of intersection of the inferior cranial base surface (basioccipital) and the posterior surface of the mandibular condyle
Ma	The apex of the mastoid

CBCT images were taken by Alphard-3030 CBCT scanner (Asahi Roentgen; Tokyo, Japan) at 2 mA and 80 kVp (Figure 3). Data were exported to Romexis software (Planmeca Romexis; Helsinki, Finland). The same bilateral landmarks were marked on CBCT frontal images with the Frankfort plane horizontally adjusted. The distance between the identical landmarks on the right and left sides was measured by the measuring tool of the software.

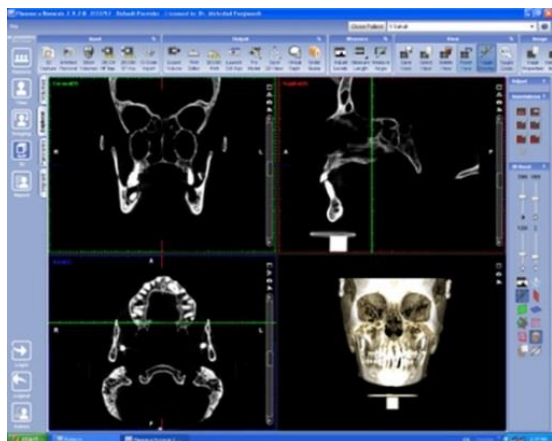


Figure 3- Distance measurement on 3D CBCT images by NEO 3D software (180×82 mm, 300 DPI)

The consistency of the measurements based on PA cephalograms and CBCT images was evaluated by calculating the interclass correlation coefficient (ICC). SPSS software (version 21; SPSS Inc., Chicago, IL, USA) was used for statistical analyses ($\alpha=0.05$).

Results

Table 2 displays the mean (standard deviation) differences in the landmarks measured on 2D PA and 3D CBCT images. The ICC revealed that the two imaging modalities had the highest rate of agreement in GO (ICC=0.931) and CO

(ICC=0.902), and the lowest agreement in U6A (ICC=-0.041) and J (ICC=0.038) landmarks. Table 3 shows the ICC of the two imaging modalities concerning the repeatability (consistency) of the distances between the measured landmarks.

Table 2- The mean (standard deviation) difference in landmarks between the CBCT and PA cephalometric images

Landmarks	Mean (SD)	Range
CO	1.48 (1.97)	2.4-6.4
J	11.64 (13.02)	12.84-36.9
U6C	0.75 (2.79)	5.62-5.82
U6A	1.8 (5.64)	9.42-12.4
L6C	0.33 (5.49)	6.8-15.51
L6A	3.13 (4.96)	7.79-11.45
U1C	0.96 (1.39)	3.61-1.57
U1A	0.62 (1.21)	2.49-2.4
L1C	0.22 (1.73)	2.47-4.42
L1A	0.45 (1.22)	1.5-2.61
GO	0.87 (3.35)	6.83-4.52
AG	6.67 (5.94)	1.61-18.28
AR	0.71 (4.07)	6.94-8.7

SD: Standard deviation

Discussion

Based on the present findings, the measurement differences between the two imaging modalities were less than 2 mm in 9 landmarks, 3 mm in L6A, and even higher in J, L6C, and AG landmarks. Besides the statistical differences, the differences greater than 1 mm are clinically significant¹¹⁻¹³, as in three cases in the present study, whose landmarks were not comparable since they only used one modality. These excluded, the measured distances on both CBCT and PA radiographs were comparable in most cases.

Mehdizadeh and Faghihian¹⁴ reported the mean absolute value of the differences between CBCT measurements and those made on dry skulls to be less than 1 mm in 42%, less than 2 mm in 42%, and 3 mm in 16% of the studied variables, indicating higher accuracy of CBCT compared with the lateral cephalometric digital technique. In the present study, the mean absolute value of the difference between CBCT and PA measurements was less than 1 mm in 53.8% of the landmarks, indicating higher agreement between the two modalities compared with what was reported by Mehdizadeh and Faghihian¹⁴; however, the differences were greater in three landmarks in the present study (jugal, antegonial and L6C).

Fuyamada et al.¹⁵ compared the repeatability of the results of landmark identification on 3D CBCT images and conventional cephalometric technique and reported similar errors for both modalities in most landmarks, which was in line with the present study. Likewise, Damstra et al.¹⁶ achieved almost similar results with both the conventional lateral cephalograms and CBCT scans. In another comparative study, Yitschaky et al.¹⁷ detected no significant difference between the results of 2D calculations of cephalostat and 3D CT calculations in terms of linear and relative calculations. In this study, the calculations based on

the conventional cephalometric radiographs were mostly confirmed with 3D images except for sella turcica.

Kumar et al.¹⁸ asserted that the CBCT of dry skulls was quite more accurate than the conventional lateral cephalometric images, particularly in mid-size measurements. Such a difference might be attributed to the magnification of the lateral cephalometric images between 7% and 12%.¹⁹ In a study by Mehdizadeh and Faghihian¹⁴, the magnification of lateral cephalometric technique equaled 1; therefore, the difference between the CBCT and lateral cephalometric images was merely attributed to the technical differences of the two modalities. The x-ray source in the lateral cephalogram is located at a distance of 1.524 m from the midsagittal plane and the film is 13 cm away from the plane; while in CBCT, the radiation source has a constant distance from the midpoint of the head.²⁰

Three-dimensional imaging allows producing volumetric data from the skull and reconstructing images in different planes to visualize the actual shape of the skull, jaw, and facial bones, and measure the relationships between them. This feature particularly matters in craniofacial and orofacial anomalies. Meanwhile, cephalometric calculations are prone to errors due to the quality of radiographs, interpretation of radiography, and determination of landmarks.²¹ The sampling method can also be the source of error. Besides, the individuals' craniofacial shape and their facial indices can be influenced by the environmental and geographical factors. Moreover, cephalometric measures are calculated based on the mean values; hence, the normal values might be biased or associated with errors in patients out of the normal percentile of growth at the time of calculating the mean values for each age group. On the other hand, in 2D cephalograms, landmarks are mainly defined as the lower and upper points of different structures, without defining the third dimension. Additionally, a point on the edge of a structure on a lateral cephalogram may not correspond to the same point on a coronal cephalogram due to patient displacement around the cephalostat rods and different x-ray projections.²²

The highest agreement between CBCT and PA cephalometry was detected in GO (ICC=0.931) and CO landmarks (ICC=0.902), and the lowest in U6A (ICC=-0.041) and J (ICC=0.038). In CBCT, the multiple 3D observations and the structured sections enable the technician to better determine the position of landmarks and compute the distances. In a 2D technique, the technician often tries to estimate the vicinity of landmarks to the adjacent structures or to detect the contrast between radiopaque and radiolucent structures. However, the technician might fail to identically replicate the initial observations. In CBCT, the errors of distance measurement might be reduced by better interpretations and repeating the observations; whereas, 2D images do not allow

improving the repeatability of images along with increasing the technician's experience. Not all oral radiology centers benefit from the novel technology of CBCT; hence, only a limited number of orthodontists make use of it. Investigations are required to evaluate the role of the operator's experience and skills in distance measurement. The consensus on the definitions of 3D landmarks is also an important factor in using cephalometric analyses in 3D imaging modalities. CBCT 3D analysis is a precise and practical method to determine abnormalities in the maxillofacial region; yet, it should be cautiously used due to the high patient radiation dose and costs. Meanwhile, PA cephalometry has recently improved in terms of repeatability and diagnostic standards.²²⁻²⁴

Taking into account the cost-effectiveness, PA cephalometry can be the main technique to determine the degree of facial asymmetry or other anomalies. The 3D reconstruction of images in CBCT provides sufficient information wherever the PA cephalometry falls short and should be considered for a more accurate diagnosis. Standard orthodontic diagnosis is usually based on panoramic radiographs, lateral cephalograms, and PA radiographs, with the approximate radiation dose of 25-35 μ Sv. Whereas, in CBCT, the radiation dose is in a larger field of view scan to achieve a complete orthodontic diagnosis within the range of 1073 to 1076 μ Sv. This additional radiation dose is only worth if it improves the treatment outcomes and reduces the treatment time and costs. Otherwise, this imaging technique is not recommended.²⁵ Further research is required to evaluate the effects of CBCT diagnoses on treatments.

Conclusion

Considering the general consistency regarding calculating the distances between the landmarks on the two imaging modalities, the usual cephalometric method seems to be still valid to detect abnormalities of the jaw and face in orthodontic patients. Therefore, the additional radiation and costs of CBCT can be avoided, unless the conventional PA images fail to provide the required diagnostic information.

Acknowledgement

Appreciations are expressed to Ms. Farzaneh Rasooli for copyediting and improving the use of English in this manuscript.

Conflict of Interest

No Conflict of Interest Declared ■

References

1. Bajaj K, Rathee P, Jain P, Panwar VR. Comparison of the reliability of anatomic landmarks based on PA cephalometric radiographs and 3D CT scans in patients with facial asymmetry. *Int J Clin Pediatr Dent* 2011;4:213-23.
2. Kokich VG. Cone-beam computed tomography: have we identified the orthodontic benefits? *Am J Orthod Dentofacial*

Orthop 2010;137:S16.

3. Hassan B, van der Stelt P, Sanderink G. Accuracy of three-dimensional measurements obtained from cone beam computed tomography surface-rendered images for cephalometric analysis: influence of patient scanning position. *Eur J Orthod* 2009;31:129-34.
4. Hwang H-S, Hwang CH, Lee K-H, Kang B-C. Maxillofacial 3-dimensional image analysis for the diagnosis of facial asymmetry. *Am J Orthod Dentofacial Orthop* 2006;130:779-85.
5. Moss J, McCance A, Fright W, Linney A, James D. A three-dimensional soft tissue analysis of fifteen patients with Class II, Division 1 malocclusions after bimaxillary surgery. *Am J Orthod Dentofacial Orthop* 1994;105:430-7.
6. Vanezis P, Blowes R, Linney A, Tan A, Richards R, Neave R. Application of 3-D computer graphics for facial reconstruction and comparison with sculpting techniques. *Forensic Sci Int* 1989;42:69-84.
7. Brown AA, Scarfe WC, Scheetz JP, Silveira AM, Farman AG. Linear accuracy of cone beam CT derived 3D images. *Angle orthod* 2009;79:150-7.
8. Hilgers ML, Scarfe WC, Scheetz JP, Farman AG. Accuracy of linear temporomandibular joint measurements with cone beam computed tomography and digital cephalometric radiography. *Am J Orthod Dentofacial Orthop* 2005;128:803-11.
9. Kumar V, Ludlow J, Soares Cevidanes LH, Mol A. In vivo comparison of conventional and cone beam CT synthesized cephalograms. *Angle Orthod* 2008;78:873-9.
10. Miner RM, Al Qabandi S, Rigali PH, Will LA. Cone-beam computed tomography transverse analyses. Part 2: Measures of performance. *Am J Orthod Dentofacial Orthop* 2015;148:253-63.
11. Bhambhani R, Bhattacharya J, Sen SK. Digitization and its futuristic approach in prosthodontics. *J Indian Prosthodont Soc* 2013;13:165-74.
12. Chen YJ, Chen SK, Chang HF, Chen KC. Comparison of landmark identification in traditional versus computer-aided digital cephalometry. *Angle Orthod* 2000;70:387-92.
13. McClure SR, Sadowsky PL, Ferreira A, Jacobson A, editors. Reliability of digital versus conventional cephalometric radiology: a comparative evaluation of landmark identification error. *Semin Orthod*; 2005: Elsevier.
14. Mehdizadeh M, Faghihian E. Comparison of linear measurement accuracy on cone-beam computed tomography images and digital lateral cephalometric radiographs. *Journal of Isfahan Dental School* 2013;8:567-75.
15. Fuyamada M, Shibata M, Nawa H, Yoshida K, Kise Y, Katsumata A, et al. Reproducibility of maxillofacial landmark identification on three-dimensional cone-beam computed tomography images of patients with mandibular prognathism: comparative study of a tentative method and traditional cephalometric analysis. *Angle Orthod* 2014;84:966-73.
16. Damstra J, Fourie Z, Ren Y. Comparison between two-dimensional and midsagittal three-dimensional cephalometric measurements of dry human skulls. *Br J Oral Maxillofac Surg* 2011;49:392-5.
17. Yitschaky O, Redlich M, Abed Y, Faerman M, Casap N, Hiller N. Comparison of common hard tissue cephalometric measurements between computed tomography 3D reconstruction and conventional 2D cephalometric images. *Angle Orthod* 2011;81:11-6.
18. Kumar V, Ludlow J, Mol A, Cevidanes L. Comparison of conventional and cone beam CT synthesized cephalograms. *Dentomaxillofac Radiol* 2007;36:263-9.
19. Moshiri M, Scarfe WC, Hilgers ML, Scheetz JP, Silveira AM, Farman AG. Accuracy of linear measurements from imaging plate and lateral cephalometric images derived from cone-beam computed tomography. *Am J Orthod Dentofacial Orthop* 2007;132:550-60.
20. Berco M, Rigali Jr PH, Miner RM, DeLuca S, Anderson NK, Will LA. Accuracy and reliability of linear cephalometric measurements from cone-beam computed tomography scans of a dry human skull. *Am J Orthod Dentofacial Orthop* 2009;136:17.e1-9.
21. Thilander B, Persson M, Adolfsson U. Roentgen- cephalometric standards for a Swedish population. A longitudinal study between the ages of 5 and 31 years. *Eur J Orthod* 2005;27:370-89.
22. de Moraes MEL, Hollender LG, Chen CS, Moraes LC, Balducci I. Evaluating craniofacial asymmetry with digital cephalometric images and cone-beam computed tomography. *Am J Orthod Dentofacial Orthop* 2011;139:e523-31.
23. Kim M-Y, Lee K-M, Cho J-H, Hwang H-S. Correction of positional change of frontal cephalometric landmarks caused by vertical head rotation. *Korean J Orthod* 2011;41:98-111.
24. Lee HJ, Lee S, Lee EJ, Song IJ, Kang B-C, Lee J-S, et al. A comparative study of the deviation of the menton on posteroanterior cephalograms and three-dimensional computed tomography. *Imaging Sci Dent* 2016;46:33-8.
25. Ludlow JB, Davies-Ludlow L, Brooks S, Howerton W. Dosimetry of 3 CBCT devices for oral and maxillofacial radiology: CB Mercuray, NewTom 3G and i-CAT. *Dentomaxillofac Radiol* 2006;35:219-26.

How to cite:

Bashizadeh Fakhar H, Soleimani M. Cephalometric Measurements on Conventional Posteroanterior Radiographs versus CBCT Images: A Comparative Study. *J Dent Sch* 2020;38(3):93-96.