

# Evaluation of Posterior Superior Alveolar Canal on Cone Beam Computed Tomography Images

Zahra Vasegh<sup>a</sup>, Solmaz Valizadeh<sup>b</sup>, Yaser Safi<sup>b</sup>, Mitra Ghazizadeh Ahsaie<sup>c</sup>, Yasaman Mohammadi<sup>d</sup>

<sup>a</sup>Assistant Professor, Dept. of Oral & Maxillofacial Radiology, School of Dentistry, Shahid Beheshti University of Medical Sciences, Tehran, Iran.

<sup>b</sup>Associate Professor, Dept. of Oral & Maxillofacial Radiology, School of Dentistry, Shahid Beheshti University of Medical Sciences, Tehran, Iran.

<sup>c</sup>Postgraduate Student, Dept. of Oral and Maxillofacial Radiology, School of Dentistry, Shahid Beheshti University of Medical Sciences, Tehran, Iran

<sup>d</sup>Undergraduate student, School of Dentistry, Shahid Beheshti University of Medical Sciences, Tehran, Iran

Correspondence to Mitra Ghazizadeh Ahsaie (email: Mitraghazizadeh@gmail.com).

(Submitted: 20 July 2019 – Revised version received: 26 October 2019 – Accepted: 28 October 2019 – Published online: Spring 2019)

**Objectives** The posterior superior alveolar artery (PSAA) is one of the branches of the maxillary artery that is located on the lateral wall of the maxillary sinus. The aim of the present study was to evaluate the detectability, position, and diameter of the posterior superior alveolar (PSA) canal and its relationship with the alveolar ridge using cone-beam computed tomography (CBCT).

**Methods** A total of 257 CBCT images were evaluated. The PSA canal location was categorized into three forms of intra-osseous, below the membrane, and on the outer cortex of the lateral sinus wall. The distance between the lower border of the artery and the alveolar crest, the distance between the artery and the medial wall of the sinus, and the diameter of the artery were all measured. The prevalence of sinusitis and mucous retention cyst was also determined. The Chi-square test and independent t-test were used for statistical analysis.

**Results** The most common type of PSA canal was intra-osseous, followed by beneath the mucosal membrane and on the outer cortex of the lateral sinus wall. The lowest distance between the PSA canal and medial sinus wall and ridge crest, and canal diameter were higher in males ( $P < 0.05$ ). In addition, sinus pathologies were significantly more common in males than females ( $P < 0.05$ ).

**Conclusion** The most common type of PSA canal was intra-osseous, and the distances between the lower border of the canal and the alveolar crest and ridge height decreased with aging; thus, it should be considered during implant surgery.

**Keywords** Maxillary Sinus; Arteries; Cone-Beam Computed Tomography

## Introduction

Posterior superior alveolar (PSA) canal is one of the branches of the maxillary artery that is located on the lateral wall of the maxillary sinus, and supplies this area and the overlying membrane.<sup>1</sup> Various surgical procedures may be performed through the lateral sinus wall such as open sinus lift, Caldwell-Luc surgery, Le Fort I osteotomy, osteosynthesis for treatment of maxillary fractures, and bone grafting before implantation.<sup>1-4</sup> There is a high success rate when implantation is combined with bone grafting in the posterior maxilla; it is advantageous in cases with insufficient residual alveolar bone. During all these procedures, the PSA canal and artery, can easily become traumatized.<sup>5</sup> Insufficient knowledge about the anatomy of the maxillary sinuses prior to sinus graft surgery may lead to perioperative or postoperative complications and may consequently lead to hemorrhage.<sup>6</sup> Also, the larger the size, the greater the risk of severe bleeding would be. Although bleeding may not be a life-threatening complication since only a minor vessel is involved, it may obscure the field of vision during surgery.<sup>7</sup>

To avoid traumatization of this artery and subsequent To avoid traumatization of this artery and subsequent perioperative bleeding, the anatomy of the area should be carefully examined. Locating the exact position and diameter of the PSA canal is substantial prior to any surgical procedure. Enlargement of the maxillary sinus with age and resorption of alveolar crest, or surgical procedures

performed in this area are associated with increased risk of damage.<sup>1</sup>

Cone-beam computed tomography (CBCT) was introduced to dentistry in the late 1990s. It is a digital imaging modality that provides accurate information about the morphology of bone and the location of anatomical landmarks such as the PSA canal.<sup>8</sup> Lower patient radiation dose and lower cost are the major advantages of CBCT over computed tomography (CT).<sup>9</sup>

Considering the clinical significance of this topic, lack of adequate information in this regard, and the controversial results of previous studies on the exact position of the PSA canal in the Iranian population, the aim of the present study was to evaluate the diameter, detectability and position of the PSA artery (PSAA) and its relationship with the alveolar ridge on CBCT images.

## Materials and Methods

### Sample size:

This retrospective study underwent formal review and received approval from Shahid Beheshti University of Medical Sciences (IR.SBMU.DRC.REC.1398.002). Sample size was calculated to be 257 CBCT images (514 maxillary sinuses), which were selected using simple random sampling.

### Evaluation of CT scans:

CBCT scans were retrieved from the archives of a private

oral and maxillofacial radiology clinic. Digital images were taken using Scanora 3D CBCT scanner (Soredex, Finland) with 110 kVp, and 8 x 10-inch field of view. CBCT scans were mostly taken to examine the sinuses, maxillary arch and dentition for tooth extraction or implant placement; therefore, no additional exposure was given to patients.

#### Inclusion criteria:

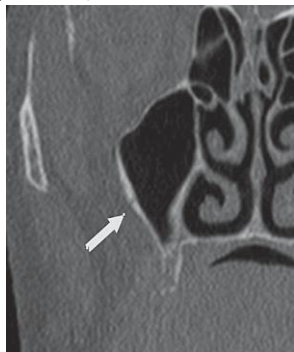- Availability of CBCT scans of the posterior maxilla with missing maxillary molar and premolar teeth in at least one quadrant
- Absence of motion or scattering artifacts

#### Exclusion criteria:

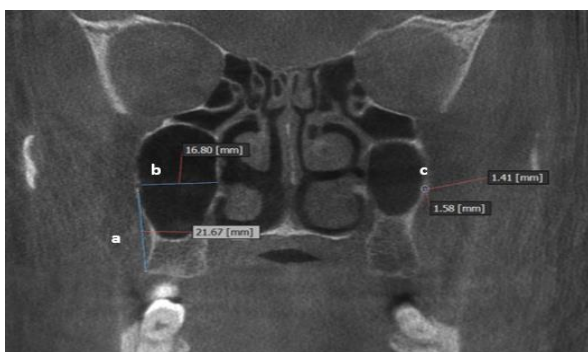
- Patients with pathological lesions
- Severe alveolar ridge atrophy
- Syndromic patients
- Previous history of surgery or grafting in the posterior maxilla

Evaluation of PSA canal was randomly performed by two calibrated oral and maxillofacial radiologists using the same viewing conditions in the coronal cut of each CBCT at the posterolateral wall of the maxillary sinus. Coronal reconstructions were created by reformatting the axial CBCT scans on a local workstation using "OnDemand 3D" software version 7. Before any assessments, the orientation of the images was determined for each patient. All evaluations were repeated after 2 weeks to assess the intra-observer reliability.

CBCT scans were evaluated for the below-mentioned parameters (Figures 1-3):



**Figure 1- Posterior superior alveolar canal**



**Figure 2- a: Distance from the lower border of the PSA canal to the alveolar crest, b: Distance from the PSA canal to the medial sinus wall c: Diameter of the canal**

1. Position of the artery [on the outer cortex of the lateral sinus wall (Figure 3-A)] as intraosseous (Figure 3-B) or below the membrane (Figure 3-C)

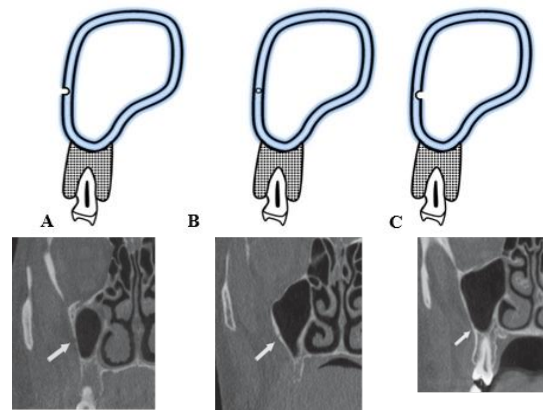
2. Distance from the lower border of the artery to the alveolar crest: the vertical line from the artery to the crest [10]

3. Distance from the artery to the medial sinus wall [6]

4. Diameter of the artery [6]

The diameter of the canal was also analyzed with regard to age, gender and location (right or left).

Maxillary pathologies such as mucosal thickening and acute or chronic sinusitis were recorded for each sinus and assessed in both males and females.



#### Statistical analysis:

The mean values were entered into SPSS software version 21 (SPSS Inc., Chicago, USA) for each parameter and standard deviations were calculated. The Pearson's correlation rank was used to assess the correlation between the canal diameter and age. Unpaired t-test was also used to determine the difference between males and females. The intra-observer agreement was calculated using the intraclass correlation coefficient.

## Results

#### Intra-observer and inter-observer reliability:

The measures for the first and second replicates for 20 patients were recorded and intra-class and inter-class correlation coefficients were calculated for all measurements. Most measures demonstrated a high degree of reliability between the first and second replicates with the correlation coefficient values ranging from 0.73 to 0.99.

#### Demographic and quantitative assessments:

A total of 257 CBCT scans were assessed (144 males and 113 females). The patients' age ranged from 35 to 82 years (mean of  $45.6 \pm 15.26$  years). The PSA canal was detected in almost 78% of CBCT scans. Table 1 demonstrates the visualization rate of PSA canal in the right and left sides of the maxilla. Although the PSA canal was detected more commonly on the right side, this difference was not statistically significant ( $P > 0.05$ ). No significant difference

was noted between males and females in detection of PSA either ( $P>0.05$ ).

**Table 1-** Visualization rate of PSA canal in the left and right sides of the maxilla

Observer	Left side N(%)	Right side N(%)
Observer 1 (first observation)	191(74.30%)	203(78.90%)
Observer 1 (second observation)	200(77.80%)	210(81.70%)
Observer 2 (first observation)	195(75.80%)	198(77.40)
Observer 2 (second observation)	201(78.20%)	205(79.70%)

According to Table 2, the most common type of PSA canal was intra-osseous (75.30% in males and 18.60% in females) followed by beneath the mucosal membrane (18.60% in males and 15.80% in females) and on the outer cortex of the lateral sinus wall (6.10% in males and 5% in females.). This pattern was detected in both males and females and the difference was not statistically significant ( $P>0.05$ ). Table 3 demonstrates the distance from the PSA canal to the alveolar crest ridge, medial sinus wall and canal diameter in males and females. These parameters were significantly different between males and females ( $P<0.05$ ).

**Table 2-** Position of the posterior superior alveolar artery based on gender

	Intraosseous		Beneath the membrane		Outer cortex of sinus wall		P- value
	Prevalence (%)	CI	Prevalence (%)	CI	Prevalence (%)	CI	
<b>Males</b>	75.30	(0.69,0.82)	18.60	(0.13,0.21)	6.10	(0.03,0.09)	0.071
<b>Females</b>	78.60	(0.73,0.83)	15.80	(0.07,0.18)	5	(0.02,0.08)	0.078

CI: Confidence Interval

**Table 3-** Descriptive statistics related to the PSA canal based on gender

Variable (mm)	Male		Female		P-value
	Mean±SD	CI	Mean±SD	CI	
<b>Distance from the inferior border of PSA canal to the alveolar crest</b>	17.2±3.6	(16.62,17.78)	14.45±3.83	(13.75,15.15)	0.043
<b>Distance from PSA canal to medial wall of sinus</b>	14.43±2.55	(14.02,14.84)	13.03±2.21	(12.64,13.42)	0.034
<b>PSA Canal diameter</b>	1.29±0.55	(1.21,1.37)	1.01±0.48	(0.93,1.09)	0.012

CI: Confidence interval, SD: Standard deviation

The lowest distance between the PSA canal and the medial sinus wall, ridge crest, and canal diameter was significantly higher in males ( $P<0.05$ ). A positive correlation was observed between the diameter of the PSA canal and the distance from the canal to the medial sinus wall with age in both the right and left sides ( $P<0.05$ ).

The maxillary sinus pathologies such as mucositis, sinusitis, mucous retention cyst, and mucosal thickening were detected on 129 (50%) CBCT scans, 59 (22.9%) right maxillary sinuses and 70 (27.2%) left maxillary sinuses. This difference was statistically significant in both males and females ( $P=0.043$ ), and males had higher frequency of maxillary sinus pathologies than females.

## Discussion

The aim of this study was to evaluate the detectability, position and diameter of the PSA canal and its relationship with the alveolar ridge on CBCT images. The PSA canal was detected on almost 78% of CBCT scans. The observers detected more PSA canals in their second observation. This shows that training and experience can significantly improve the rate of detection of the PSA canal. According to the classification of the PSA position, the most common type of PSA canal was intraosseous ( $>75\%$  in both males and females). This prevalence rate is almost similar to the rates reported by Ilguy et al.<sup>7</sup> and Guncu et al.<sup>1</sup> (68.2% and 71.1%, respectively). However, in the study conducted by Khojastehpour et al.<sup>11</sup> The most common type of PSA canal

was submucosal with a prevalence of 49.8%. This difference could be due to the use of different CBCT scanners and software programs.

The results of this study suggested that the PSA canal anatomy and position change with age. Sinus pathologies did not intervene with the detection of the PSA canal on CBCT scans. Gender significantly affected the position and diameter of the PSA canal ( $P<0.05$ ).

No significant difference was noted between males and females in detectability of the PSA canal in our study, which is in agreement with the results of Ilgüy et al.<sup>7</sup> However, Kim et al.<sup>2</sup> reported a higher prevalence rate in males (64%). The difference between their results and ours may be due to differences in the male-to-female ratio. In 2017, Tehranchi et al.<sup>12</sup> conducted a study to assess the detectability and position of the PSAA using CBCT scans. They indicated that the PSAA was beneath the membrane as often as it had an intraosseous location (47%), but in a small percentage of patients, the PSAA was detected on the external cortex of the lateral sinus wall (6%).

The distance between the PSA canal and the ridge crest was 8.2 to 17.81 mm in males and 7.5 to 16.23 mm in females. This distance is 18.9 to 19.6 mm in the anatomy reference books.<sup>13, 14</sup> In the study by Ilguy et al.<sup>7</sup> this distance was 2.94 to 17 mm in males and 9.64 to 14.91 in females. This difference may be due to variability in race and genetics between different populations.

The PSA canal diameter was  $1.32\pm 0.32$  mm in males and

1.01±0.23 mm in females. The mean canal diameter was significantly greater in males than females ( $P<0.05$ ), which is in line with other studies<sup>1, 2, 11</sup>; although in the study by Mardinger et al.<sup>6</sup> this difference was not statistically significant. It has been reported that cases of excessive bleeding occur when the PSA canal has a diameter larger than 2 mm.<sup>15</sup> Oliviera et al. reported that 10% of individuals would be at risk of profuse bleeding because of the presence of the PSA canal with a diameter greater than 2 mm, and males had higher prevalence of PSA canal with a diameter 3 times larger than that in females. In this study, the position and diameter of the PSA canal varied as age increased. This could be due to alveolar ridge resorption and loss of bone support in the posterior maxilla. Also, the PSA canal size increased with age. This could be due to lower efficiency of the systemic organs in the elderly, which may lead to higher need for blood supply and subsequent increase in canal diameter.<sup>14</sup> Mardinger et al.<sup>6</sup> and Khojastehpour et al.<sup>11</sup> also reported this incident.<sup>6, 11</sup> However, in the study by Guncu et al.<sup>1</sup> no significant correlation was seen between the PSA canal size and aging. Ding et al.<sup>15</sup> reported easier detection of the PSA canal in patients with osteoporosis.

In line with the study by Khojastehpour et al.<sup>11</sup> the distance between the PSA canal and the medial wall of the sinus and alveolar crest was reported to be higher in males than females, which could be due to larger craniofacial size in males.<sup>11</sup>

This study suggested higher prevalence of sinus pathologies in males than in females ( $P<0.05$ ). Previous studies such as those by Busaba et al.<sup>16</sup> also suggested significantly higher rates of chronic rhinosinusitis with polyposis in males. Ozdemir and Kavak<sup>17</sup> also detected significantly higher

incidental sinus abnormalities in males than females.

A previous study suggested that CBCT can detect 74.3% to 81.2% of the PSA canals, which is higher than CT. This difference could be due to higher resolution of CBCT images.<sup>18</sup>

The main advantage of this study was its relatively high sample size (514 sinuses) in comparison with previous studies.<sup>1, 6</sup> However, one of the limitations was the fact that CBCT scans with metal artifacts had lower image quality and therefore PSA localization was negatively affected.

## Conclusion

The results of this study showed that the most common type of PSA canal was “intraosseous” followed by “beneath the mucosal membrane” and on the “outer sinus wall”. Our results also indicated that as the age increased, the distance from the PSA canal to the alveolar ridge decreased and therefore, more attention should be paid in implant surgery in the posterior maxilla. Locating the PSA canal on CBCT scans prior to surgery can prevent complications during the surgical procedures.

## Acknowledgements

The authors would like to thank Dr. Mahshid Namdari for her special effort in statistical data analysis.

## Conflict of Interest

Non Declared ■

## References

- Güncü GN, Yildirim YD, Wang HL, Tözüm TF. Location of posterior superior alveolar artery and evaluation of maxillary sinus anatomy with computerized tomography: a clinical study. *Clin. Oral Impl. Res.* 2011 Oct;22(10):1164-7.
- Kim JH, Ryu JS, Kim K-D, Hwang SH, Moon HS. A radiographic study of the posterior superior alveolar artery. *Implant Dent.* 2011 Aug;20(4):306-10.
- Boyne PJ. Grafting of the maxillary sinus floor with autogenous marrow and bone. *J Oral Surg.* 1980;38:613-6.
- Summers RB. A new concept in maxillary implant surgery: the osteotome technique. *Compendium (Newtown, Pa).* 1994 Feb;15(2):152-4.
- Pandharbale AA, Gadgil RM, Bhoosreddy AR, Kunte VR, Ahire BS, Shinde MR, et al. Evaluation of the posterior superior alveolar artery using cone beam computed tomography. *Pol J Radiol.* 2016 Dec ;81:606-10.
- Mardinger O, Abba M, Hirshberg A, Schwartz-Arad D. Prevalence, diameter and course of the maxillary intraosseous vascular canal with relation to sinus augmentation procedure: a radiographic study. *Int J Oral Maxillofac Surg.* 2007 Aug;36(8):735-8.
- Ilguy D, Ilguy M, Dolekoglu S, Fisekcioglu E. Evaluation of the posterior superior alveolar artery and the maxillary sinus with CBCT. *Braz Oral Res.* 2013 Oct;27(5):431-7.
- Vogiatzi T, Kloukos D, Scarfe WC, Bornstein MM. Incidence of anatomical variations and disease of the maxillary sinuses as identified by cone beam computed tomography: a systematic review. *Int J Oral Maxillofac Implants.* 2014 Nov;29(6):1301-14.
- Varela-Centelles P, Loira-Gago M, Seoane-Romero J, Takkouche B, Monteiro L, Seoane J. Detection of the posterior superior alveolar artery in the lateral sinus wall using computed tomography/cone beam computed tomography: a prevalence meta-analysis study and systematic review. *Int J Oral Maxillofac Surg.* 2015 Nov;44(11):1405-10.
- Elian N, Wallace S, Cho S-C, Jalbout ZN, Froum S. Distribution of the maxillary artery as it relates to sinus floor augmentation *Int J Oral Maxillofac Implants.* 2005 Sep-Oct;20(5):784-7.
- Khojastehpour L, Dehbozorgi M, Tabrizi R, Esfandnia S. Evaluating the anatomical location of the posterior superior alveolar artery in cone beam computed tomography images. *Int J Oral Maxillofac Surg.* 2016 Mar;45(3):354-8.
- Tehranchi M, Taleghani F, Shahab S, Nouri A. Prevalence and location of the posterior superior alveolar artery using cone-beam computed tomography. *Imaging Sci Dent.* 2017 Mar;47(1):39-44.
- Traxler H, Windisch A, Geyerhofer U, Surd R, Solar P, Firbas

- W. Arterial blood supply of the maxillary sinus. *Clin. Anat.* 1999 Nov;12(6):417-21.
14. Solar P, Geyerhofer U, Traxler H, Windisch A, Ulm C, Watzek G. Blood supply to the maxillary sinus relevant to sinus floor elevation procedures. *Clinical Oral Implants Research.* 1999;10(1):34-44.
  15. Ding W-G, Yan W-h, Wei Z-X, Liu J-B. Difference in intraosseous blood vessel volume and number in osteoporotic model mice induced by spinal cord injury and sciatic nerve resection. *J Bone Miner Metab.* 2012 Jul;30(4):400-7.
  16. Busaba N, Sin H, Salman S. Impact of gender on clinical presentation of chronic rhinosinusitis with and without polyposis. *J Laryngol Otol.* 2008 Nov; 122(11): 1180-4.
  18. Özdemir M, Kavak RP. Season, age and sex-related differences in incidental magnetic resonance imaging findings of paranasal sinuses in adults. *Turk Arch Otorhinolaryngol.* 2019 Jun;57(2):61-7.
  19. Taschieri S, Rosano G. Management of the alveolar antral artery during sinus floor augmentation procedures. *J Oral Maxillofac Surg.* 2010 Jan;68(1):230.

**How to cite:**

Zahra Vasegh, Solmaz Valizadeh, Yaser Safi, Mitra Ghazizadeh Ahsaie, Yasaman Mohammadi. Evaluation of Posterior Superior Alveolar Canal on Cone Beam Computed Tomography Images. *J Dent Sch* 2019;37(2): 62-66.