



Diagnostic Accuracy of Reverse Contrast Enhancement for Detection of Vertical Root Fractures

Sanaz Sharifi Shoshtari ^a, Mona Rahmani ^b, Mohammad Deimi ^c, Maryam Alizad Rahvar ^d

^aAssistant Professor, Dept. of Oral & Maxillofacial Radiology. School of Dentistry, Ahvaz Jundishapur University of Medical Sciences, Ahvaz, Iran.

^bAssistant Professor, Dept. of Endodontics. School of Dentistry, Shahid Beheshti University of Medical Sciences, Tehran, Iran.

^cDentist, Ahwaz, Iran.

^dPostgraduate Student, Dept. of Oral & Maxillofacial Radiology. School of Dentistry, Shahid Beheshti University of Medical Sciences, Tehran, Iran.

Correspondence to Maryam Alizad Rahvar (email: alizadmaryam@gmail.com).

(Submitted: 31 December 2019 - Revised version received: 1 March 2020 - Accepted: 11 March 2020 - Published online: Summer 2020)

Objectives Vertical root fracture (VRF) is a common complication in endodontically-treated teeth. Due to its poor prognosis, a valid and reliable detection method is imperative for treatment planning. The aim of this study was to evaluate the application of reverse contrast in diagnosis of VRF by digital radiography.

Methods Fifty extracted single-rooted premolar teeth were selected for this in-vitro experimental study. The teeth were mounted in a dry mandible and fixed with wax. Radiographs were obtained of all teeth with 0° horizontal angle, and 0° and +15° vertical angle. VRFs were then created by a hammer in vertical direction. Radiographs were obtained again as previously described. Radiographs of each tooth were evaluated twice: once without reverse contrast and then with reverse contrast 2 weeks later. The weighted kappa coefficient was calculated to assess the inter-observer agreement. The sensitivity, specificity, positive predictive value (PPV), negative predictive value (NPV), positive likelihood ratio (LR+) and negative likelihood ratio (LR-) were compared in use and no use of reverse contrast using the Cochran Q test.

Results Radiographic angle had no significant effect on the diagnostic accuracy in use or no use of reverse contrast, except for the sensitivity value in no use of reverse contrast which was significantly higher in 15° vertical angle. The diagnostic accuracy of images enhanced with reverse contrast had no significant difference with original images in 0° and 15° vertical angles.

Conclusion Radiographs enhanced with reverse contrast had no significant difference with original radiographs for diagnosis of VRFs. Thus, for detection of VRFs, reverse contrast should only be considered as an adjunct.

Keywords Tooth Fractures; Radiography, Dental, Digital; Image Enhancement

Introduction

Vertical root fracture (VRF) refers to longitudinal hair-like cracks that are difficult to diagnose clinically and radiographically in early stages of their development.^{1, 2} Endodontically-treated teeth are at higher risk of VRF because of excessive removal of tooth structure and the stresses applied to the root canal wall during root canal instrumentation, filling of the root canal with gutta-percha, or inappropriate placement of intra-radicular posts.^{3, 4} These procedures create high level of stress labially and/or lingually and can cause root separation into coronal and apical fragments.⁵ In some cases, there are no signs and symptoms to detect VRFs even on routine conventional radiographs.^{1, 6} In early stages of development of subtle cracks, there might not be any separation of the segments and thus, the fracture may remain undetected for some time.⁷

On the other hand, VRF may cause nonspecific symptoms such as pain, swelling, mobility, periodontal packet, and sinus tract.⁸⁻¹¹ Radiographically, VRFs may cause bony developmental defects, halo lesions, perilateral radiolucency or angular resorption of crestal bone.^{11, 12} Therefore, early diagnosis of VRF can prevent excessive destruction of the tooth and periodontium.⁶ This background highlights the importance of diagnosis of VRFs for efficient treatment planning.²

Intraoral radiography is the most common imaging modality for detection of VRFs.⁶ The fracture can be manifested as a radiolucent line if the central ray of the X-ray beam is oriented parallel to the fracture line.⁶ Nowadays, film-based radiography has been broadly replaced with the digital imaging systems, which have many potential benefits such as low patient radiation dose, real-time display, simple archiving and transfer, and elimination of processing and subsequent artifacts.^{13, 14} Image enhancement potential is one of the most important advantages of digital imaging.¹⁵ The digital imaging technology presents a multitude of options for advancement of visual quality of diagnostic images with the most appropriate enhancement techniques.^{16, 17} Reverse contrast is a digital image processing tool that changes a positive radiographic image to a negative radiographic image that can help in better image interpretation and comprehension by the observers.^{2, 17}

At present, 3D imaging modalities such as cone-beam computed tomography have become widespread because of their high precision and sensitivity for diagnosis of root fractures.^{18, 19} However, higher cost and radiation dose, difficult accessibility, and metal artifacts in comparison with intraoral radiography are considered as the limitations of cone-beam computed tomography.²⁰

This study was designed to evaluate the application of reverse contrast enhancement for the diagnosis of VRFs by

digital radiography.

Materials and Methods

The study was approved by the ethics committee of Jundishapur University of Medical Sciences (IR.AJUMS.DRC.REC.1395.90). Fifty extracted human mandibular or maxillary single-rooted premolar teeth with closed apices were selected for this in vitro experimental study. The sample size was calculated to be 40 assuming the minimum significant difference in sensitivity between the two groups to be 10%, 80% study power and the minimum level of significance to be 0.05.

All teeth were checked for probable fractures or any internal or external resorption and those with such defects were discarded. The teeth were mounted in a dry human mandible and fixed with wax. The dry mandible was then mounted in putty impression material on a board perpendicular to the ground for the purpose of immobilization.

Radiographs were obtained of all teeth at two different angulations: 0° horizontal angle and 0° and +15° vertical angle. We used photostimulable phosphor plates with 10 mA tube current and 70 kVp tube voltage. The photostimulable phosphor sensor was fixed at 10 cm distance from the X-ray tube. The exposure time was 0.16 s for all samples. Afterwards, VRFs were induced by a hammer in a perpendicular direction. The two segments of the fractured teeth were bonded to each other with superglue and they were mounted again in the dry mandible. Radiographs were repeated with the same exposure settings reported earlier. By doing so, we had two radiographs taken from different angles of each sound tooth (group A) and the same tooth with VRF (group B).

All radiographs were numbered and saved. Two independent observers (one oral and maxillofacial radiologist and one endodontist) evaluated each radiograph for the presence/absence of VRFs.

Radiographs of each tooth (with or without VRF) were inspected and evaluated twice: once without reverse contrast and then with reverse contrast 2 weeks later. We scored the radiographs from 0 to 4 as follows: 0 = fracture definitely not present, 1 = fracture probably not present, 2 = uncertain-unable to judge on the presence of VRF, 3 = fracture probably present, 4 = fracture definitely present.⁵ We assumed scores 0 and 1 as an intact root, scores 3 and 4 as a fractured root and score 2 was excluded from the analysis. The observers were allowed to use options such as zoom-in magnification and adjustment of brightness and contrast.

Data were analyzed using SPSS version 22.0 (SPSS, Chicago, IL, USA). The sensitivity, specificity, positive predictive value (PPV), negative predictive value (NPV), positive likelihood ratio (LR+) and negative likelihood ratio (LR-) of each mode (with reverse contrast versus without reverse contrast) for detection of VRFs were determined by the Cochran Q test. The level of significance was set at

0.05. The weighted kappa coefficient was calculated to assess the inter-observer agreement for each mode.

Results

As mentioned earlier, the sample size was calculated to be 40; but, we collected 50 teeth for the study. However, 10 out of 50 teeth fractured unfavorably and were excluded from the study. Thus, the statistical analysis was carried out on 40 teeth. The diagnostic values in use and no use of reverse contrast are illustrated in Tables 1 and 2, respectively. Accordingly, the radiographic angle did not affect the diagnostic accuracy of enhanced and original images. However, the sensitivity of the original images was significantly higher in 15° vertical angle (sensitivity: 0.6 in 15° vertical angle versus 0.35 in 0° vertical angle; $P < 0.05$).

Table 1- Comparison of the diagnostic accuracy of original digital images (without reverse contrast enhancement) at 0° and 15° angles

Diagnostic parameter	0°	15°	P-value
Sensitivity	0.35	0.6	0.021*
Specificity	0.8	0.75	0.592
Positive predictive value	0.64	0.71	0.587
Negative predictive value	0.45	0.35	0.297
Positive likelihood ratio	1.75	2.4	19.0
Negative likelihood ratio	0.81	0.53	0.512

Table 1- Comparison of the diagnostic accuracy of digital images enhanced with reverse contrast at 0° and 15° angles

Diagnostic parameter	0°	15°	P-value
Sensitivity	0.45	0.55	0.369
Specificity	0.9	0.85	0.499
Positive predictive value	0.82	0.79	0.775
Negative predictive value	0.38	0.35	0.710
Positive likelihood ratio	4.5	3.6	0.653
Negative likelihood ratio	0.52	1.6	0.547

When comparing the diagnostic value of images enhanced with reverse contrast versus original images in the two radiographic angles for detection of VRFs, there was no statistically significant differences between the two imaging modalities in 0° and 15° vertical angles regarding sensitivity, specificity, PPV, NPV, LR+ and LR- (Table 3).

Table 3- Comparison of digital images with and without reverse contrast enhancement at 0° and 15° vertical angles

Diagnostic parameters	Vertical angle (degrees)	With contrast	Without contrast	P-value
Sensitivity	0	0.45	0.35	0.359
	15	0.55	0.6	0.651
Specificity	0	0.9	0.8	0.210
	15	0.85	0.75	0.264
Positive predictive value	0	0.82	0.64	0.167
	15	0.79	0.81	0.467
Negative predictive value	0	0.38	0.45	0.456
	15	0.35	0.35	0.983
Positive likelihood ratio	0	4.53	1.75	0.189
	15	3.66	2.4	0.354
Negative likelihood ratio	0	0.61	0.81	0.491
	15	0.52	0.53	0.864

We assessed the inter-observer reliability between the radiologist and endodontist regarding the aforementioned

imaging protocols. When combining the results of enhanced and original images taken with the two radiographic angles, the radiologist showed significantly higher sensitivity than the endodontist for detection of VRFs ($P=0.043$). On the other hand, the endodontist had greater specificity and PPV than the radiologist for detection of VRFs ($P<0.001$ for specificity, and $P=0.03$ for PPV; Table 4, Figure 1). In general, the inter-observer agreement between the radiologist and endodontist for detection of VRFs was found to be 0.383 using the Kappa coefficient of agreement.

Table 4- Comparison of diagnostic parameters of radiologist and endodontist for detection of VRFs

Diagnostic parameter	Radiologist	Endodontist	P value
Sensitivity	0.65	0.54	0.043
Specificity	0.6	0.81	0.000
Positive predictive value	0.62	0.74	0.03
Negative predictive value	0.63	0.64	0.846
Positive likelihood ratio	1.62	2.84	0.138
Negative likelihood ratio	0.58	0.56	0.763

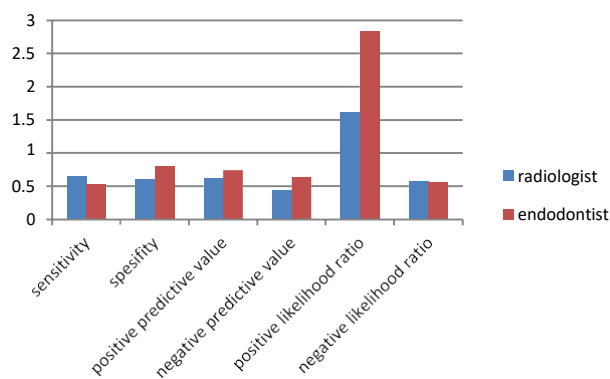


Figure 1- Comparison Of The Diagnostic Parameters Of Radiologist And Endodontist For Detection Of VRFs

Discussion

Diagnosis of VRFs is one of the main concerns of dental clinicians that require high precision.²¹ VRFs may be asymptomatic at first. However, over time, they have the ability to progressively destruct the periodontium and bone.⁶ Therefore, if root fractures are not detected at the right time, their restoration and future treatment would be difficult.² Accordingly, applying the most accurate imaging technique to identify VRF in early stages has always been a concern for dentists.

The advent of digital imaging revolutionized diagnosis and treatment planning in dentistry. This great innovation was the result of both technological advances in image acquisition and development of image retrieval and transfer systems.²² During the recent years, digital imaging systems have been used as an alternative to film-based radiography.^{13, 14} Evidence shows that the diagnostic accuracy of digital imaging is comparable to that of conventional film-based radiography.²³ Digital imaging systems have numerous

advantages such as lower patient radiation dose, elimination of chemical processing, and enabling electronic image transfer to other healthcare providers without any change in the original image quality.¹⁵ One of the important benefits of this system is image enhancement with special software programs.²⁴ However, the results of studies regarding the diagnostic value of different enhancement tools such as the reverse contrast of digital imaging software are controversial.^{6, 25} Considering the importance of early diagnosis of VRFs and the necessity of validated radiographic modalities for this purpose, this study aimed to compare the efficacy of reverse contrast filter of digital radiography with original digital images taken at 0° and 15° angles for detection of VRFs by two observers. The observers were allowed to adjust the contrast and brightness of images to compensate for the loss of image clarity. The analyses revealed that the diagnostic parameters did not differ by the presence or absence of reverse contrast ($P>0.05$). However, original images taken at 15° vertical angle had higher sensitivity in comparison with 0° angle for detection of VRFs ($P<0.05$). No such a difference was noted in images enhanced with the reverse contrast ($P>0.05$). Therefore, reverse contrast enhancement of digital images appears to bring little benefit in diagnosis of VRFs.

Several studies have examined the diagnostic accuracy of digital images and their enhancement for the diagnosis of various oral lesions, such as caries and root fractures. Our findings are in line with those of some other studies that reported that none of the used enhancement tools improved the diagnostic accuracy of digital images.²⁵ Moystad et al.²⁶ reported that enhancement of digital images did not result in any significant improvement in inter-observer or intra-observer agreement for detection of VRFs and dental caries. The findings of Kositbowornchai et al.²⁷ were parallel to those of an earlier study that showed no significant improvement in detection of VRFs using the zoom function of software at 1:1, 1:2, and 2:1 digital magnifications. In a study by Mehr-Alizadeh et al.,²⁸ reverse contrast images did not significantly increase the sensitivity, specificity and accuracy of VRF detection. Moreover, Brullmann et al.²⁵ reported that none of the noise reduction filters used for digital images significantly improved root fracture detection.

However, image enhancement tools may increase the recognition accuracy for other purposes. Kal et al.¹⁸ reported that reverse contrast, brightness and edge improved the accuracy of measuring the file length. On the other hand, Wenzel et al.²⁹ found that improvement of density, contrast and edges resulted in more accurate detection of caries especially on low-density images. In another study, image enhancement tools such as contrast and brightness features were found to be the most effective factors in increasing the detection of periapical lesions.³⁰ In a study by Tofangchiha et al.² the lowest sensitivity belonged to images enhanced with reverse contrast. Statistical analysis in the study by Tofangchiha et al.²

showed that the average sensitivity of colorized images was higher than that of the other two techniques, which indicated their higher efficacy for detection of root fracture. Original images had the highest specificity among all; therefore, false positive results are minimized with this technique. However, there was no significant difference with original images.

Controversy in the results of studies can be due to the sensitive nature of radiographic interpretations for diagnostic purposes and the fact that various factors can influence the observers and their decision, such as the imaging system (digital or film-based), monitor properties or film type, manipulation and enhancement of images, viewing conditions, and the observer's experience and expertise.^{27, 28} Therefore, in addition to the selected method for detection of dental lesions, it seems that visual conditions are also involved in the diagnostic accuracy of the observers. Thus, aside from the tool selected for improvement of the diagnostic efficacy of digital systems based on the target (task specific), the experience and expertise of the observer can also affect the results.^{2, 6, 28}

This study had an in vitro design, and presence/absence of bone and soft tissue in vitro may result in different responses to radiation compared with the oral cavity.² Therefore, the difference in the results of this study with other studies may be due to the differences in study design and methodology.

As previously mentioned, the radiologist had a higher sensitivity than the endodontist and the endodontist had a higher specificity than the radiologist in this study. The reason may be that radiologists more commonly encounter VRFs and are more acquainted with their radiographic features than endodontists. On the other hand, endodontists are more familiar with the radiographic features of sound roots.

Considering the importance of detection of VRFs as well as the increasing desire of dentists to use digital radiography, we suggest further studies with more radiographic angles to assess the efficacy of enhancement filters and their limitations, advantages and disadvantages to maximize the benefits of these diagnostic tools. Therefore, the reverse contrast filter can be considered as an adjunct, and not the exclusive diagnostic tool, for detection of VRFs.

Conclusion

The present study showed that images enhanced with reverse contrast had no significant difference with images without reverse contrast enhancement for diagnosis of VRFs.

Conflict of Interest

None Declared ■

References

1. Tsesis I, Kamburoglu K, Katz A, Tamse A, Kaffe I, Kfir A. Comparison of digital with conventional radiography in detection of vertical root fractures in endodontically treated maxillary premolars: an ex vivo study. *Oral Surg Oral Med Oral Pathol Oral Radiol Endod.* 2008Jul;106(1):124-8.
2. Tofangchiha M, Bakhshi M, Shariati M, Valizadeh S, Adel M, Sobouti F. Detection of vertical root fractures using digitally enhanced images: reverse-contrast and colorization. *Dent Traumatol.* 2012Dec;28(6):478-82.
3. Popescu SM, Diaconu OA, Scrieci M, Marinescu IR, Draghici EC, Trusca AG, et al. Root fractures: epidemiological, clinical and radiographic aspects. *Rom J Morphol Embryol* 2017 Jun, 58(2):501-6.
4. Queiroz PM, Nascimento HA, da Paz TD, Anacleto FN, Freitas DQ. Accuracy of Digital Subtraction Radiography in the Detection of Vertical Root Fractures. *J Endod.* 2016Jun;42(6):896-9.
5. Welbury R, Kinirons MJ, Day P, Humphreys K, Gregg TA. Outcomes for root-fractured permanent incisors: a retrospective study. *Pediatr Dent.* 2002 Feb;24(2):98-102.
6. Kamburoglu K, Murat S, Pehlivan SY. The effects of digital image enhancement on the detection of vertical root fracture. *Dent Traumatol.* 2010Feb;26(1):47-51.
7. Meister F, Jr., Lommel TJ, Gerstein H, Bell WA. An additional clinical observation in two cases of vertical root fracture. *Oral Surg Oral Med Oral Pathol.* 1981Jul;52(1):91-6.
8. Tamse A. Iatrogenic vertical root fractures in endodontically treated teeth. *Endod Dent Traumatol.* 1988Oct;4(5):190-6.
9. Meister F, Jr., Lommel TJ, Gerstein H. Diagnosis and possible causes of vertical root fractures. *Oral Surg Oral Med Oral Pathol.* 1980Mar;49(3):243-53.
10. Testori T, Badino M, Castagnola M. Vertical root fractures in endodontically treated teeth: a clinical survey of 36 cases. *J Endod.* 1993Feb;19(2):87-91.
11. Tamse A, Fuss Z, Lustig J, Kaplavi J. An evaluation of endodontically treated vertically fractured teeth. *J Endod.* 1999Jul;25(7):506-8.
12. Tamse A, Kaffe I, Lustig J, Ganor Y, Fuss Z. Radiographic features of vertically fractured endodontically treated mesial roots of mandibular molars. *Oral Surg Oral Med Oral Pathol Oral Radiol Endod.* 2006Jun;101(6):797-802.
13. White SC, Pharoah MJ. The evolution and application of dental maxillofacial imaging modalities. *Dent Clin North Am.* 2008Oct;52(4):689-705.
14. Nair MK, Nair UP. Digital and advanced imaging in endodontics: a review. *J Endod.* 2007Jan;33(1):1-6.
15. Yokota ET, Miles DA, Newton CW, Brown CE, Jr. Interpretation of periapical lesions using RadioVisioGraphy. *J Endod.* 1994Oct;20(10):490-4.
16. Mikrogeorgis G, Eirinaki E, Kapralos V, Koutroulis A, Lyroudia K, Pitas I. Diagnosis of vertical root fractures in endodontically treated teeth utilising Digital Subtraction Radiography: A case series report. *Aust Endod J.* 2018Dec;44(3):286-91.
17. Mol A. Image processing tools for dental applications. *Dent Clin North Am.* 2000Apr;44(2):299-318.
18. Kal BI, Baksi BG, Dundar N, Sen BH. Effect of various digital processing algorithms on the measurement accuracy of endodontic file length. *Oral Surg Oral Med Oral Pathol Oral Radiol Endod.* 2007Feb;103(2):280-4.
19. Versteeg KH, Sanderink GC, van Ginkel FC, van der Stelt PF.

- stimating distances on direct digital images and conventional radiographs. *J Am Dent Assoc.* 1997Apr;128(4):439-43.
20. Kobayashi-Velasco S, Salineiro FC, Gialain IO, CavalcanEti MG. Diagnosis of alveolar and root fractures: an in vitro study comparing CBCT imaging with periapical radiographs. *J Appl Oral Sci.* 2017Mar/Apr;25(2):227-33.
 21. Nascimento HA, Neves FS, de-Azevedo-Vaz SL, Duque TM, Ambrosano GM, Freitas DQ. Impact of root fillings and posts on the diagnostic ability of three intra-oral digital radiographic systems in detecting vertical root fractures. *Int Endod J.* 2015Sep;48(9):864-71.
 22. Oral radiology principles and interpretation, white and Pharoah's, 8th Edition, p 40
 23. Furkart AJ, Dove SB, McDavid WD, Nummikoski P, Matteson S. Direct digital radiography for the detection of periodontal bone lesions. *Oral Surg Oral Med Oral Pathol.* 1992Nov;74(5):652-60.
 24. Versteeg CH, Sanderink GC, van der Stelt PF. Efficacy of digital intra-oral radiography in clinical dentistry. *J Dent.* 1997May;25(3-4):215-24.
 25. Brullmann D, Witzel V, Willershausen B, d'Hoedt B. Effect of digital noise filters on diagnostic radiographs for the diagnosis of experimental root fractures. *Int J Comput Dent.* 2008Jan;11(2):107-14.
 26. Moystad A, Svanaes DB, van der Stelt PF, Grondahl HG, Wenzel A, van Ginkel FC, et al. Comparison of standard and task-specific enhancement of Digora storage phosphor images for approximal caries diagnosis. *Dentomaxillofac Radiol.* 2003Nov;32(6):390-6.
 27. Kositbowornchai S, Sikram S, Nuansakul R, Thinkhamrop B. Root fracture detection on digital images: effect of the zoom function. *Dent Traumatol.* 2003Jun;19(3):154-9.
 28. Mehralizadeh S, Mehrvarzfar P, Taghizadeh S, Edalat M, Mohebi M. Reverse contrast enhancement in digital radiography in detection of vertical root fracture (in vitro). *JDentMed.* 2015Jul;28(2):115-21.
 29. Wenzel A, Fejerskov O. Validity of diagnosis of questionable caries lesions in occlusal surfaces of extracted third molars. *Caries Res.* 1992;26(3):188-94.
 30. Kullendorff B, Nilsson M. Diagnostic accuracy of direct digital dental radiography for the detection of periapical bone lesions. II. Effects on diagnostic accuracy after application of image processing. *Oral Surg Oral Med Oral Pathol Oral Radiol Endod.* 1996Sep;82(5):585-9.

How to cite:

Sanaz Sharifi Shoshtari, Mona Rahmani, Mohammad Deimi, Maryam Alizad Rahvar. Diagnostic Accuracy of Reverse Contrast Enhancement for Detection of Vertical Root Fractures. *J Dent Sch* 2019;37(3):94-98.