

# A Systematic Review of Methods Used to Assess Mid-Palatal Suture Maturation

Arezoo Mahdian<sup>a</sup>, Shekoofeh Shaykhian<sup>b</sup>, Mohammad Behnaz<sup>c</sup>

<sup>a</sup>Postgraduate Student, Dept. of Orthodontics, School of Dentistry, Shahid Beheshti University of Medical Sciences, Tehran, Iran.

<sup>b</sup>Postgraduate Student, Dept. of Orthodontics, School of Dentistry, Kerman University of Medical Sciences, Kerman, Iran.

<sup>c</sup>Assistant Professor, Dept. of Orthodontics, School of Dentistry, Kerman University of Medical Sciences, Kerman, Iran.

Correspondence to Mohammad Behnaz (email: behnaz1357@yahoo.com).

(Submitted: 27 February 2019 – Revised version received: 18 May 2019 – Accepted: 19 May 2019 – Published online: Winter 2019)

**Objectives** Use of a reliable method to determine the degree of skeletal development of the mid-palatal suture is important in the choice of treatment between orthopedic maxillary expansion and surgical expansion in adolescents and young adults. The aim of this study was to review the methods for evaluation of mid-palatal suture maturation.

**Methods** Electronic search was conducted in PubMed and Scopus databases using the following key words: (“mid-palatal suture maturation” OR “mid-palatal suture ossification”) AND (“orthopedic treatment” OR “maxillary expansion” OR “orthodontic”) to find articles published from January 1990 to December 2018 in English that evaluated the mid-palatal suture maturation stage.

**Results** Of 127 papers found, 28 articles met the inclusion criteria and their full texts were reviewed. Finally, 8 met the inclusion criteria. Five studies used cone-beam computed tomography (CBCT) as the imaging modality and examined the quality of the mid-palatal suture maturation and assessed the morphology of the suture. Two studies used bone density and one study used fractal dimensions.

**Conclusion** Since all the innovative methods lack a gold standard and valid histological references, it is not possible to reach a comprehensive conclusion. It is therefore important that the clinicians use several diagnostic criteria for thorough evaluation of the development of mid-palatal suture and decide on the appropriate therapeutic modality.

**Keywords** Palatal Expansion Technique; Systematic Review; Palate; Hard

## Introduction

Maxillary deficiency in the transverse dimension is one of the common problems in the craniofacial area, which can lead to occlusal discrepancy, esthetic problems and functional disorders such as narrowing of the pharyngeal airway, an increase in the nasal resistance to the airflow and changes in the position of the tongue.<sup>1-4</sup> Maxillary bone constriction, which is diagnosed by the narrowness of the palate, leads to posterior crossbite in most cases. Posterior crossbite is a malocclusion with a relatively high prevalence rate during the mixed and permanent dentition period. The prevalence of this malocclusion was reported to be about 12% in the permanent dentition and 7.2% in the mixed dentition period by Hanson et al. (1970).<sup>5</sup> A study reported a prevalence rate of 12.4% for posterior crossbite in the Iranian population.<sup>6</sup> This malocclusion is more prevalent in girls than boys.<sup>7</sup> Crossbite and crowding which can be easily diagnosed are two signs of transverse maxillary deficiency. However, the buccal tipping of the posterior teeth could camouflage the transverse deficiency. Although these patients appear to have proper posterior occlusion, they in fact have transverse maxillary deficiency, with an increased Wilson Curve.<sup>7</sup>

Determining the appropriate time for maxillary expansion is one of the most challenging issues in orthodontic treatment. This treatment is possible prior to the closure and maturation of the suture.<sup>8</sup> The rate of dental and skeletal responses to maxillary expansion directly depends on the

degree of skeletal maturation of the mid-palatal suture. A large variation has been reported in the age of onset of closure of the mid-palatal suture. This variation has resulted in difficulty in predicting the response of the mid-palatal suture before treatment. This poses a major challenge for providing proper treatment for skeletal expansion, especially during the late adolescence period and in young adults.<sup>9</sup>

Wrong prediction of the amount of closure of the mid-palatal suture before treatment can lead to incorrect selection of the expansion method and increasing the risk of iatrogenic complications, including acute pain, periodontal injury, mucosal necrosis, open bite, severe buccal tipping of the teeth, poor stability of the occlusion in the lateral dimension, unnecessary additional costs, a long healing period and potential surgical complications.<sup>10</sup> Sexual maturity, dental age, height and development index based on hand-wrist radiographic analysis are the most important biological indices for evaluation of growth.<sup>11</sup> Tooth development indices are not reliable predictors for skeletal maturation.<sup>12, 13</sup>

There is a close relationship between the time of height growth spurt during the puberty and the development of facial bones. The long-term growth records of the body height can be used in orthodontic treatment planning; however, these growth records are usually rarely available for craniofacial structures. Even if sufficient records are available, it is difficult to determine the puberty growth spurt because in 30% of the girls and 20% to 30% of the

boys the growth rate during the spurt is too small to be clinically detectable.<sup>14</sup>

Use of secondary sexual characteristics cannot be a precise index to determine the stage of skeletal maturation because evidence shows that there might be approximately 6 years of difference in the incidence of sexual characteristics in both genders.<sup>15</sup> Unfortunately, most orthodontists routinely use chronological age to determine the correct time for maxillary expansion. Due to the influence of the time factor on the complexity of diversity phenomenon and individual differences in time, duration and rate of growth, the chronological age is not usually a good indicator for the growth status of an individual.<sup>16</sup>

Considering what was discussed above, use of a reliable biological index is important to determine the extent of skeletal maturation of mid-palatal suture in order to examine the possibility of orthopedic maxillary expansion.<sup>17</sup> Various methods have been developed to evaluate the mid-palatal suture maturation. Some of these methods include human and animal histological studies, occlusal radiographs and computed tomography scans on human and animal samples. The aim of this study was to review and evaluate new methods and technologies for assessment of the maturity of mid-palatal suture.

## Materials and Methods

This systematic review used PRISMA 2010 Declaration to evaluate previous studies on the mid-palatal suture maturation.

This study included clinical studies that provided a practical and non-invasive method for evaluation of the mid-palatal suture maturity. Studies that evaluated the degree of mid-palatal suture maturation based on invasive methods, such as sampling and histological studies, were excluded. In addition, articles that evaluated the extent of bone formation in the mid-palatal suture in people with special conditions such as cleft palate, skeletal and metabolic diseases, use of medications that affect the growth and development or patients after maxillary expansion, were excluded. In vivo studies and case reports were not eligible for inclusion in this study.

Electronic search was conducted in PubMed and Scopus databases using the following key words: ("mid-palatal suture maturation" OR "mid-palatal suture ossification") AND ("orthopedic treatment" OR "maxillary expansion" OR "orthodontic\*").

This search was carried out in December 2018 and was limited to studies published in English from January 1990 to December 2018. In addition, any method that was used to evaluate the mid-palatal suture maturation in the reviewed articles was also searched. Finally, the bibliography of the included articles was reviewed and each study that provided a method for assessing the mid-palatal suture was included in this study.

Two reviewers performed the screening and data extraction.

Disagreements were resolved by discussion. After a thorough search of the databases, a preliminary screening was performed based on the titles and abstracts of the retrieved articles. Then, the full texts of the selected articles were examined according to the inclusion and exclusion criteria. Subsequently, a search was carried out in the bibliography of the articles that were included in the study. Finally, the methods that were used to evaluate skeletal age for orthopedic treatments were retrieved and evaluated. These methods included suture obliteration evaluation using bone density, assessment of mid-palatal suture morphology based on cone-beam computed tomography (CBCT) images and fractal dimension method.

The following information was extracted from the studies: type of study, sample size, sample age, quantitative or qualitative study, imaging modality, parameters used to evaluate mid-palatal suture maturity and outcome.

The methods presented in these studies were not compared with each other and were simply described in a qualitative manner.

## Results

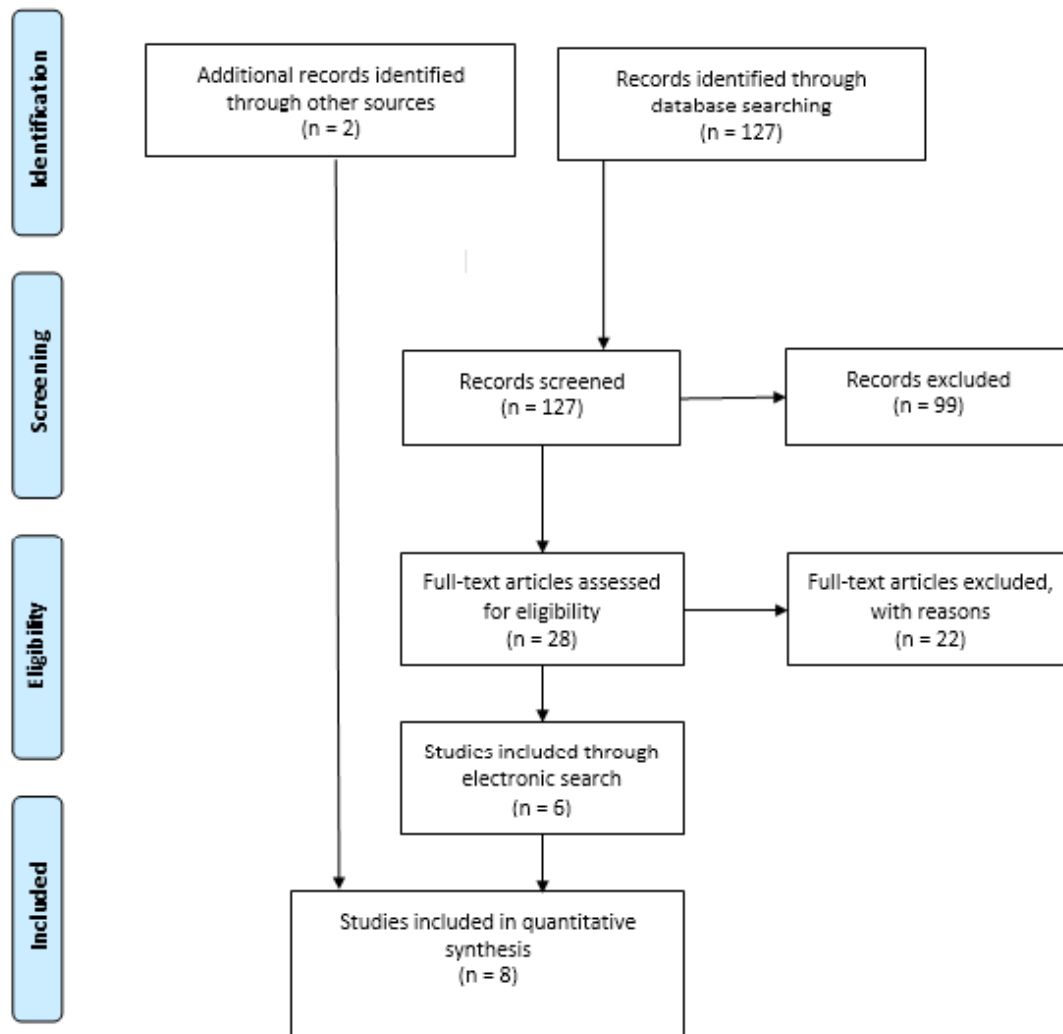
The search flowchart of the study is shown in Figure 1. During the electronic search, 127 titles were found that decreased to 28 articles after screening by title and abstract. Finally, considering the inclusion and exclusion criteria, 6 papers were included.<sup>18-24</sup> After reviewing the bibliography of the selected articles, 2 other studies were found to be eligible to be included in this review.<sup>25, 26</sup> Therefore, finally 8 studies evaluating the mid-palatal suture maturation were selected for this systematic review. Data extracted from the studies are presented in Table 1. All of the studies had a cross-sectional design.

The number of samples varied from 21<sup>18</sup> to 165.<sup>27</sup> Nine CBCT and a CBCT and occlusal radiography study<sup>18</sup> were reviewed to evaluate the mid-palatal suture maturation. In 4 studies,<sup>18, 20, 27, 28</sup> the quantitative criteria were used for assessing the mid-palatal suture maturation; in one study,<sup>19</sup> both quantitative and qualitative criteria were used and in other studies,<sup>21, 22, 24-26</sup> a quantitative technique was used. One study used fractal analysis;<sup>20</sup> 5 studies used the shape and degree of complexity of the mid-palatal suture,<sup>21, 22, 24-26</sup> one study used suture obliteration index,<sup>18</sup> one study used both bone density of mid-palatal suture and examined the shape and degree of complexity of mid-palatal suture<sup>23</sup> and another study used the obliteration index, interdigitating index and bone density to evaluate the maturation of the mid-palatal suture.<sup>19</sup>

A study by Kwak et al. (2016)<sup>20</sup> introduced the use of fractal dimension as a reliable method. Other studies<sup>18, 19, 21, 22, 24-26</sup> emphasized on the necessity of examining the maturity of mid-palatal suture using CBCT and did not consider the chronological age and gender as suitable indices for this assessment. In one study, the accuracy of occlusal radiography and the axial view of CBCT were

compared for assessing the suture density, and the results indicated lower accuracy of occlusal radiography compared

with CBCT<sup>18</sup>.



**Figure 1- The Search Strategy**

**Table 1-** Summary of articles included in this study

Authors	Number of samples	Age of samples (yrs.)	Quantitative/ qualitative	Imaging modality	Parameter used to evaluate mid-palatal suture maturation	Result
Thadani et al. (2010) <sup>18</sup>	21	8-25	Quantitative	CBCT/occlusal radiography	Suture obliteration index	In both age groups, the density shown by the CBCT image was less than that shown by occlusal radiography.
Angelieri et al. (2013) <sup>21</sup>	140	5.6-58.4	Qualitative	CBCT	Mid-palatal suture morphology	Stages A and B were typically up to the age of 13 years; stage C was mainly between 11 and 17 years of age; stages D and E were after 11 years of age in girls, and stage D was between 14-17 years seen in only 23% of boys.
Kwak et al. (2016) <sup>20</sup>	131	4.53-18.1	Quantitative	CBCT	Fractal dimension	There was a strong negative correlation between fractal dimension and mid-palatal suture maturation.
De Miranda Ladewig et al. (2018) <sup>25</sup>	112	16-20	Qualitative	CBCT	Mid-palatal suture morphology	Stages C, D and E were seen in 91.9% of the cases; 51.3% of the males and 39.7% of females were in stage C.

Angelieri et al (2016) <sup>23</sup>	78	18-46	Qualitative	CBCT	Mid-palatal suture morphology	The majority of adults were in the D and E stages of mid-palatal suture maturation. In 12% of the cases, the suture was not completely closed.
Samra and Hadad (2018) <sup>19</sup>	95	8-18	Quantitative /qualitative	CBCT	Bone density of mid-palatal suture/Mid-palatal suture morphology	The highest density in the palatal area was in the maxillary region in stages D and E. The density can be used to determine the amount of complexity of the suture.
Haghanifar et al. (2017) <sup>22</sup>	144	10-70	Qualitative	CBCT	Mid-palatal suture morphology	Strong correlation was observed between the maturity of mid-palatal suture and age in both sexes  Stage A was only seen in an 11-year-old girl. Stage B was seen in all ages, but more commonly in those younger than 13 years of age and stage C was observed in all ages. Stages D and E were found with a lower incidence.
Tonello et al. (2017) <sup>24</sup>	84	11-15	Qualitative	CBCT	Mid-palatal suture morphology	The early stages of suture maturation were more common in boys.

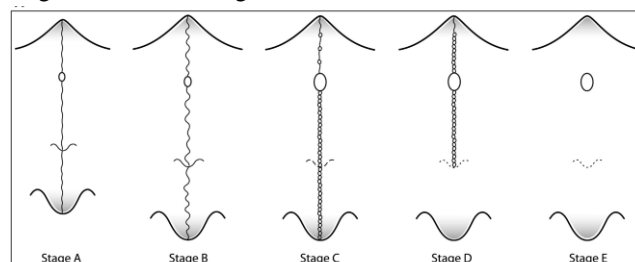
## Discussion

There is a great deal of disagreement about the time of maxillary expansion, as well as decision making between rapid maxillary expansion and surgically-assisted rapid maxillary expansion. Some authors suggest surgery for patients over 14 years of age,<sup>29</sup> while others believe that surgery should only be considered for men older than 25 years of age and women older than 20 years.<sup>30</sup> There are also different perspectives on the time of mid-palatal suture closure. Because of the many individual variations in mid-palatal suture maturation, the chronological age cannot be a good predictor of treatment outcomes. Therefore, an individual assessment must be made before deciding on the maxillary expansion method. Different methods, such as measuring the bone density of mid-palatal suture, sampling and microscopic examination, morphological study and the degree of complexity of the mid-palatal suture, have been reported in the literature. In this review, the most practical and least invasive methods were reviewed, along with an examination of the advantages and disadvantages of each one.

To evaluate the mid-palatal suture maturity, the first step is to select an acceptable standard that indicates the midline maturation or immaturity. In 2013, Angelieri et al,<sup>21</sup> in Brazil presented an innovative method to classify the maturity status of the mid-palatal suture using an axial cross-section of CBCT images. In this classification, based on the mid-palatal suture morphology, 5 developmental stages of A-E were identified. It was determined that the final stages of D and E represent the suture fusion. It has been suggested that in these steps, there is no possibility to open the suture by rapid palatal expansion.<sup>21</sup> This classification is generally accepted and most studies that took place subsequently used this classification.<sup>19, 20, 22, 24-26</sup>

Morphologically, the stages of puberty of the suture include

A: a dense and straight sharp line; B: scallop-shaped structures with high density in the mid-palatal suture; C: two high-density scalloped parallel lines separated in some regions by low-density regions; D: complete fusion of palatal bone without any sign of residual suture; and E: complete fusion of the anterior part of the maxilla. These stages are shown in Figure 2.



**Figure 2- Stages of mid-palatal suture maturation**

Several studies<sup>22, 24-26</sup> have shown little or no correlation between the chronological age, sex and developmental stages of mid-palatal suture, and none is a good predictor of the maturity of this suture. These studies suggest that CBCT is a reliable method for assessment of the degree of closure of mid-palatal suture and the decision to choose the type of treatment. However, in a study by Haqqani Far et al,<sup>22</sup> on an Iranian population, the results showed a significant correlation between age and progression of the developmental stages of mid-palatal suture ( $r = 0.681$ ). The authors did not consider the chronological age as a valid indicator for assessing the development of the mid-palatal suture and emphasized on the necessity of using CBCT to study the morphology of the suture and its development. Tonello et al.<sup>24</sup> showed that in the 11 to 15-year-old age group, 76.2% of the patients were in stages A to C and had good prognosis for maxillary expansion. After age 15, gender becomes more important. According to de Miranda Ladewig et al,<sup>25</sup> males aged 16 to 20 years are more

probable to be in the developmental stage C than females and in general, in both sexes, stage C is the most common stage in this age group.

Because one of the constraints and problems of categorizing the maturity of the mid-palatal suture is the subjectivity and difficulty in finding the suture on CBCT images, two studies evaluated the validity of complementary methods. Samar and Hadad<sup>19</sup> measured bone density in this area. According to their results, the density of suture increased with the progression of the developmental stage from A to E. However, there was a significant increase between stage E and previous stages. According to the authors, due to the impossibility of comparing the gray scale values between different CBCT scanners, it seems that the use of morphology of the suture to evaluate the development of the mid-palatal suture is more practical and reliable than bone density measurements. In another study, Kwak et al.<sup>20</sup> used fractal analysis, which is a quantitative and objective method. This method, which previously was used to evaluate sutures of the skull in mammals, was applied for the first time in combination with CBCT to evaluate the mid-palatal suture maturation. The analyses indicated that the developmental stages B to E had a significant relationship with the mean fractal dimension variations and there was a negative correlation between the developmental stages and fractal dimension ( $-0.623$ ,  $P < 0.001$ ). Based on the results, fractal analysis can be a good alternative to the Angeliери approach.<sup>21</sup> The advantages of this method are its quantitative and objective nature. The major disadvantage of this method is the need for a remarkable familiarity with image processing and software applications and complex analyses to calculate fractal dimension. This method is also time-consuming and costly.

Despite the applicability of the criteria introduced by Angeliери et al.,<sup>21</sup> to assess the development of mid-palatal suture, the limitations of this criterion are the existence of a classification based on the morphology of the suture and the lack of a gold standard to determine the shape of the suture, qualitative and subjective examination, and the absence of examination of samples with close age proximity to each other. Therefore, its validity and reliability remain questionable. Its validity should be evaluated with clinical and animal studies and its reliability should be improved by making this criterion more objective.

One of the other limitations of all the included studies was their methodology since all of them had a cross-sectional design. The studies lacked clinical evaluation to confirm the categorization of mid-palatal suture maturation. Therefore,

it is necessary to evaluate this criterion with measurable and objective clinical criteria such as opening of the mid-palatal suture after rapid palatal expansion and histological studies in the future. In addition, if more objective and valid methods are used, such as fractal analysis or ultrasonography to substitute subjective methods for classifying the suture maturation, the reliability of the measurements would increase.

Finally, the need to use CBCT to evaluate the mid-palatal suture maturation is another limitation of this approach. CBCT increases the X-ray exposure of patients and according to the ALARA protocol (as low as diagnostically acceptable), it should be requested only when necessary. The study by Thadani et al.<sup>18</sup> showed that evaluation of mid-palatal suture maturation by CBCT is more reliable than occlusal radiography, and accuracy of occlusal radiography and CBCT is only comparable in the anterior maxillary region. Despite the advice of most researchers that CBCT is required to evaluate the mid-palatal suture maturation, this method has not yet been widely used by the clinicians. Therefore, determining the relationship between mid-palatal suture maturation and skeletal age evaluation methods such as cervical vertebral maturation can help decrease the patient radiation dose, and result in greater acceptance of this approach by the clinicians.

## Conclusion

Because of the differences in sample size, the age groups, evaluation method, and heterogeneity of the results, it was not possible to carry out a meta-analysis or direct comparisons between the results of the studies. This restricted the provision of a conclusive conclusion about the new methods for evaluation of the mid-palatal suture maturity. All the proposed methods lack standards and valid histological references. Thus, it is important that clinicians use several diagnostic criteria to evaluate the development of the mid-palatal suture and decide on the appropriate modalities of treatment in young adult patients. The use of CT scans should be considered as an ethical consideration in order to assess the mid-palatal suture, and should be used following the ALARA protocol. The use of more conservative imaging technologies from a biological viewpoint, such as ultrasonography, is recommended for future studies in order to assess the mid-palatal suture development.

## References

1. Vidya V, Sumathi F. Rapid maxillary expansion as a standard treatment for obstructive sleep apnea syndrome: a systematic review. *IOSR-JDMS*. 2015 Feb;14:51-5.
2. Aloufi F, Preston CB, Zawawi KH. Changes in the upper and lower pharyngeal airway spaces associated with rapid maxillary expansion. *ISRN Dentistry*. 2012;2012.
3. De Rossi M, De Rossi A, Hallak JEC, Vitti M, Regalo SCH. Electromyographic evaluation in children having rapid maxillary expansion. *Am J Orthod Dentofacial Orthop*. 2009 Sep;136(3):355-60.
4. McNamara JA. Maxillary transverse deficiency. *Am J Orthod Dentofacial Orthop*. 2000 May;117(5):567-70.



5. Hanson MI, Barnard LW, Case JL. Tongue-thrust preschool children. Part II dental occlusal patterns. *Am J Orthodont.* 1970 Jan;57(1):15-22.
6. Borzabadi-Farahani A, Borzabadi-Farahani A, Eslamipour F. Malocclusion and occlusal traits in an urban Iranian population. An epidemiological study of 11-to 14-year-old children. *Eur J Orthod.* 2009 May;31(5):477-84.
7. Johnson E, Larson B. Thumb-sucking: literature review. *ASDC J Dent Child* 1993 Nov-Dec;60(4):385-91.
8. Dhiman S, Maheshwari S, Verma SK. Assessment of maturity in orthodontics: A review. *J Adv Clinical & Res Insights.* 2015 Mar-Apr;2(2):101-10.
9. Baccetti T, Franchi L, Cameron CG, McNamara Jr JA. Treatment timing for rapid maxillary expansion. *Angle Orthod.* 2001 Oct;71(5):343-50.
10. Isfeld D, Flores-Mir C, Leon-Salazar V, Lagravère M. Evaluation of a novel palatal suture maturation classification as assessed by cone-beam computed tomography imaging of a pre-and postexpansion treatment cohort. *Angle Orthod.* 2018 Mar; 89(2); 252-61.
11. Hassel B, Farman AG. Skeletal maturation evaluation using cervical vertebrae. *Am J Orthod Dentofacial Orthop.* 1995 Jan;107(1):58-66.
12. Sağlam AMŞ, Gazilerli Ü. The relationship between dental and skeletal maturity. *J Orofac Orthop/Fortschritte der Kieferorthopädie.* 2002 Mar;63(6):454-62.
13. Uysal T, Sari Z, Ramoglu SI, Basciftci FA. Relationships between dental and skeletal maturity in Turkish subjects. *Angle Orthod.* 2004 Oct;74(5):657-64.
14. Hagg U, Taranger J. Menarche and voice change as indicators of the pubertal growth spurt. *Acta Odontol Scand.* 1980 Jan;38(3):179-86.
15. Flores-Mir C, Nebbe B, Major PW. Use of skeletal maturation based on hand-wrist radiographic analysis as a predictor of facial growth: a systematic review. *Angle Orthod.* 2004 Feb;74(1):118-24.
16. Proffit WR, Fields HW, Sarver DM. Contemporary orthodontics. 4th ed. St Louis: Mosby Elsevier; 2007. p. 16,267,651.
17. Baccetti T, Franchi L, McNamara JA, Jr. An improved version of the cervical vertebral maturation (CVM) method for the assessment of mandibular growth. *Angle Orthod.* 2002 Aug;72(4):316-23.
18. Thadani M, Shenoy U, Patle B, Kalra A, Goel S, Toshinawal N. Midpalatal suture ossification and skeletal maturation: a comparative computerized tomographic scan and roentgenographic study. *J Indian Acad Oral Med Radiol.* 2010 Apr-Jun;22(2):81.
19. Samra DA, Hadad R. Midpalatal suture: evaluation of the morphological maturation stages via bone density. *Prog Orthod.* 2018 Aug 13;19(1):29.
20. Kwak KH, Kim SS, Kim YI, Kim YD. Quantitative evaluation of midpalatal suture maturation via fractal analysis. *Korean J Orthod.* 2016 Sep;46(5):323-30.
21. Angelieri F, Cevidanes LH, Franchi L, Gonçalves JR, Benavides E, McNamara Jr JA. Midpalatal suture maturation: classification method for individual assessment before rapid maxillary expansion. *Am J Orthod Dentofacial Orthop.* 2013 Nov;144(5):759-69.
22. Haghanifar S, Mahmoudi S, Foroughi R, Mir APB, Mesgarani A, Bijani A. Assessment of midpalatal suture ossification using cone-beam computed tomography. *Electron Physician.* 2017 Mar 25;9(3):4035-41.
23. Angelieri F, Franchi L, Cevidanes LH, Bueno-Silva B, McNamara JA Jr. Prediction of rapid maxillary expansion by assessing the maturation of the midpalatal suture on cone beam CT. *Dental Press J Orthod.* 2016 Nov-Dec;21(6):115-25.
24. Tonello DL, de Miranda Ladewig V, Guedes FP, Conti ACdCF, Almeida-Pedrin RR, Capelozza-Filho L. Midpalatal suture maturation in 11-to 15-year-olds :A cone-beam computed tomographic study. *Am J Orthod Dentofacial Orthop.* 2017 Jul;152(1):42-8.
25. Ladewig VM, Capelozza-Filho L, Almeida-Pedrin RR, Guedes FP, de Almeida Cardoso M, de Castro Ferreira Conti AC. Tomographic evaluation of the maturation stage of the midpalatal suture in postadolescents. *Am J Orthod Dentofacial Orthop* 2018 Jun;153(6):818-24.
26. Angelieri F, Franchi L, Cevidanes L, Gonçalves J, Nieri M, Wolford L, et al. Cone beam computed tomography evaluation of midpalatal suture maturation in adults. *Int J Oral Maxillofac Surg.* 2017 Dec;46(12):1557-61.
27. Kang D, Kwak KH, Kim SS, Park SB, Son WS, Kim YI. Application of fractal analysis of the midpalatal suture for estimation of pubertal growth spurts. *Oral Radiol.* 2017 Sep;33(3):199-203.
28. Abat C, Raoult D, Rolain J-M. Low level of resistance in enterococci isolated in four hospitals, Marseille, France. *Microb Drug Resist.* 2016 Apr;22(3):218-22.
29. Mommaerts M. Transpalatal distraction as a method of maxillary expansion. *Br J Oral Maxillofac Surg.* 1999 Aug;37(4):268-72.
30. Alpern MC, Yurosko JJ. Rapid palatal expansion in adults: with and without surgery. *Angle Orthod.* 1987 Jul;57(3):245-63.

**How to cite:**

Arezoo Mahdian, Shekoofeh Shaykhan, Mohammad Behnaz. A Systematic Review of Methods Used to Assess Mid-Palatal Suture Maturation. *J Dent Sch* 2019;37(1):26-31.