

# Evaluation of Root Canal Morphology and Root Apex Anatomy of Mandibular Premolars in an Iranian Population: an ex-vivo study

Mandana Naseri<sup>a</sup>, Mohammad Ali Mozayeni<sup>b</sup>, Nahid Adelhani<sup>c</sup>, Atefeh Gohari<sup>d</sup>

<sup>a</sup>Associate Prof., Iranian Center for Endodontic Research, Research Institute of Dental Sciences, Dept. of Endodontics, School of Dentistry, Shahid Beheshti University of Medical Sciences, Tehran, Iran.

<sup>b</sup>Professor, Dept. of Endodontics, School of Dentistry, Shahid Beheshti University of Medical Sciences, Tehran, Iran.

<sup>c</sup>Private Practice, Tehran, Iran

<sup>d</sup> Postgraduate student, Dept. of Endodontics, School of Dentistry, Shahid Beheshti University of Medical Sciences, Tehran, Iran.

Correspondence to Atefeh Gohari (email: atp.gohari@gmail.com).

(Submitted: 17 March 2019 – Revised version received: 24 April 2019 – Accepted: 4 May 2019 – Published online: Winter 2019)

**Objectives** Adequate knowledge about canal anatomy is necessary for clinicians to prevent any damage to the periodontium. The aim of this study was to evaluate the canal and apical complexities of the mandibular first and second premolars in an Iranian population.

**Methods** One-hundred mandibular first (n=50) and second (n=50) premolars were collected. After access cavity preparation, 2% methylene blue was injected into the canals, and they were sealed with Coltisol and nail varnish. Next, demineralization and clearing with 5% nitric acid and methyl salicylate were performed. Apical morphology including the presence of accessory canals, apical delta, anastomoses and canal configurations was evaluated under a stereomicroscope at x16 magnification. Descriptive statistics (including tables, central tendency and dispersion tests) were used for data analysis.

**Results** The most prevalent form of canal type was Vertucci's type I in first and second premolars. The mean distance between the apical foramen and anatomic apex, apical foramen and apical constriction, and apical constriction and anatomic apex was 0.3, 0.6 and 0.9 mm, respectively for the first premolars. These values were 0.3, 0.5 and 0.8 mm, respectively for the second premolars.

**Conclusion** Although most mandibular premolars have one canal, using appropriate cleaning methods is imperative because of high prevalence of accessory canals, anastomoses and apical deltas. First premolars pose more challenges in this respect.

**Keywords** Tooth Apex; Root Canal Therapy; Bicuspid; Mandible

## Introduction

Adequate knowledge about the anatomy of the apex and the root canal system is necessary to prevent damage to the periodontal ligament<sup>1</sup>. Some clinicians use the terms “apex” and “apical Foramen” as synonyms<sup>2</sup>. The anatomic apex (AA) is defined as the tip of the root, the farthest part from the occlusal table; while the apical foramen (AF) is the point at which the root canal exits the root and faces the periodontal ligament. It does not necessarily conform to AA and may be located mesially, distally, buccally or lingually relative to the apex. The apical constriction (AC) is the part of the root canal with the smallest diameter and is considered as the reference point for clinicians for apical termination limit in enlargement, cleaning, disinfection and filling procedures<sup>3</sup>. AF to AC and AA to AF distances are of high importance in determining the accurate working length and achieving a successful treatment<sup>4</sup>.

According to a study by Washington<sup>5</sup>, mandibular first premolars have the highest failure rate, probably due to wide variations in their root canal morphology and higher incidence of untreated extra-canals. Several studies have shown that the incidence of different root canal configurations in mandibular premolars may vary among

different ethnic or regional populations<sup>6-8</sup>. Clinicians must consider these variations in the root canal morphology and configurations in different races during endodontic treatment<sup>9</sup>.

There are several methods to study the root canal anatomy and morphology, such as cross-sectioning<sup>10</sup>, grinding<sup>11</sup>, conventional radiography<sup>12</sup>, cone-beam computed tomography (CBCT)<sup>13, 14</sup>, micro-CT<sup>15</sup> and clearing and injection of dye.<sup>16-20</sup>

Several studies have been performed to evaluate root canal morphology of mandibular premolars in the Iranian population. But, none of them evaluated the prevalence of anastomoses and accessory canals.

This study was conducted to assess the morphological indices in the apical area including AC to AF, AF to AA and AA to AC distances and to evaluate the position of AF relative to the AA (deviations), the presence of deltas and accessory canals and the canal morphology in the mandibular first and second premolars in an Iranian population.

## Materials and Methods

The study protocol was approved by ethics committee of

Shahid Beheshti University of Medical Sciences (No. 21 in 16th meeting of ethics committee of Research Institute of Dental Sciences on 28 Feb. 2012). This descriptive cross sectional, ex-vivo study evaluated 50 extracted mandibular first premolars and 50 second premolars that had been collected from dental clinics of Tehran during one year and were stored in saline<sup>21</sup>. All 22 municipal districts of Tehran were pooled and the samples were randomly selected using a table of random numbers. The sample size was calculated according to a study by Safi et al,<sup>11</sup> using Minitab software (Minitab 16 statistical software. Minitab Inc., State College, Pennsylvania, USA). The reason of extraction, age and gender of patients was not known. All the selected teeth had complete apices, intact roots and no root fracture or apical resorption. The calculus and soft or hard tissue residues were removed from the tooth surfaces and all samples were disinfected with 5.25% sodium hypochlorite (Golrang Co., Pakshou, Tehran, Iran) for 24 hours and stored in 0.9% saline. The ASH criteria<sup>22</sup> for distinction between the first and second premolar anatomy, was used in this study. Teeth that were difficult to distinguish were excluded.

Access cavity was prepared using a fissure diamond bur (Jota AG, Rüthi, Switzerland) with high-speed handpiece (Kavo, West, Germany). A DG16 endodontic explorer was used to negotiate the canal orifice and make sure that no roof remained. A size 6 or 8 K-file (Maillefer, Ballaigues, Switzerland) was placed in the canal and the distance between the AF (where the file tip was visible on the outer surface of the root) and AA and also the position of AF in relation to AA were recorded under a stereomicroscope (DP12 SZX9; Olympus, Tokyo, Japan) at x16 magnification. The teeth were soaked in 5.25% sodium hypochlorite for 48 hours to dissolve the organic debris in the root canal system and washed under running tap water for 4 hours in order to eliminate debris. The root canals were dried to some extent using # 20 absorbent paper points (Aria Dent, Tehran, Iran). Dye injection was done in two steps with and without suctioning; 2% methylene blue (Merck Millipore, Darmstadt, Germany) was injected with a 27-gauge insulin syringe. Then, this procedure was repeated while at the same time negative pressure of about 25 mmHg was applied from the root apex using a central suctioning system, in

order to allow the dye to exit the canal. Finally, the access cavities were temporarily restored with Coltosol (Aria Dent, Tehran, Iran) and wet cotton was applied on it for 10 minutes. Two layers of nail varnish were applied on the temporary restoration, especially on the margins. All the teeth were immersed in 5% nitric acid solution (Merck Millipore, Darmstadt, Germany) at room temperature (20°C) for three days<sup>23</sup>. The solution was agitated by hand using a stainless steel spoon, 3 times a day and changed daily. Subsequently, complete decalcification of the samples was examined using an explorer (by inspecting and tactile sensation). If complete decalcification was not apparent, the tooth was compared with an intact tooth using X-ray. Again, rinsing with tap water for another 4 hours and dehydration with 17% ethyl alcohol (Ararat Co., Tehran, Iran) for 24 hours were performed. The dehydrated teeth were then placed in methyl salicylate (B.P.63, Poland) for approximately 2 hours, which made them transparent and they were stored in the solution until the end of the study<sup>23</sup>. The transparent teeth were observed under a stereomicroscope at x16 magnification and evaluated for apical morphology including the presence of accessory canals, apical delta, anastomoses and canal configurations according to the Vertucci's classification<sup>24</sup> and Gulabivala's classification. The apical morphologic indices included the distances between AA and AC, AF and AA, and AF and AC, which were measured with 0.01 mm accuracy. A person, other than the practitioner who did the procedure, performed all the observations and evaluations. The prevalence and incidence rate of each morphologic index were calculated with 95% confidence interval in the Iranian population. Descriptive statistics (including tables, mean, mode, median and dispersion) was applied for data analysis.

## Results


All mandibular premolars belonged to adult patients aged 18 to 65 years. Forty-eight teeth belonged to male and 52 belonged to female patients. The prevalence of canal types according to the Vertucci's classification<sup>24</sup> is described in Table 1.

**Table 1-** Prevalence of canal configurations in the mandibular first and second premolars according to the Vertucci's classification<sup>24</sup> and Gulabivala's classification<sup>25</sup>.

|                                   | Vertucci's type I | Vertucci's type II | Vertucci's type III | Vertucci's type IV | Vertucci's type IV | Gulabivala's type II | Gulabivala's type III | Total     |
|-----------------------------------|-------------------|--------------------|---------------------|--------------------|--------------------|----------------------|-----------------------|-----------|
| Mandibular First Premolar (n=50)  | 36 (72%)          | 3 (6%)             | 3 (6%)              | 1 (2%)             | 7 (14%)            | 0 (0%)               | 0 (0%)                | 50 (100%) |
| Mandibular Second Premolar (n=50) | 41 (82%)          | 2 (4%)             | 2 (4%)              | 0 (0%)             | 2 (4%)             | 2 (4%)               | 1 (2%)                | 50 (100%) |

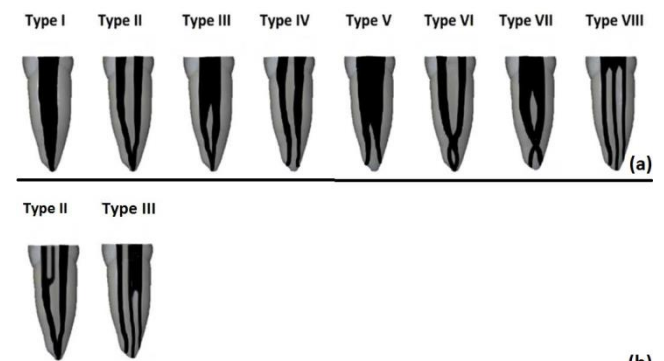
Most mandibular premolars (72% of first and 82% of second premolars) had one canal (Figure 1). In three samples of second premolars, a variation in canal configuration was observed which could not be classified

under the Vertucci's classification. These variations represented type II (Figure 1) and type III (Figure 2) of Gulabivala's classification<sup>25</sup>.



**Figure 1-** Type I (a) and type V (b) according to Vertucci's classification<sup>24</sup> and type II according to Gulabivala's classification<sup>25</sup> (c) under a stereomicroscope at x16 magnification

The prevalence of accessory canals was 40% in both the first and second premolars; inter-canal anastomoses was present in 12% and 10% of the first and second premolars, respectively. Apical deltas were noted in 10.3% and 13.2% of the first and second premolars, respectively (Table 2). The prevalence and direction of deviation of AF from AA are presented in Table 3. The mean distance of AF to AA and AF to AC in the first premolars was  $0.33 \pm 0.2$  and  $0.56 \pm 0.3$  mm, respectively. These values were  $0.35 \pm 0.2$  and  $0.51 \pm 0.2$  mm in the second premolars (Table 4). The AF to AA distance was recorded under a stereomicroscope, by placement of a size 6 or 8 K-file into the canal to the AF and measuring its distance to AA. On the other hand, the AC to AA distance was evaluated after clearing of the teeth, under the stereomicroscope.



**Figure 2-** Schematic view of root canal configurations according to Vertucci's classification (a)<sup>24</sup> and Gulabivala's classification (b)<sup>25</sup>

**Table 2-** Prevalence of anastomoses, accessory canals and apical deltas in mandibular first and second premolars

| Tooth                              | Apical delta    | Accessory canals | Anastomoses   |
|------------------------------------|-----------------|------------------|---------------|
| Mandibular first premolars (n=50)  | 6 teeth (10.3%) | 20 teeth (40%)   | 6 teeth (12%) |
| Mandibular second premolars (n=50) | 7 teeth (13.2%) | 20 teeth (40%)   | 5 teeth (10%) |

**Table 3-** Prevalence and direction of deviation of apical foramen from the anatomic apex in both buccolingual and mesiodistal aspects in mandibular premolars

|  | Deviation    | Mandibular first premolar | Mandibular second premolar |
|--|--------------|---------------------------|----------------------------|
| Apical foramen deviation from the anatomic apex in buccolingual aspect | Mesial       | 25 (43.1%)                | 24 (45.3%)                 |
|  | Distal       | 28 (48.3%)                | 26 (49.1%)                 |
|  | No deviation | 5 (8.6%)                  | 3 (5.7%)                   |
| Apical foramen deviation from the anatomic apex in mesiodistal aspect  | Buccal       | 35 (60.3%)                | 28 (52.8%)                 |
|  | Lingual      | 15 (25.9%)                | 19 (35.8%)                 |
|  | No deviation | 8 (13.8%)                 | 6 (11.3%)                  |

**Table 4-** Distance of apical foramen to anatomic apex, apical foramen to apical constriction and apical constriction to anatomic apex in millimeters

|  | Mandibular first premolars |                                  |       | Mandibular second premolars |                                  |       |
|--|----------------------------|----------------------------------|-------|-----------------------------|----------------------------------|-------|
|  | Mean $\pm$ SD*             | 95% confidence interval for mean |       | Mean $\pm$ SD*              | 95% confidence interval for mean |       |
|  |                            | Lower                            | Upper |                             | Lower                            | Upper |
| Apical foramen to anatomic apex distance       | 0.33 $\pm$ 0.2             | 0.275                            | 0.385 | 0.35 $\pm$ 0.2              | 0.295                            | 0.405 |
| Apical foramen to apical constriction distance | 0.56 $\pm$ 0.3             | 0.477                            | 0.643 | 0.51 $\pm$ 0.2              | 0.455                            | 0.565 |
| Apical constriction to anatomic apex distance  | 0.89 $\pm$ 0.3             | 0.807                            | 0.973 | 0.86 $\pm$ 0.2              | 0.805                            | 0.915 |

## Discussion

A good understanding of canal anatomy is essential for root canal therapy. An untreated root canal, missed by the clinician due to his/her lack of knowledge about the internal morphology of the teeth, could result in treatment failure<sup>26</sup>. Several methods have been suggested for evaluation of root canal anatomy. These include microscopic observations<sup>10</sup> cross-sectioning<sup>10,27</sup>, grinding<sup>11</sup>, modeling<sup>28</sup>, various radiographic techniques<sup>12</sup>, spiral CT<sup>29</sup>, CBCT<sup>13, 14</sup>, micro-CT<sup>15</sup> and also clearing and injection of dye<sup>16-20</sup>. Each method has its own limitations, advantages and disadvantages. Neelakantan<sup>30</sup> et al. (2010) showed that among canal staining and clearing, CBCT, peripheral quantitative CT, Spiral CT and plain digital radiography, CBCT and peripheral quantitative CT are as accurate as the staining and clearing technique in identifying root canal anatomy<sup>30</sup>. The canal staining and tooth clearing is typically considered as the gold standard to study the apical and root canal morphology<sup>25</sup>. Therefore, clearing and decalcifying techniques provide the most accurate and comprehensive data. This technique produces a 3D image of root canal space. It also helps maintaining the original root canal morphology and its anastomoses<sup>23</sup>. Tooth samples can be stored for a long time, little equipment and space is needed and the toxicity of the chemicals used is low<sup>16</sup>. One of the limitations of the staining and clearing method is its invasive nature, while CBCT and micro-CT provide almost the same level of accuracy for detection of canal morphology in conjunction with their non-invasive nature which can be used directly to evaluate patients<sup>31</sup>. In this study, the clearing and staining technique was employed due to its accuracy and other advantages.

All the first premolars in this study were single-rooted. This result was in accord with earlier studies<sup>14, 16, 20, 32</sup>. A study by Kazemipour et al. (2015)<sup>33</sup> reported that 86.4% of mandibular first premolars in Yazd, Iran were single-rooted. The prevalence of non-single rooted first premolars in the study by Kazemipour et al.<sup>33</sup> was higher than that in other studies on the Iranian population. Moreover, Chourasia et al. (2017)<sup>19</sup> reported a lower prevalence of single-rooted

mandibular first premolars (80%) in a Saudi subpopulation. These differences may be due to regional background of the tooth sources, as well as the differences in the methods used. All the second premolars were also single-rooted. Almost all of the teeth in the earlier anatomic studies were single-rooted. The incidence of two roots and three roots was extremely low.<sup>14, 16, 34</sup>

In the present study, the prevalence of different types of canal configurations in first premolars was as follows: 72% type I, 6% type II, 6% type III, 2% type IV and 14% type V according to the Vertucci's classification; which was similar to the results of previous researches<sup>12, 16-18, 24</sup>. Among the Iranian population, Khedmat et al. (2010)<sup>27</sup> reported that 88.4% in Golestan subpopulation, Kazemipour et al. (2015)<sup>33</sup> revealed that 68.1% in Yazd, Kuzekanani and Asgari (2005)<sup>35</sup> reported that 79% in Kerman, Rahimi et al. (2007)<sup>36</sup> showed that 70.6% in Tabriz and Sobhani et al. (2013)<sup>37</sup> reported that 90.8% in Tehran population were type I according to the Vertucci's classification, all in accordance with our study. The highest prevalence of type I was reported by Ok<sup>38</sup> in a Chinese population (92.8%) and Bulut et al. (2015)<sup>14</sup> in a Turkish population (94%). In contrast, the lowest prevalence of type I was reported by Alhadini (2013)<sup>20</sup> as 61% in an Egyptian population. These divergent reported results may best be explained by methodological differences or by variations in sample size and ethnic background of the samples used.

The prevalence of different types of canal configurations in second premolars were 82% type I, 4% type II, 4% type III and 4% type V according to Vertucci's classification. Rahimi et al. (2009) obtained almost the same results in an Iranian subpopulation<sup>39</sup>. Similar results (76.3-91.2% of type I) were reported by several studies on Iranian population<sup>11, 37</sup>. Again, the highest prevalence of type I was reported by Ok (98.5%)<sup>38</sup> and Bulut et al. (2015) (98%)<sup>14</sup>.

This study showed that the prevalence of anastomosis was 12% and 10% in the first and second premolars, respectively; the prevalence of accessory canals was 40% for both types of teeth. This result was similar to the results of previous studies<sup>12, 17, 18, 24, 39</sup>.

Apical delta was present in 10.3% of the first and 13.2% of

the second premolars. Some authors reported lower prevalence rates<sup>12, 19, 24, 39</sup>, while others reported higher rates<sup>17, 18, 20</sup>. These discrepancies in percentages are related to ethnic origins (the prime reason of the variations in the root canal configuration), sample size, the method of investigation and also the evaluators.

The results of this study revealed that the AF deviation towards the buccal and mesial (31%) and buccal and distal (24.5%) were the most prevalent directions of deviation in the first and second premolars, respectively. This was in accordance with other studies<sup>12, 24, 40, 41</sup>. AF does not normally exit at the AA, but is rather located mesially, distally, buccally or lingually relative to the apex. This variation is more prominent in older individuals due to cementum apposition during continuous remodeling of teeth as the result of physiological or pathological conditions<sup>2</sup>. The deviation of the apical foramen is not easily detectable on radiographs, especially when its opening is on the buccal or lingual wall of the root<sup>40</sup>. This issue could result in incorrect working length determination.

In the current study, it was observed that the mean distance between AF and AA in the first and second mandibular premolars was 0.3 mm. These results are approximately consistent with those found by other researchers<sup>1, 10, 11, 40</sup>. The mean distance between AF and AC was 0.6 mm for the first premolars and 0.5 mm for the second premolars. Safi et al.<sup>11</sup> reported lower rates in the population of Shiraz, Iran. Additionally, the mean distance between AC to AA was 0.9 and 0.8 mm in the first and second premolars, respectively. It was also similar to the results of previous studies<sup>1, 10, 11</sup>. It is assumed that the variability in the reported rates is due to different methodologies and target populations of the studies<sup>6, 7</sup>. Most studies use the cross-sectioning method<sup>1, 10, 40</sup>, whereas in the present study we used the clearing method.

In the method used in the present study, an innovative step was added to the Robertson's method<sup>23</sup>. In order to prevent microleakage of nitric acid and methyl salicylate into the

canal space, we applied two layers of nail varnish on the margins of the temporary restoration. Additionally, although the standard time for decalcification is said to be 3 days<sup>23</sup>, it is worth noting that in the present study, some teeth took 5 to 6 days in order to be completely decalcified. Thus, ensuring adequate decalcification of the samples is highly important. This was assessed by inspecting and tactile sensation, which was carried out by an explorer and subsequently by radiographic comparison with an intact tooth.

One of the limitations of this study was inadequate information about the age of patients, whose teeth were extracted and examined. Further studies based on age and sex of patients whose teeth are evaluated are required.

## Conclusion

Within the limitations of the current study, it was observed that mandibular first premolars present more anatomical challenges than mandibular second premolars, due to extreme variations in their root canal morphology. Even though most of the mandibular premolars have a single Vertucci's type I canal (especially mandibular second premolars), using appropriate cleaning and irrigating methods are necessary, because there is a high prevalence of accessory canals, anastomoses and apical deltas in both the first and second premolars of the mandible

## Conflict of Interest

The authors declare that they have no conflict of interest. This article was based on an under-graduate thesis by an undergraduate student, which was successfully completed under the supervision of Dr. Mandana Naseri at the Dental School of Shahid Beheshti University of Medical Sciences.

## References

- Dummer P, McGinn J, Rees D. The position and topography of the apical canal constriction and apical foramen. *Int Endod J*. 1984 Oct;17(4):192-8.
- Asna-ashari M, Nouri M, Mozayyeni MA, Seradji F. Evaluation of apical foramen situation by anatomic apex and diagnostic value of radiography on determination of its location (A stereomicroscopic study). *J Dent Sch*. 2004 Fall;22(3):361-8.
- Ricucci D, Langeland K. Apical limit of root canal instrumentation and obturation, part 2. A histological study. *Int Endod J*. 1998 Nov;31(6):394-409.
- Mangani F, Ruddle CJ. Endodontic treatment of a "very particular" maxillary central incisor. *J Endod*. 1994 Nov;20(11):560-1.
- Ingle JI, Bakland L. *Endodontics*. 5th ed. BC Decker: Hamilton; 2002.p 194.
- Trope M, Elfenbein L, Tronstad L. Mandibular premolars with more than one root canal in different race groups. *J Endod*. 1986 Aug;12(8):343-5.
- Kim E, Fallahrestegar A, Hur YY, Jung IY, Kim S, Lee SJ. Difference in root canal length between Asians and Caucasians. *Int Endod J*. 2005 Mar;38(3):149-51.
- Zillich R, Dowson J. Root canal morphology of mandibular first and second premolars. *Oral Surg Oral Med Oral Pathol*. 1973 Nov;36(5):738-44.
- de Pablo O. V, Estevez R, Peix Sanchez M, Heilborn C, Cohenca N. Root anatomy and canal configuration of the permanent mandibular first molar: a systematic review. *J Endod*. 2010 Dec;36(12):1919-31.
- Kuttler Y. Microscopic investigation of root apices. *J Am Dent Assoc*. 1955 May;50(5):544-52.
- Safi L, Pardis S, Khalili F. An in vitro evaluation of root anatomy, detection of apical foramen and apical constriction in human mandibular premolar teeth. *Shiraz Univ Dent J*. 2006;6(1):47-56.
- Pineda F, Kuttler Y. Mesiodistal and buccolingual roentgenographic investigation of 7,275 root canals. *Oral Surg Oral Med Oral*

- Pathol. 1972 Jan;33(1):101-10.
13. Naseri M, Safi Y, Akbarzadeh Baghban A, Khayat A, Eftekhari L. Survey of anatomy and root canal morphology of maxillary first molars regarding age and gender in an Iranian population using cone-beam computed tomography. *Iran Endod J*. 2016 Fall;11(4):298-303.
  14. Bulut D. G, Kose E, Ozcan G, Sekerci A. E, Canger EM, Sisman Y. Evaluation of root morphology and root canal configuration of premolars in the Turkish individuals using cone beam computed tomography. *Eur J Dent*. 2015 Oct-Dec;9(4):551-7.
  15. Grande NM, Plotino G, Gambarini G, Testarelli L, D'Ambrosio F, Pecci R, et al. Present and future in the use of micro-CT scanner 3D analysis for the study of dental and root canal morphology. *Ann Ist Super Sanita*. 2012;48(1):26-34.
  16. Singh S, Pawar M. Root canal morphology of South Asian Indian mandibular premolar teeth. *J Endod*. 2014 Sep;40(9):1338-41.
  17. Caliskan M. K, Pehlivan Y, Sepetcioglu F, Turkun M, Tuncer SS. Root canal morphology of human permanent teeth in a Turkish population. *J Endod*. 1995 Apr; 21(4):200-4.
  18. Sert S, Bayirli GS. Evaluation of the root canal configurations of the mandibular and maxillary permanent teeth by gender in the Turkish population. *J Endod*. 2004 Jun ;30(6):391-8.
  19. Chourasia H, Boreak N, Tarrosh M, Mashyakhly M. Root canal morphology of mandibular first premolars in Saudi Arabian southern region subpopulation. *Saudi Endod J*. 2017 Apr;7(2):77-81.
  20. Alhadainy HA. Canal configuration of mandibular first premolars in an Egyptian population. *J Adv Res*. 2013 Mar ;4(2):123-8.
  21. Alves AM, Felipe MC, Felipe WT, Rocha MJ. Ex vivo evaluation of the capacity of the Tri Auto ZX to locate the apical foramen during root canal retreatment. *Int Endod J*. 2005 Oct;38(10):718-24.
  22. Hsu YY, Kim S. The resected root surface. The issue of canal isthmuses. *Dent Clin North Am*. 1997 Jul;41(3):529-40.
  23. Robertson D, Leeb I. J, McKee M, Brewer E. A clearing technique for the study of root canal systems. *J Endod*. 1980 Jan;6(1):421-4.
  24. Vertucci FJ. Root canal anatomy of the human permanent teeth. *Oral Surg Oral Med Oral Pathol*. 1984 Nov;58(5):589-99.
  25. Gulabivala K, Aung TH, Alavi A, Ng YL. Root and canal morphology of Burmese mandibular molars. *Int Endod J*. 2001 Jul;34(5):359-70.
  26. Vertucci FJ. Root canal morphology and its relationship to endodontic procedures. *Endod Topics*. 2005 Mar;10(1):3-29.
  27. Khedmat S, Assadian H, Saravani AA. Root canal morphology of the mandibular first premolars in an Iranian population using cross-sections and radiography. *J Endod*. 2010 Feb;36(2):214-7.
  28. Gomes BP, Rodrigues HH, Tancredo N. The use of a modelling technique to investigate the root canal morphology of mandibular incisors. *Int Endod J*. 1996 Jan;29(1):29-36.
  29. Gopikrishna V, Bhargavi N, Kandaswamy D. Endodontic management of a maxillary first molar with a single root and a single canal diagnosed with the aid of spiral CT: a case report. *J Endod*. 2006 Jul;32(7):687-91.
  30. Neelakantan P, Subbarao C, Subbarao CV. Comparative evaluation of modified canal staining and clearing technique, cone-beam computed tomography, peripheral quantitative computed tomography, spiral computed tomography, and plain and contrast medium-enhanced digital radiography in studying root canal morphology. *J Endod*. 2010 Sep;36(9):1547-51.
  31. Yang H, Tian C, Li G, Yang L, Han X, Wang Y. A cone-beam computed tomography study of the root canal morphology of mandibular first premolars and the location of root canal orifices and apical foramina in a Chinese subpopulation. *J Endod*. 2013 Apr;39(4):435-8.
  32. Cleghorn B. M, Christie W. H, Dong C. C. The root and root canal morphology of the human mandibular first premolar: a literature review. *J Endod*. 2007 May;33(5):509-16.
  33. Kazemipour M, Pookheradmand M, Rezaeian M, Safi Y. Evaluation by CBCT of root and canal morphology in mandibular premolars in an Iranian population. *Chin J Dent Res*. 2015;18(3):191-6.
  34. Cleghorn B. M, Christie WH, Dong C. C. The root and root canal morphology of the human mandibular second premolar: a literature review. *J Endod*. 2007;33(9):1031-7.
  35. Kuzekanani M, Asgari E. The incidence of mandibular first premolar teeth with 2 canals in a group of Kerman population. *J Dent Sch (Shahid Beheshti)*. 2005;23(2):286-93.
  36. Rahimi S, Shahi S, Yavari H. R, Manafi H, Eskandarzadeh N. Root canal configuration of mandibular first and second premolars in an Iranian population. *J Dent Res Dent Clin Dent Prospects*. 2007 Summer;1(2):59-64.
  37. Sobhani MA, Razmi H, Sadeh M. Evaluation of anatomy and morphology of human mandibular premolar teeth by cone-beam computed tomography in Iranian population. *J Dent Med*. 2013 Sep;26(3).
  38. Ok E, Altunsoy M, Nur B. G, Aglarci O. S, Colak M, Gungor E. A cone-beam computed tomography study of root canal morphology of maxillary and mandibular premolars in a Turkish population. *Acta Odontol. Scand*. 2014 May ;72(8):701-6.
  39. Rahimi S, Shahi S, Yavari HR, Reyhani MF, Ebrahimi ME, Rajabi E. et al. A stereomicroscopy study of root apices of human maxillary central incisors and mandibular second premolars in an Iranian population. *J Oral Sci*. 2009 Apr;51(3):411-5.
  40. Burch JG, Hulen S. The relationship of the apical foramen to the anatomic apex of the tooth root. *Oral Surg Oral Med Oral Pathol*. 1972 Aug;34(2):262-8.
  41. Gutierrez JH, Aguayo P. Apical foraminal openings in human teeth. *Oral Surg Oral Med Oral Pathol Oral Radiol Endod*. 1995 Jun;79(6):769-77.

**How to cite:**

Mandana Naseri, Mohammad Ali Mozayeni, Nahid Adelkhani, Atefeh Gohari. Evaluation of Root Canal Morphology and Root Apex Anatomy of Mandibular Premolars in an Iranian Population: an ex-vivo study. *J Dent Sch* 2019;37(1):11-16.