

Intra-osseous Jaw Lesions in Children and Adolescents: A 20-Year Retrospective Study in an Iranian Population

Nasim Taghavi^a, Fahimeh Kooshki^b, Nafiseh Shamloo^c, Mohammadreza Hosseini^d

^aAssociate Prof., Dept. of Oral & Maxillofacial Pathology, School of Dentistry, Shahid Beheshti University of Medical Sciences, Tehran, Iran.

^bAssistant Prof., Dept. of Pediatric Dentistry, School of Dentistry, Shahid Beheshti University of Medical Sciences, Tehran, Iran.

^cAssistant Prof., Dept. of Oral & Maxillofacial Pathology, School of Dentistry, Shahid Beheshti University of Medical Sciences, Tehran, Iran.

^dPostgraduate student, Dept. of Endodontics, School of Dentistry, Shahid Beheshti University of Medical Sciences, Tehran, Iran.

Correspondence to Mohammadreza Hosseini (email: Mohammadrezahosseini_005@yahoo.com).

(Submitted: 1 May 2019 – Revised version received: 21 May 2019 – Accepted: 2 June 2019 – Published online: Winter 2019)

Objectives The aim of the present study was to document the frequency and clinicopathologic features of intra-osseous jaw lesions in an Iranian pediatric population over a 20-year period.

Methods Data were obtained from the archives of the Oral Pathology Department, Shahid Beheshti University of Medical Sciences, Tehran, Iran. The lesions were classified into four groups: (A) odontogenic cysts, (B) odontogenic tumors, (C) benign bone pathologies and (D) malignant bone tumors. The patients were divided into two age groups of (A) children (≤ 12 years old) and (B) adolescents (13 to 18 years old).

Results Of 5,722 biopsy samples, 475 (58.2%) were diagnosed as intra-osseous lesions in patients aged 0-18 years with a male (55.2%) and mandibular (60.6%) predilection. The patients' age ranged from 3 months to 18 years with a mean age of 12.5 years. Odontogenic cysts presented the most prevalent subgroup (51.3%) followed by benign bone pathologies (26.5%), odontogenic tumors (18.9%) and malignant bone tumors (3.1%). The most frequently observed lesions in descending order were dentigerous cyst (25.2%), radicular cyst (18.3%), central giant cell granuloma (14.9%), ameloblastoma (7.7%) and odontogenic keratocyst (5%).

Conclusion Comparing our results with available data showed similarities in odontogenic cysts and benign bone pathologies. However, differences in odontogenic and malignant bone tumors were evident, which may be due to racial and geographical characteristics. Considering the limited data, further studies are recommended in this respect.

Keywords Jaw; Child; Adolescent; Iran

Introduction

Oral and maxillofacial lesions affecting children and adolescents differ from those affecting the adult population, which may be due to the ongoing process of physical growth and development in children. These lesions constitute approximately 7-17% of all submitted biopsies in specialized pathology centers.¹ Malignant tumors are rare and comprise about 1% of the pediatric pathology samples.² There are several histopathologic and epidemiologic investigations from the USA, South America, Europe, Africa and Asia evaluating the pediatric population with variable results.^{1, 3-9} Numerous studies focused on specific types of lesions mostly tumors and tumor-like lesions^{3, 10, 11}, but comprehensive surveys on the incidence and clinicopathologic characteristics of intra-osseous jaw lesions are infrequent.^{12, 13}

Intrabony lesions might lead to expansion, root resorption, tooth displacement, cortical perforation or destruction of the adjacent tissue.^{14, 15} Therefore, knowledge about their prevalence, age, sex distribution, histological subtypes and anatomical location is imperative for early diagnosis and effective treatment. Considering the limited data in the literature in this respect from Iran, this retrospective study reviewed the relative frequency, demographics, histological diagnosis and anatomical distribution of intra-osseous jaw

lesions in a population of Iranian children and adolescents over a 20-year period.

Materials and Methods

This study was approved by the Ethics Committee of Shahid Beheshti University of Medical Sciences (IR.SBMU.RIDES.REC.1395-430). A retrospective assessment was conducted on the archive of the Oral Pathology Department of Shahid Beheshti Dental School (Tehran, Iran) between 1998 and 2017, and all intra-osseous jaw lesions in patients 18 years of age or younger were retrieved. The lesions were classified into four groups: (A) odontogenic cysts, (B) odontogenic tumors, (C) benign bone pathologies and (D) malignant bone tumors. The patients were divided into two age groups of (A) children (≤ 12 years old) and (B) adolescents (13 to 18 years old). The patients' age and gender, location and frequency of lesions, and their clinical and histopathological features were the main outcome measures. The cases without complete data and definite histopathological diagnosis were excluded from the study. Data were analyzed using SPSS software version 22 (SPSS Inc., Chicago, IL) via the chi-square test. $P < 0.05$ was considered statistically significant.

Results

In the 20-year period investigated, 5,722 biopsy samples of jaw lesions with definite diagnosis were detected; from which, 832 (14.54%) affected patients ≤ 18 years of age. Of 832 cases, 475 (58.2%) were intra osseous jaw lesions. From these, 174 (36.6%) cases were diagnosed in children and 301 (63.3%) cases in adolescents. The peak frequency was observed in the year 2002 (8.4%) followed by 2011 (7.2%) and 2009 (6.8%). The least frequency was found in 2017 (1.5%). The most frequent subgroup was odontogenic cysts (51.3%) followed by benign bone pathologies (26.5%), odontogenic tumors (18.9%) and malignant bone

tumors (3.1%). The five most frequently occurring lesions comprised 71.1% of the total biopsies and included dentigerous cyst (DC; 25.2%), radicular cyst (RC; 18.3%), central giant cell granuloma (CGCG; 14.9%), ameloblastoma (7.7%) and odontogenic keratocyst (OKC; 5%). The patients' age ranged from 3 months to 18 years, with a mean age of 12.5 years. In terms of gender, 262 (55.2%) males and 213 (44.8%) females (male/female ratio: 1.2:1) were found. Regarding location, 288 (60.6%) cases were in the mandible and 187 (39.3%) cases were in the maxilla indicating on overall mandible-maxilla ratio of 1.5. Location distribution of the eight most frequent lesions is shown in Figure 1.

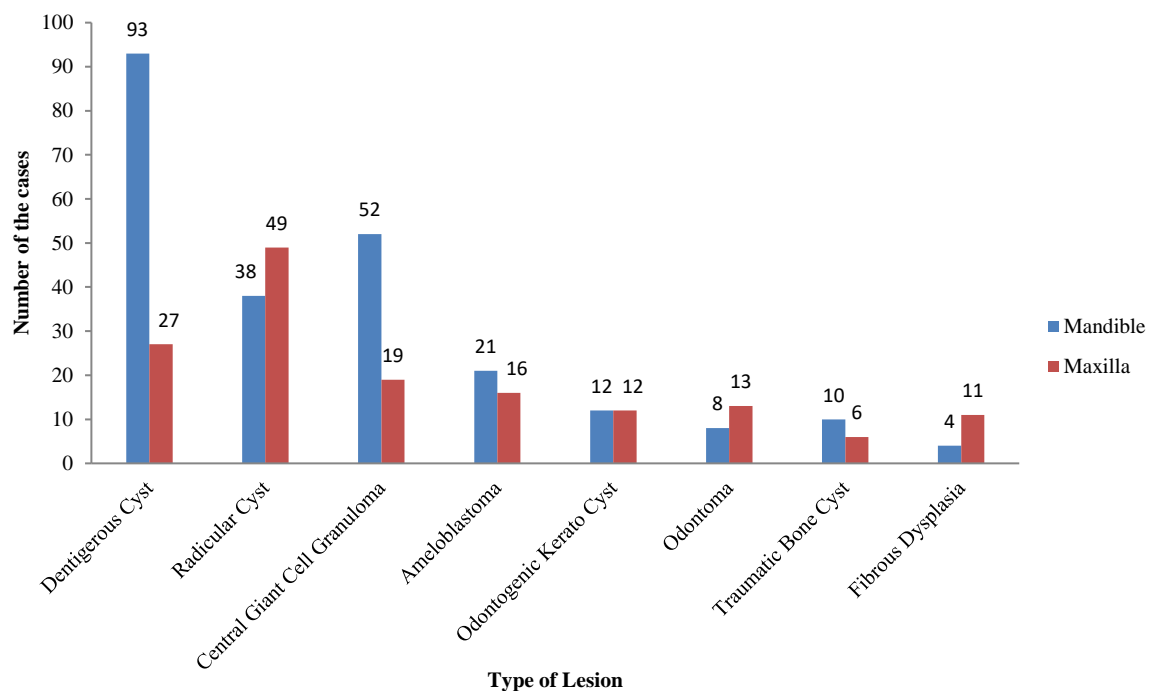


Figure 1- Location distribution of eight most frequent intra-osseous jaw lesions

Chi-square test showed no significant difference in gender, age or location among the four groups ($P > 0.05$).

In the present study, 244 cases of odontogenic cysts were observed (Table 1). The predominant types noticed were DC (49.1%) (Fig.2a), RC (35.6%) and OKC (9.8%). Male ($n=150$) to female ($n=94$) ratio was 1.59:1. However, all cases of calcifying odontogenic cyst (COC; $n=3$) were seen in females. The patients' age ranged from 4 to 18 years with a mean age of 14.1 years. The majority of the cysts ($n=143$) were found in adolescents with mandible ($n=136$) being the favored site. Of note, RC and COC showed a higher frequency in the maxilla. Equal distribution in the maxilla and mandible was found for OKC. Evaluation of clinical features represented painless swelling as the most significant sign in 189 (77.4%) cases. Pain was detected in 18 cases of RC and 3 cases of buccal bifurcation cyst.

Table 2 shows the distribution of odontogenic tumors with ameloblastoma ($n=37$; Fig. 2b) being the predominant tumor followed by odontoma ($n=21$), myxomas ($n=10$) and adenomatoid odontogenic tumor (AOT; $n=6$). The mean age of occurrence was 16 years with a higher predilection in males [the samples comprised of 50 (55%) males and 40 (45%) females]. The female preponderance was more noticeable for AOT. Data concerning the anatomical distribution demonstrated predominance for the mandible (55%). However, odontoma and odontogenic fibroma showed higher frequency in the maxilla. Similar to odontogenic cysts, painless expansion was the most remarkable clinical feature ($n=126$). Cortical perforation and paresthesia were reported in 5 and 3 cases with ameloblastoma, respectively.

Table 1- Distribution of odontogenic cysts				
Odontogenic cysts	No. (%)	Male/ female ratio	Children No. (%)	Adolescents No. (%)
Dentigerous cyst	120 (49.1)	2:1	53 (21.7)	67 (27.4)
Radicular cyst	87 (35.6)	1.2:1	32 (13.1)	55 (22.5)
Odontogenic keratocyst	24 (9.8)	1.6:1	10 (4.09)	14 (5.7)
Residual cyst	3 (1.2)	2:1	1 (0.4)	2 (0.8)
Calcifying odontogenic cyst	3 (1.2)	0.3:1	0 (0)	3 (1.2)
Buccal bifurcation cyst	7 (2.8)	1.3:1	5 (2.1)	2 (0.8)
Total	244 (100)	1.59:1	101 (41.4)	143 (58.6)

Table 2- Distribution of odontogenic tumors				
Odontogenic tumors	No. (%)	Male/female ratio	Children No. (%)	Adolescents No. (%)
Ameloblastoma	37 (41.1)	1.3:1	15(16.6)	22(24.4)
Odontoma	21 (23.3)	2:1	6(6.6)	15(16.6)
Myxoma	10 (11.1)	1	2(2.2)	8(8.8)
AOT [⊛]	6 (6.6)	0.2:1	0(0)	6(6.6)
Odontogenic fibroma	6 (6.6)	1	1(1.1)	5(5.5)
AFO [⊛]	4 (4.4)	3:1	2(2.2)	2(2.2)
Cementoblastoma	4 (4.4)	1	1(1.1)	3(3.3)
Ameloblastic fibroma	2 (2.2)	1	1(1.1)	1(1.1)
Total	90 (100)	1.25:1	28(31.1)	62(68.8)

⊛ AOT (Adenomatoid odontogenic tumor), AFO (Ameloblastic-fibro odontoma)

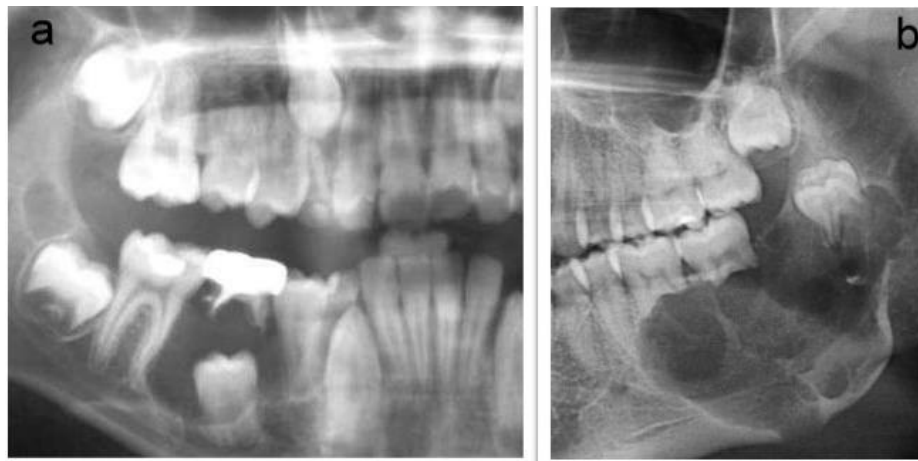


Figure 2- (a) Dentigerous cyst in the posterior mandible (b) ameloblastoma in the posterior mandible

Among 126 cases of benign bone pathologies (Table 3), 71 cases were CGCG (Fig. 3a) followed by traumatic bone cyst (TBC; n=16), fibrous dysplasia (FD; n=15) and aneurysmal bone cyst (ABC; n=14). The patients' age ranged from 5 to 18 years with a mean age of 12.3 years. The majority of the cases were adolescents (n=82). Higher

number of female patients (male to female ratio of 0.9:1) and mandibular predilection (n=83, 68.5%) were significant. Notably, maxillary involvement in FD (n=11) was higher. Most cases (n=86) of the present subgroup, in particular CGCG, cemento-osseous dysplasia and TBC, were asymptomatic. Pain was reported in 4 cases of ABC.

Table 3- Distribution of benign bone pathologies				
Bone pathologies	No. (%)	Male/ female ratio	Children No. (%)	Adolescents No. (%)
CGCG [⊛]	71 (56.3)	0.7:1	26(20.6)	45(35.7)
Traumatic bone cyst	16 (12.6)	1.2:1	2(1.58)	14(11.1)
Fibrous dysplasia	15 (11.9)	0.8:1	7(5.5)	8(6.3)
Aneurysmal bone cyst	14 (11.1)	1.3:1	6(4.7)	8(6.3)
COD [⊛]	5 (3.9)	1.5:1	1(0.79)	4(3.1)
Central ossifying fibroma	5 (3.9)	1.5:1	2(1.58)	3(2.3)
Total	126 (100)	0.9:1	44(34.9)	82(65.1)

⊛CGCG (Central giant cell granuloma), COD (cemento-osseous dysplasia)

Details of malignant bone tumors are presented in Table 4. These tumors (n=15, 3.1%) were approximately rare.

Osteosarcoma (n=6; Fig. 3b) was the most frequent tumor followed by Langerhans cell histiocytosis (n=5),

chondrosarcoma (n=2) and Ewing sarcoma (n=2). The patients' age ranged from 10 to 17 years with a mean age of 14.3 years. An almost equal distribution between males (n=7) and females (n=8) and mandibular (n=7) and

maxillary (n=8) involvement was observed. Rapidly growing swelling associated pain was found in all cases. In addition, cortical perforation was reported in 2 cases with osteosarcoma.

Table 4- Distribution of malignant bone tumors

Malignant bone tumors	No. (%)	Male/ female ratio	Children No. (%)	Adolescents No. (%)
Osteosarcoma	6 (40)	1	1 (6.6)	5 (33.3)
Chondrosarcoma	2 (13.3)	2:1	0 (0)	2 (13.3)
Ewing sarcoma	2 (13.3)	1	0 (0)	2 (13.3)
Langerhans cell histiocytosis	5 (33.3)	1.5:1	2 (13.3)	3 (20)
Total	15 (100)	0.87:1	3 (20)	12 (80)

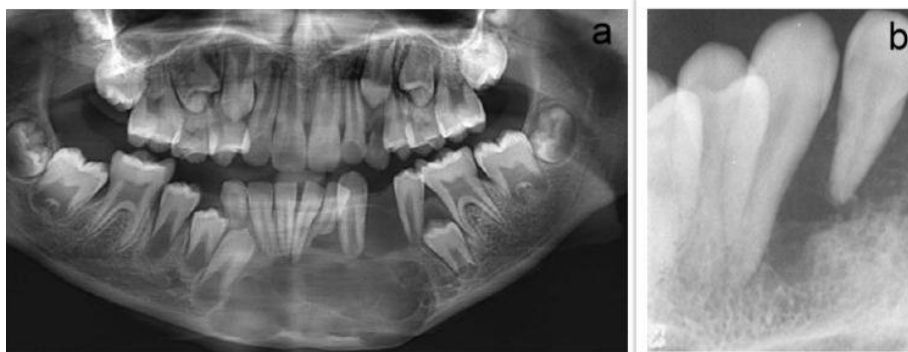

Figure 3- (a) Central giant cell granuloma in the anterior mandible (b) osteolytic osteosarcoma in the anterior maxilla

Discussion

This study provided the profile of intra-osseous jaw pathologies encountered in an Iranian pediatric population. The percentage of pediatric specimens in our study (14.54%) was more than that in studies conducted in Brazil⁸, Turkey¹⁶, Thailand⁵ and less than that in a study conducted in Nigeria.⁶ Intra osseous jaw lesions comprised 58.2% of the total biopsies in pediatric patients, a percentage within the range of variation found in Brazil, India and South east of Iran.^{1, 12, 17} Different results between studies can be related to geographical location, upper age limit, period of study and medical center type. In line with previous studies, our results showed a predominance of odontogenic cysts (51.3%) in pediatric age group of 0-18 years. Additionally, our data showed a male and mandibular predominance which was similar to the results of Urs et al, and Skiavounou et al.^{12, 13} Conversely, maxillary predominance was reported by Ochsenius et al.¹⁸ The most prevalent lesion in the present study was DC (25.2%), followed by RC (18.3%) which was in accordance with former published data.^{4-6, 12, 13} Opposing results were found in Greece and Chile; wherein, radicular cyst had the highest frequency.^{13, 18} Benign bone pathologies constituted 26.5% of the cases, which represented the second most frequent subgroup in our series that disagreed with the results of Urs et al.¹² However, in accordance with their results and data from Brazilian and Indian populations, CGCG was the most

prevalent lesion in this subgroup with female and mandibular predilection.^{1,12,19} In a Thai pediatric population, fibrous dysplasia comprised the highest number of benign bone pathologies.⁵ Maxillary and female predilection was observed in fibrous dysplasia in our series and previously published data.^{1, 5} In odontogenic tumors, ameloblastoma was the commonly found tumor followed by odontoma, which was similar to studies by Saxena et al.¹⁹ Aregbesola et al.⁶ and Dhanuthai et al.⁴ However, in Brazilian, Greece and Australian pediatric populations, odontoma was reported as the most prevalent pediatric odontogenic tumor followed by ameloblastoma.^{1, 2, 10, 13, 14} We found male and mandibular predominance in odontogenic tumors, which agreed with obtained results in Asian and African countries^{3, 11, 16} but Servato et al. showed equal gender distribution with slightly higher maxillary involvement.¹⁴

In general, malignant tumors in pediatric patients comprise less than 1% of all biopsies. Rhabdomyosarcoma is the most common soft tissue tumor.¹ In the present series, 15 (3.1%) cases of malignant bone tumors were observed; among which, the commonest tumor was osteosarcoma. Our results indicated a higher percentage of malignant tumors compared with previous reports.^{3, 10-12, 19, 20} All malignant tumors presented with rapidly growing swelling associated pain implying the necessity of special attention to children with the afore mentioned clinical features for early diagnosis and proper treatment.

Conclusion

In conclusion, this is the first large series of intra-osseous jaw lesions in pediatric patients from Iran. Comparing this study with other populations reveals similarities in odontogenic cysts and benign bone pathologies. However, differences in the frequency and type of odontogenic tumors and malignant tumors were also found. Considering

the small number of studies related to intra-osseous jaw lesions especially malignant bone tumors in pediatric patients, further studies are necessary to compare the obtained data and allow better understanding and faster diagnosis of these lesions.

Conflict of Interest

Non Declared ■

References

1. Prosdócimo ML, Agostini M, Romañach MJ, de Andrade BA. A retrospective analysis of oral and maxillofacial pathology in a pediatric population from Rio de Janeiro–Brazil over a 75-year period. *Med Oral Patol Oral Cir Bucal*. 2018 Sep;23(5):e511-17.
2. Ha W, Kelloway E, Dost F, Farah CS. A retrospective analysis of oral and maxillofacial pathology in an Australian paediatric population. *Aust Dent J*. 2014 Jun;59(2):221-5.
3. Jaafari-Ashkavandi Z, Ashraf MJ. A clinico-pathologic study of 142 orofacial tumors in children and adolescents in southern Iran. *Iran J Pediatr*. 2011 Sep;21(3):367-72.
4. Dhanuthai K, Banrai M, Limpanaputtajak S. A retrospective study of paediatric oral lesions from Thailand. *Int J Paediatr Dent*. 2007 Jul;17(4):248-53.
5. Laphanasupkul P, Juengsomjit R, Klanrit P, Taweechaisupapong S, Poomsawat S. Oral and maxillofacial lesions in a Thai pediatric population: a retrospective review from two dental schools. *J Med Assoc Thai*. 2015 Mar;98(3):291-7.
6. Aregbesola SB, Ugboko VI, Akinwande JA, Arole GF, Fagade OO. Orofacial tumours in suburban Nigerian children and adolescents. *Br J Oral Maxillofac Surg*. 2005 Jun;43(3):226-31.
7. Furlanetto DLV, Crighton A, Topping GVA. Differences in methodologies of measuring the prevalence of oral mucosal lesions in children and adolescents. *Int J Paediatr Dent*. 2006 Jan;16(1):31-9.
8. Ataíde AP, Fonseca FP, Silva ARS, Júnior JJ, Lopes MA, Vargas PA. Distribution of oral and maxillofacial lesions in pediatric patients from a Brazilian southeastern population. *Int J Pediatr Otorhinolaryngol*. 2016 Nov;90:241-4.
9. Kwok EY, Dovigi EA, Eversole LR, Dovigi AJ. Pediatric oral pathology: a retrospective survey of 4,554 biopsies. *Pediatr Dent*. 2015 Dec;37(7):546-9.
10. Iatrou I, Theologie-Lygidakis N, Tzerbos F, Schoinohoriti OK. Oro-facial tumours and tumour-like lesions in Greek children and adolescents: an 11-year retrospective study. *J Craniomaxillofac Surg*. 2013 Jul;41(5):437-43.
11. Adebayo ET, Ajike SO, Adekeye EO. Tumours and tumour-like lesions of the oral and perioral structures of Nigerian children. *Int J Oral Maxillofac Surg*. 2001 Jun;30(3):205-8.
12. Urs AB, Arora S, Singh H. Intra-osseous jaw lesions in paediatric patients: a retrospective study. *J Clin Diagn Res*. 2014 Mar;8(3):216-20.
13. Skiavounou Dr, Odont A, Iakovou M, Kontos-Toutouzas J, Kanellopoulou A, Papanikolaou Dr. Intra-osseous lesions in Greek children and adolescents. A study based on biopsy material over a 26-year period. *J Clin Pediatr Dent*. 2006 Jan;30(2):153-6.
14. Servato J, De Souza P, Horta M, Ribeiro D, de Aguiar M, De Faria P, et al. Odontogenic tumours in children and adolescents: a collaborative study of 431 cases. *Int J Oral Maxillofac Surg*. 2012 Jun;41(6):768-73.
15. Iatrou I, Theologie-Lygidakis N, Leventis M. Intraosseous cystic lesions of the jaws in children: a retrospective analysis of 47 consecutive cases. *Oral Surg Oral Med Oral Pathol Oral Radiol Endod*. 2009 Apr;107(4):485-92.
16. Gultelkin SE, Tokman B, Turkseven MR. A review of paediatric oral biopsies in Turkey. *Int Dent J*. 2003 Feb;53(1):26-32.
17. Saravani S, Kadeh H, Amirabadi F, Keramati N. Clinical and histopathological profiles of pediatric and adolescent oral and maxillofacial biopsies in a Persian population. *Int J Pediatr*. 2015 Jan;3(1.1):381-90.
18. Ochsenius G, Escobar E, Godoy L, Peñafiel C. Odontogenic cysts: analysis of 2,944 cases in Chile. *Med Oral Patol Oral Cir Bucal*. 2007 Mar;12(2):85-91.
19. Saxena S, Kumar S, Pundir S. Pediatric jaw tumors: Our experience. *J Oral Maxillofac Pathol*. 2012 Jan;16(1):27-30.
20. Trobs RB, Mader E, Friedrich T, Bennek J. Oral tumors and tumor-like lesions in infants and children. *Pediatr Surg Int*. 2003 Nov;19(9-10):639-45.

How to cite:

Nasim Taghavi, Fahimeh Kooshki, Nafiseh Shamloo, Mohammadreza Hosseini. Intra-osseous Jaw Lesions in Children and Adolescents: A 20-Year Retrospective Study in an Iranian Population. *J Dent Sch* 2019;37(1):21-25.