

Cementoblastoma of the Mandible: A Case Report and Review of Literature

Safoura Seifi^a, Marjan Kiani^b, Alireza Babaei Darzi^c, Hakimeh Ghorbani^d

^aDept. of Oral & Maxillofacial Pathology, Oral Health Research Center, Institute of Health, School of Dentistry, Babol University of Medical Sciences, Babol, Iran.

^bDept. of Oral & Maxillofacial Pathology, School of Dentistry, Babol University of Medical Sciences, Babol, Iran.

^cDept. of Oral & Maxillofacial Surgery, School of Dentistry, Babol University of Medical Sciences, Babol, Iran.

^dDept. of Oral & Maxillofacial Radiology, School of Dentistry, Babol University of Medical Sciences, Babol, Iran.

Correspondence to Safoura Seifi (email: sf_seify@yahoo.com).

(Submitted: 11 December 2018 – Revised version received: 18 February 2019 – Accepted: 30 February 2019 – Published online: Fall 2018)

Objectives Cementoblastoma is a rare benign odontogenic tumor which is linked to the root of a vital tooth. This tumor is usually accompanied by pain and swelling, and its most common site is the left mandibular first molar. General dentists' inattention to oral lesions, especially tooth-related radiopacities, is problematic in some cases and results in delayed or missed diagnosis.

Case Our patient was a 31-year-old woman who presented to our clinic complaining of dull pain in the left mandibular first molar. Root canal therapy was performed for the patient but the pain continued for the next 2 years. The patient was referred to a surgeon. Panoramic radiography revealed a radiopaque mass of approximately 2 x 1 cm in diameter attached to the root of the mandibular left first molar. The lesion together with the involved tooth was removed by excisional biopsy. Histopathological diagnosis was cementoblastoma.

Conclusion Dentists' knowledge of pulpal, periapical and periodontal lesions is usually satisfactory, but their inattention to oral lesions, especially tooth-related radiopaque lesions, is problematic in some cases. Pain from cementoblastoma may be mistaken for endodontic pain.

Keywords Dental Cementum; Mandible; Odontogenic Tumors

Introduction

Cementoblastoma is a rare benign odontogenic tumor producing cementum¹. This lesion is the only genuine neoplasm with a cementum origin that usually occurs in young men around the roots of second premolars or first molars of the mandible². Cementoblastoma is attached to the root of the tooth and surrounds it³. This neoplasm grows slowly and unrestrictedly and can be completely asymptomatic. However, in symptomatic cases, pain and swelling are common findings^{2,3}. It is prevalent in the third and fourth decades of life, and mostly occurs in permanent teeth and rarely in deciduous teeth².

On X-ray examination, cementoblastoma is usually seen as a radiopaque mass with a specific area and a thin radiolucent rim connected to the root of the involved teeth. Erosion of the tooth root and loss of the periodontal ligament space are the common radiographic findings⁴. Histopathologically, the tumor has distinct borders with a pseudo-cement tissue surrounded by a fibrous capsule². The treatment of this neoplasm often involves removing the affected tooth and the tumor; however, if the size of the lesion is small, root canal therapy is performed and long-term follow-ups are recommended^{3,5,6}.

Correct diagnosis and efficient treatment planning are the most important steps in dental clinics. Typical symptoms such as pain, pain on percussion, and jaw swelling usually originate from the teeth. General dentists usually identify endodontic lesions characterized by dental pain. However, they may misdiagnose or mistreat non-endodontic lesions

associated with dental pain because of the lack of knowledge about such lesions. In summary, to prevent misdiagnosis, dental history should be taken and radiographic examination and electric pulp testing are also recommended⁷.

Herein, we report a case of cementoblastoma that was first misdiagnosed as an endodontic lesion.

Case Report

Our patient was a 31-year-old female presented to our dental school clinic complaining of dull pain and pyorrhea in the posterior mandible and mandibular left first molar. The patient recalled visiting a dentist 2 years earlier for a toothache, and the dentist performed a poor root canal treatment. However, the pain persisted and the patient was referred to our dental school clinic. On extra-oral examination, no asymmetry was seen in the patient's face, and there was no history of systemic diseases. On oral examination, a normal oral mucosa was observed with no swelling. Differential diagnosis included cementoblastoma, ossifying fibroma and periapical cemento-osseous dysplasia. The patient's panoramic radiograph showed a radiopaque mass of approximately 2 x 1 cm in diameter attached to the root of the mandibular left first molar with no displacement of the adjacent teeth and a radiolucent rim around the radiopaque mass. The lesion together with the involved tooth was removed by excisional biopsy (Figures 1 and 2).

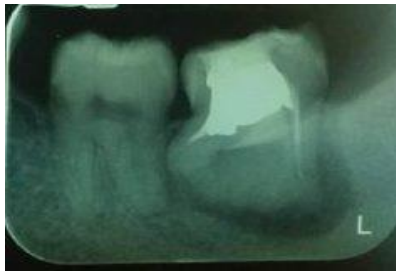


Figure 1- Radiologic view of cementoblastoma

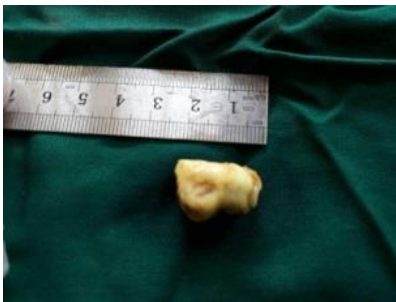
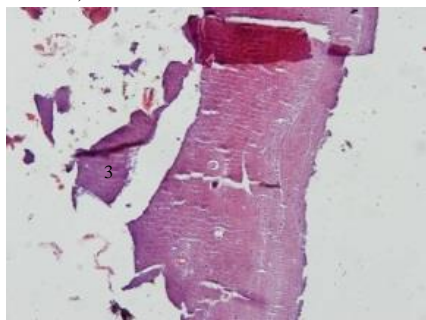
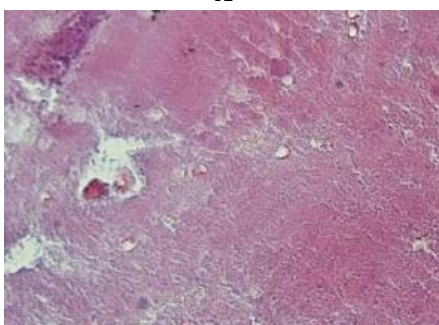


Figure 2- Gross view of cementoblastoma

On macroscopic examination of the biopsied lesion, a molar segment 2 x 1.4 x 0.7 cm in size with an irregular tissue and hard consistency was attached to the tooth root. On microscopic examination of the lesion, a calcifying tissue with irregular lacunae of cementocytes and clear basophilic reversal lines were observed. A brush border was seen on the side margin of the calcifying mass. The stroma was fibro-vascular, containing intense inflammatory infiltration and a dentine structure (dentin tubules) attached to the cement (Figure 3). A diagnosis of cementoblastoma was made. There was no recurrence on the 8-month follow-up (Figures 4 and 5).



A

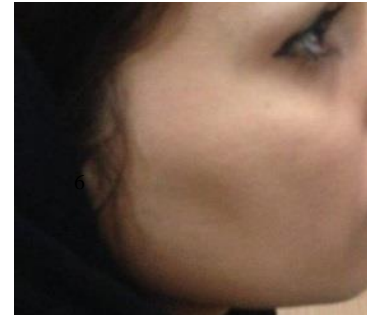


B

Figure 3- H&E staining of cementoblastoma (x10)(A)- (x40)(B)

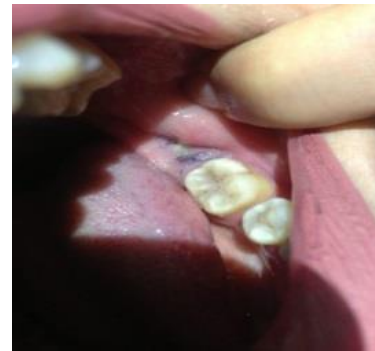

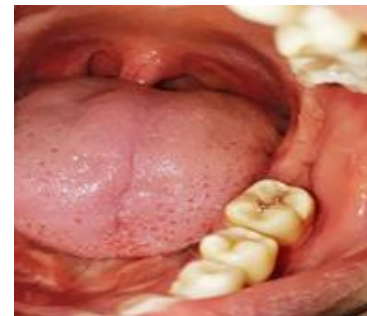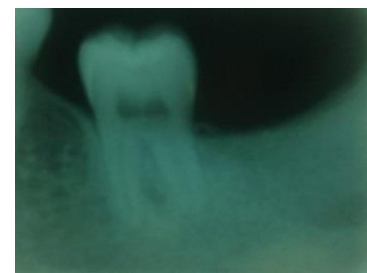Figure 4- Clinical view after treatment



A



B



C

Figure 5- Clinical (A and B) and radiographic view (C) after treatment

Discussion

Cementoblastoma is an uncommon slow growing odontogenic tumor, although some case reports are available regarding its aggressive behavior. Cementoblastoma is common in adult male patients. Most patients have dull pain and swelling at the beginning. The presentation of this case was unusual since it was misdiagnosed as an endodontic lesion^{6,7}. Dental pain has different causes. Proper and timely diagnosis and the dentist's knowledge about oral lesions

and their differentiation seem to be necessary for assessment of pulpal and periapical pain and periodontal diseases⁸. In this case report, the patient was a 31-year-old female who was referred to a maxillofacial surgeon for long-term dull pain of the mandibular left first molar that did not improve with root canal treatment. It seems that the dentist's lack of attention to a radiopaque lesion attached to the mandibular left first molar was the main reason for persistent pain. Maxillary radiopacities are mostly low-risk and include exostosis, torus, and reactive and neoplastic lesions⁸. In a review of the literature, only 5 of 56,836 patients with oral lesions associated with pain and swelling had cementoblastoma⁹. In our case report, the patient's chief complaint was dull pain from 2 years ago but there was no marked swelling. This tumor is more common in the mandible in men, and in the second and third decades of life, but rare cases have been reported in the maxilla and sinus. Costa et al.¹⁰ reported a case of cementoblastoma in an 18-year-old man complaining of pain and swelling of the right mandible. Imaging showed a radiolucent-radiopaque mass and a vital tooth. Paranjyothi et al.¹¹ reported a cementoblastoma in the maxillary first bicuspid. Caliskan et al.¹¹ reported cementoblastoma in a 31-year-old woman as a painless swelling in the mandible. X-ray imaging showed a radiopaque mass with a radiolucent rim. Sumer et al.¹² reported cementoblastoma in a 46-year-old man with complaints of pain, trismus, and swelling in the mandibular third molar for the past two months. Pain and swelling appear to be the main clinical symptoms of cementoblastoma. An asymptomatic lesion has been rarely reported in temporary teeth in some cases. There are extremely rare reports of multiple cementoblastomas⁶. In the present case report, radiographic examination revealed a radiopaque lesion with a radiolucent rim. The radiolucent form of cementoblastoma is the first stage of the disease, i.e. a non-calcified matrix. Due to the large similarity of the histopathology of bone defects, clinical presentation and radiography are very helpful in making a definite diagnosis¹⁴. The clinical differential diagnosis of cementoblastoma includes osteoblastoma, osteoid osteoma and ossifying fibroma. Cementoblastoma and osteoblastoma are similar in terms of location and histopathology, but osteoblastoma is usually larger than 2 cm. Superior lesions originate from the medullary bone and have no correlation with the tooth root. Although osteoid osteoma and cementoblastoma are painful lesions, the pain resolves with aspirin in osteoid osteoma. Cementoblastoma is a mass attached to the vital tooth root. Ossifying fibroma is not usually attached to the tooth; the mass can be removed completely and distinctly from the surrounding bone during surgery. The patient usually has no pain unless the lesion is very large; therefore, it is not difficult to differentiate it from cementoblastoma, which is completely attached to the tooth¹⁵. Other differential diagnoses of cementoblastoma include

odontoma, periapical cemento-osseous dysplasia, hypercementosis, condensing osteitis and gigantiform cementoma.

Odontoma is a heterogeneous radiodensity that has no correlation with the tooth root. Hypercementosis is a smaller, painless, non-inflammatory lesion that has no attachment to the tooth. Osteitis is seen in young individuals and the affected tooth is non-vital. Gigantiform cementoma usually presents with multifocal radiopacities in the mandible and maxilla⁶. Periapical cemento-osseous dysplasia is a painless reactive lesion with its common location being in the anterior mandibular region. Pathologically, it has osteolytic and cementoblastic phases. It manifests as a radiolucent or radiolucent-radiopaque lesion on radiologic examination and is usually self-limiting¹⁶.

Treatment of cementoblastoma includes complete removal of the lesion with curettage and peripheral ostectomy associated with removal of the tooth involved, which was performed in our case. However, in cases with small cementoblastoma, root canal treatment is usually associated with tooth root cut. Recurrence is possible^{3, 6}, but no recurrence was observed in our patient on the 8-month follow-up.

In this case report, the dentist was not aware of the vitality of the mandibular left first molar. He performed endodontic treatment because the patient complained of severe pain in the mandibular left first molar. However, the pain did not resolve after 2 years. Further evaluation showed that the mandibular left first molar had a poor endodontic treatment. The patient's history, radiographic examination, clinical differential diagnosis, and vitality testing are necessary to make a definite diagnosis. If clinical vitality testing and radiographic examinations are not sufficient for a definite diagnosis, biopsy and histopathological examination are indicated. Keyes et al. (ref) reported a case of cementoblastoma in a 12-year-old female with pain and swelling in the anterior teeth. A radiolucent-radiopaque periapical lesion was seen around the tooth apex. The pain did not improve after endodontic treatment. Therefore, surgical treatment was performed successfully. Correct diagnosis and treatment planning are the most important steps in dental clinics. Dentists may misdiagnose or mistreat lesions because of their poor knowledge about lesions associated with dental pain. In summary, to prevent misdiagnosis, general dentists should consider dental history, radiographic examination, and electric pulp testing as part of dental pain evaluation.

Conclusion

Dentists' knowledge about pulpal, periapical and periodontal lesions is usually satisfactory, but lack of attention to oral lesions, especially tooth-related radiopaque lesions, is problematic in some cases and results in delayed

or missed diagnosis. Cementoblastoma is a rare benign odontogenic tumor that should be included in the list of differential diagnosis of dental pain and swelling.

Acknowledgement

The authors would like to thank Mr. Mohammadi for

staining of slides.

Conflict of Interests

None Declared ■

References

1. Aiyer RG, Rajagopal S. Benign cementoblastoma - a rare odontogenic neoplasm. *Indian J Otolaryngol Head Neck Surg.* 2000 Jul;52(3):272-3.
2. Brannon RB, Fowler CB, Carpenter WM, Corio RL. Cementoblastoma: An innocuous neoplasm? A clinicopathologic study of 44 cases and review of the literature with special emphasis on recurrence. (*Oral Surg Oral Med Oral Pathol Oral Radiol Endod* 2002 Mar;93:311-20)
3. Pynn BR, Sands TD, Bradley G. Benign Cementoblastoma: A Case Report. *J Can Dent Assoc* 2001 May; 67:260-2.
4. Pacifici L, Tallarico M, Bartoli A, Ripari A, Cicconetti A. Benign cementoblastoma: a clinical case of conservative surgical treatment of the involved tooth. *Minerva Stomatol.* 2004 Nov-Dec;53(11-12):685-91.
5. Sharma N. Benign cementoblastoma: A rare case report with review of literature. *Contemp Clin Dent.* 2014 Jan;5(1):92-4.
6. Iannaci G, Luise R, Iezzi G, Piattelli A, Salierno A. Multiple cementoblastoma: a rare case report. *Case Rep Dent.* 2013 Jul;2013:828373.
7. Roneda M, Suzuki N, Macedo S, Anan H, Hirofujii T. Confusing endodontic cases. *Cases Series. Smile Dental J* 2011;26-31.
8. Jafari ashkevandi Z, Haghnegahdar A.A, Amanpoor S. Cementoblastoma of the Maxilla: Report of a Rare Case with Delayed Diagnosis. *Shiraz Univ Dent J* 2011; 12(1): 84-89.
9. Huvar RJ, Butura CC. Benign cementoblastoma: report of case. *CDS Rev.* 1995 Sep;88(8):36-7.
10. Costa BC, Oliveira GJ, Chaves MD, da Costa RR, Gabrielli MF, Guerreiro-Tanomaru JM, et al. Surgical treatment of cementoblastoma associated with apicoectomy and endodontic therapy: Case report. *World J Clin Cases.* 2016 Sep 16;4(9):290-5.
11. Çalışkan A, Karöz TB, Sumer M, Açıkğöz A, Süllü Y. Benign cementoblastoma of the anterior mandible: an unusual case report. *J Korean Assoc Oral Maxillofac Surg.* 2016 Aug;42(4):231-5.
12. Sumer M, Gunduz K, Sumer AP, Gunhan O. Benign cementoblastoma: A case report. *Med Oral Patol Oral Cir Bucal.* 2006 Nov 1;11(6):E483-5.
13. Monti LM, Souza AM, Soubhia AM, Jorge WA, Anichinno M, Da Fonseca GL. Cementoblastoma: a case report in deciduous tooth. *Oral Maxillofac Surg.* 2013 Jun;17(2):145-9.
14. He X, Li K, Huang Y, Liu S. Mandibular cementifying fibroma and cementoblastoma: a case report. *Int J Clin Exp Med.* 2017 Mar;10(3):5475-9.
15. Senia ES, Sarao MS. Periapical cement-osseous dysplasia: a case report with twelve-year follow-up and review of literature. *Int Endod J.* 2015 Nov;48(11):1086-99.

How to cite:

Safoura Seifi, Marjan Kiani, Alireza Babaei Darzi, Hakimeh Ghorbani. Cementoblastoma of the Mandible: A Case Report and Review of Literature. *J Dent Sch* 2018;36(4):140-143.