

# Evaluation of canonical correlations between masticatory muscle orientation and craniodentofacial morphology in 10-17 year-olds

Vahid Zand,<sup>a</sup> Morteza Oshagh,<sup>b\*</sup> Nariman Iraj Nasrabadi,<sup>c</sup> Parvin Kharazi,<sup>b</sup> and Fatemeh Bahramnia<sup>b</sup>

<sup>a</sup>Endodontist, Dental and Periodontal Research Center, Dental School, Tabriz University of Medical Sciences, Tabriz-Iran.

<sup>b</sup>Orthodontist, Private Practice.

<sup>c</sup>Dentist, Private Practice.

\*Correspondence to: Morteza Oshagh (email: morteza\_oshagh@yahoo.com).

(Submitted: 04 April 2017 – Revised version received: 27 May 2017 – Accepted: 05 June 2017 – Published online: Spring 2017)

**Objectives** Different theories have been suggested to define factors involved in skeletal and craniofacial morphology. Many of these theories explain that the bone morphology is the result of the bone tissue capability to adapt in response to biomechanical forces exerted during growth. Also, it seems logical to hypothesize that there is a relationship between biomechanical connections of muscles to bones with the morphology of musculodentofacial complex. A few studies have evaluated muscle orientation in different skeletal occlusions (class I, II and III). The aim of this study was to evaluate correlations between masticatory muscle orientation and craniodentofacial morphology in different skeletal malocclusions.

**Materials and Methods** A total of 160 lateral cephalograms of patients between 10–17 years in a dental clinic were evaluated for the orientation of masticatory muscles and craniofacial morphology. All cephalograms were traced and confirmed by an orthodontist. Thirty-seven parameters (skeletal, dental, muscular) were measured. For statistical analysis, canonical correlation, variation and linear regression analysis were performed.

**Results** Increase of the masseter muscle angulation was accompanied by a more superior position of the muscle in female subjects with Class II malocclusion. Increase of temporalis muscle angulation was seen in long face males. Increase of the masseter muscle angulation and its higher position were seen in short face males.

**Conclusion** Increase of the masseter muscle angulation was accompanied by a more superior position of the muscle in female patients with class II properties. Increase of temporalis muscle angulation was seen in male patients with long face characteristics. Increase of the masseter muscle angulation and its higher position were seen in male patients with short face properties.

**Keywords** correlations, craniodentofacial, morphology, masticatory muscles

## Introduction

The relationship between the masticatory muscle function and skull form is the key to understand the functional determinants of phenotypic evolution.<sup>1,2</sup> There is still doubt that it might be the other way around and genetically affected facial features may determine muscular characteristics.<sup>3</sup> Kiliaridis et al.<sup>4</sup> reported that subjects with heavy bite forces have anteriorly positioned masseter, shorter anterior facial height and smaller gonial angle compared to those who have shorter posterior facial height and bigger gonial angle. These findings were later confirmed by Becht et al.<sup>5</sup> who used cone beam computed tomography (CBCT) to evaluate the masseter muscle with regard to different facial heights and occlusions and reported that the hyper divergent group (long face) had the shortest muscle length and subjects with class II malocclusion had the most acutely angulated masseter orientation. Herring<sup>6</sup> suggests that bite forces can provide sufficient force to distract the sagittal suture of the skull. Takada et al.<sup>7</sup> studied 55 samples and suggested that there is an association between the features that are generally observed in skeletal open bite subjects such as anterior inclination of masseter muscle relative to the occlusal plane with superior positioning of its origin and a short posterior facial height with a steep mandibular plane and a large gonial angle. They also concluded that in correspondence to alterations in the dimension and position of craniofacial structures subsequent to growth, the masseter muscle insertion site is positioned inferiorly and the temporalis muscle reaches for an anterior and slightly inferior position relative to the occlusal plane. Contrary to the findings of Takada et al.,<sup>7</sup> Chan et al.<sup>3</sup> could not establish a

relationship between the masseter inclination and the occlusal plans but they observed an acute angulation in muscle orientation in long face subjects. Gionhaku and Lowe<sup>8</sup> studied the relation between the skull, masticatory muscles and dentofacial morphology. They reported that the masseter muscle volume was negatively correlated with the mandibular plane and gonial angle and positively correlated with the posterior facial height, ramus height and gonion to pterygomaxillary fissure distance.

According to the above-mentioned studies, it seems logical to hypothesize that there is a relationship between biomechanical connections of muscles to bones with the morphology of musculodentofacial complex.

There are a few studies which have evaluated muscle orientation in different skeletal occlusions (class I, II and III). Hence, this study was designed to evaluate the correlations between the masticatory muscle orientation and craniodentofacial morphology in different skeletal occlusions.

## Materials and Methods

A total of 160 patients (40 boys, 120 girls) presenting to the radiology unit of a private dental clinic were randomly enrolled. The inclusion criteria were as follows: 1) The image was of sufficient quality to allow identification of landmarks. 2) All patients were in permanent dentition period and their age ranged from 10 to 17 years. There were no unerupted or partially erupted teeth that could have hindered landmark identification. 3) The patients had different skeletal occlusions

and none of them had a history of orthodontic treatment. The demographic information of the participants is shown in Table 1.

The cephalometric equipment included an X-ray unit (Planmeca Pro Expert) and a tube together with a cephalostat. The conventional cephalograms were taken with patients in fixed head position in the cephalostat in natural head position.

Cephalograms were hand-traced by two dental students under the supervision of an expert orthodontist. Tracings were performed on tracing papers by 0.5 mm pencil. Then, the common landmarks and planes were identified on tracings. The landmark position could be corrected until the operators were satisfied. All tracings and assessments were made in a dark room on a negatoscope to ensure contrast enhancement of images.

Twenty cephalograms were then randomly selected and controlled by the supervisor (orthodontist). To assess intra and inter-examiner reliability, each student re-evaluated 10 cephalograms and the differences between the two measurements and also the two examiners were not statistically significant. All points and contours necessary for evaluation of dentoskeletal measurements were defined. The selected muscular and dentoskeletal variables were categorized into subgroups to be used in canonical analysis. Fig. 1<sup>7</sup> depicts the main variables and their measurement schematically. The variables are shown in Tables 2, 3, and 4.

Table 1. Demographic information of the participants

Total (n%)	Gender (n%) Male	Gender (n%) Female	Malocclusion
94(58.75)	20(12.5)	74(46.25)	Class I
47(29.375)	13(8.125)	34(21.25)	CLII divl
7(4.375)	2(1.25)	5(3.125)	CLII divl
12(7.5)	5(3.125)	7(4.375)	CL III
160(100)	40(25)	120(75)	Total

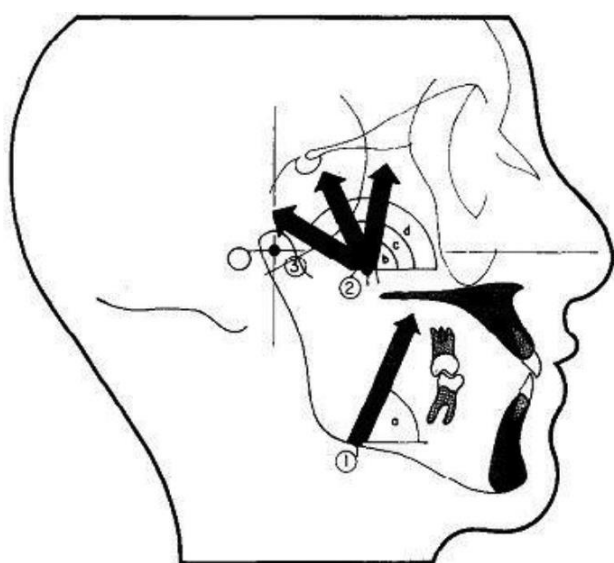


Fig 1. Muscle orientation angles relative to the occlusal plane and insertion coordinates relative to a line parallel to the occlusal plane registered at CC. (a), opemas; (b), opeat; (c), opemt; (d), opopt; (1), IMx, IMy; (2), PCx, PCy; (3), CC.

Table 2. Muscle orientation variables used in canonical analysis<sup>5</sup>

Variable	Interpretation
opemas	Masseter muscle angulation
[opeat + opemt + opopt]	Temporalis muscle angulation
IMx	Horizontal coordinate of masseter
IMy	Vertical coordinate of masseter
PCx	Horizontal coordinate of temporalis
PCy	Vertical coordinate of temporalis

Table 3. Dentoskeletal variables used in canonical analysis<sup>5</sup>

Variable	Interpretation
[1 to NA + 1 to SN + 1 to FH]	Maxillary incisor inclination
[SNMP + FMA + Y.axis]	Mandibular angulation
[1 to IMPA + 1 to NB]	Mandibular incisor inclination
[1 to MP(mm) + MdMH(mm)]	Mandibular tooth height
[ADH(mm) + MxMH(mm)]	Maxillary tooth height
[SN-PG + Facial]	Anteroposterior position of pogonion
[PFH + RH]	Posterior facial height
MxUL	Maxillary unit length
SN-Occ	Occlusal plane inclination
OJ	Over jet
OB	Over bite
MdUL	Mandibular unit length
SNB	Anteroposterior position of mandible
LFH	Lower facial height
SNA	Anteroposterior position of maxilla
UFH	Upper facial height
SN-Pal	Maxillary angulation

Table 4. Definition of muscular variables used to evaluate the orientation of muscles<sup>5</sup>

Variable	Definition
opemas	Superficial masseter muscle orientation. The angle between the occlusal plane and a line parallel to the line connecting the key ridge and antegonion through the insertion point of the muscle.
opeat	Anterior temporalis muscle angulation. The angle between the occlusal plane and a line through muscle insertion on the coronoid process and origin of anterior temporalis.
opopt	Posterior temporalis muscle angulation. The angle between the occlusal plane and a line through muscle insertion on the coronoid process and origin of posterior temporalis.
opemt	Medial temporalis muscle angulation. The angle between the occlusal plane and a bisector of anterior and posterior temporalis muscle lines.

## Canonical Correlation Analysis

The canonical correlation analysis is a statistical method which is used to describe the dependence of two groups of variables. To investigate the association between the masticatory muscle orientation and dentoskeletal morphology, canonical correlations were defined for the data gathered from 160 cephalograms. Coefficients of canonical variables were chosen so that the correlation was as high as possible. The significance of the canonical correlations can be tested by using Bartlett's chi-square test. If none of the canonical variables is significant, there is no correlation or inter-dependence between the two groups; which means there is no linear combination of variables in the first group which is significantly correlated with a linear combination of variables in the second group. Even if none of the pairwise correlations is significant, it is still possible to find significant canonical variables.

The significance of a single correlation coefficient can be tested by means of Fisher's Z transformation. In the present study, the significance level was set at 5%.

Data were analyzed with SPSS version 18 software (SPSS Inc., Chicago, IL). MS Excel and MS Word were used to generate tables and graphs.

## Results

The patients had class I (94 patients), class II (54 patients) and Class III (12 patients) skeletal occlusions.

### *opΘmas*

In female patients, protrusion of the upper central incisors (1 to SN;  $P = 0.001$ ), retrusion of the chin (SN-Pog;  $P = 0.01$ ), decrease in SN-Occ plane angle ( $P = 0.01$ ), increase in overjet and decrease in SNB ( $P = 0.03$ ) were observed with an increase in *opΘmas*. Overall, an increase in *opΘmas* in female patients was accompanied by development of class II characteristics.

In male patients, increase in *opΘmas* was observed in those with decrease in posterior facial height (PFH;  $P = 0.04$ ), length of maxilla (MxUL;  $P = -0.03$ ), length of mandible (MdUL;  $P = -0.05$ ) and lower facial height (LFH;  $P = -0.03$ ). Generally, increase in *opΘmas* was seen in male patients with short face properties and retrusion of the base of the maxilla and mandible.

In male patients, increase of the temporalis muscle angulation was accompanied by increase in lower facial height and increase in SN-Occ plane angle.

### *PCx*

Increase in the length of maxilla (MxUL;  $P = 0.04$ ), decrease in SN-Occ plan angle ( $P = -0.04$ ), decrease in the length of mandible (MdUL;  $P = -0.002$ ) and increase in SNA ( $P = 0.04$ ) and SNB ( $P = 0.03$ ) angles were seen in female patients with increase in PCx. Overall, increase in PCx was accompanied by class III characteristics which is more anterior position of the mandible.

### *PCy*

In female patients, increase in PCy was observed in samples with increase in SN-Occ plane angle ( $P = 0.000$ ) and decrease of SNA ( $P = -0.03$ ) and SNB ( $P = -0.03$ ), but in male patients, increase of PCy was accompanied by an increase of the mandibular plane angle (SN-Mand;  $P = 0.05$ ), increase of

SN-Occ plane angle ( $P = 0.003$ ) and increase of LFH ( $P = 0.02$ ). Overall, a more anteriorly and inferiorly positioned PC (temporalis muscle insertion) was accompanied by decrease of SN-Occ (superior rotation of the occlusal plane) and increase of SNA and SNB.

### *IMx*

The increase of IMx indicates a more anterior position of masseter insertion. In female patients, increase in IMx was observed in patients with increase of SN-Occ plane angle ( $P = 0.04$ ). In male patients, increase of IMx was accompanied by retrusion of pogonion (SN-Pog;  $P = 0.0003$ ) and increase of the length of maxilla and overall intensification of class II properties.

### *IMy*

Increase of IMy means a more superior position of muscle insertion. In female patients, increase in IMy was observed in patients with decrease in 1 to MP ( $P = 0.01$ ) and PFH ( $P = 0.01$ ). It was also accompanied by some features like increase of SN-Occ plane angle ( $P = 0.01$ ), decrease of mandibular length (MdUL;  $P = 0.02$ ) and decrease in SNB ( $P = 0.05$ ), LFH ( $P = 0.02$ ) and UFH ( $P = 0.004$ ).

In male patients, increase of IMy was seen in those showing a decrease in PFH ( $P = 0.01$ ), MdUL ( $P = 0.009$ ) and UFH ( $P = 0.01$ ) which implies that in both male and female patients, increase of IMy was accompanied by class II and short face features.

## Discussion

Masseter and temporalis muscle orientations are mostly related to skeletal features and little connection was found with dental factors. In this study, decrease of masseter and temporalis angulation (*opΘmas* and *opΘtemp*) and also more anterior and superior position of masseter insertion were accompanied by class II features. This corresponds to the findings of Takada et al.<sup>7</sup> Also, Peterson<sup>9</sup> found a more anteriorly inclined masseter, relative to sella-nasion plane, in class II patients. But Peterson<sup>9</sup> found the same masseter muscle attachment sites when comparing class I and class II cases. Becht et al.<sup>5</sup> also observed the same pattern. Although the muscle length did not differ among the malocclusion classes, the class II type tended to have a more acutely angled masseter than class III who had a more obtuse muscle orientation. With respect to muscle length, they observed that long face cases had the shortest muscle length.

In our study, the angulated masseter orientation was accompanied by short face features. This is in contrast with the findings of Takada et al.<sup>7</sup> who stated that, these muscular features were accompanied by skeletal open bite properties. However, gender was not studied separately in their research.

Proctor and DeVincenzo<sup>10</sup> also concluded that masseter muscle inclination relative to SN was more horizontal in the open-bite group and more vertical in the closed-bite patients. But masseter inclination relative to the occlusal plane was not different in dolichofacial or brachifacial patients. Chan et al.<sup>3</sup> could not find a correlation between the masseter orientation and functional occlusal plane either.

In another study by Van Spronsan et al.,<sup>11</sup> the anterior facial height was significantly correlated with the orientation of the jaw

opening muscles in the sagittal plane but was not significantly correlated with the orientation of the mandibular elevators.

In this study, the insertion site of the masseter was more superior in patients with a reduction in PFH. This was also found by Takada et al.<sup>7</sup> They suggested an association between an anteriorly inclined masseter muscle relative to the occlusal plane and a superior position of its insertion site and a short posterior facial height with a steep mandibular plane and a large gonial angle. Since the ramal length is 7 mm less in open-bite group,<sup>10</sup> this superior position of muscle insertion is expected. This interpretation supports the concept proposed by Sassouni<sup>12</sup> and by Sassouni and Nanda<sup>13</sup> that in skeletal deep-bite cases the masseter muscle is attached anteriorly on the mandible and that it suggests a more vertical position. It would not be unreasonable to expect that in closed-bite individuals the masseter would be more anteriorly positioned but Proctor and DeVincenzo<sup>10</sup> compared the location of the anterior border of the masseter by palpation and found that the masseter muscle attachment sites are the same in skeletal open-bite and closed-bite subjects and suggested that relatively constant origin and insertion areas exist regardless of skeletal type.

It must be stated that muscle border differences seem to be an expression of both anteroposterior displacements of the mandible and the large differences in the gonial angles between patients.<sup>10</sup>

In our study, increase of temporalis angulation and more superior position of temporalis insertion were found in long face male subjects. This was in agreement with the study which stated that in open-bite group, the condyle is anterosuperiorly positioned, the ramus is shorter, the gonial angle is larger, and the mandible is rotated inferoposteriorly.<sup>10</sup>

Muscle loading generates mechanical strain in the mandibular bone surface which is affected by the change in loading direction and magnitude.<sup>14,15</sup> It was found that the strain in the zone of mandibular angle is greater under masseter loading, and the strain in the zone of anterior mandibular ramus is greater under temporalis loading.<sup>16</sup> It has also been suggested that this muscular activity affects the PFH rather than AFH since the growth in this region is more influenced by gonial angle and its muscles.<sup>17</sup>

It has been reported that the masseter muscle activity and/or maximum jaw-closing force are positively correlated with the posterior facial height and negatively correlated with the mandibular plane and gonial angle.<sup>18,19</sup> Throckmorton and associates<sup>20</sup> in their model analysis showed that the elevator muscles have an increased mechanical advantage when the gonial angle is acute and the mandibular plane is flat. Lione et al.<sup>21</sup> who measured muscle volume by ultra-sonography also showed that the masseteric volume showed a 10% decrease from brachyfacial to dolichofacial cases.

This was confirmed by Wong et al.<sup>22</sup> who studied muscle volume and angulation by computed tomography. They observed that a less acute muscle angulation and increased muscular volume were accompanied by increased facial width in brachyfacial patients.

In the present study, more posterior and superior position of temporalis insertion and more anterior and superior position of masseter insertion were observed in subjects with clockwise rotation of occlusal plane which is consistent with the findings of Takada et al.<sup>7</sup>

Proctor and DeVincenzo<sup>10</sup> concluded that the angle of muscle border to occlusal plane and the ramal plane and the

distances from the muscle to the first molar and to gonion are quite close in value in open bite and deep bite groups. The constant angular relationship between the muscle border and occlusal plane might suggest a definite relationship between the dentition and muscular forces irrespective of mandibular or maxillary shape or position. As explained by Rohila et al.,<sup>23</sup> the weaker muscles in long face subjects may lead to over eruption of molars and thus rendering the subject with an increased facial height while contraction forces in short face individuals create a more acute gonial angle.

Takada et al.<sup>7</sup> found a growth-related correlation between the masticatory muscle insertion positions relative to the occlusal plane and the dimensional and positional changes of craniofacial structures during growth. In their study, in later stages of growth, the masseter muscle insertion was positioned inferiorly and the temporalis muscle insertion assumed to have an anterior and slightly inferior position relative to the occlusal plane.

In a cephalometric analysis, one should be careful to interpret the results obtained in terms of possible effect of the variation of the reference plane. For example, as the occlusal plane is steepened, the muscle angulation relative to the occlusal plane linearly increases. The fluctuation of the X and Y coordinates of the muscle insertion sites depends upon the distances of these points from the origin. The masticatory muscle inclinations, the X coordinate of the masseter muscle insertion site, and the Y coordinate of the temporalis muscle insertion site all increase in accordance with an anteriorly inclined occlusal plane.<sup>7</sup>

It is interesting to note that nearly all the differences in masseter muscle position and inclination relative to craniofacial measurements between different skeletal types can be explained by the anteroposterior position of the mandible.<sup>10</sup> Another limitation of this study was that the muscle force vector on the radiographs is not a real vector. Also, the number of male patients in this study was less than females which suggests that in future studies the number of males and females should be equal.

In the study by Proctor and DeVincenzo<sup>10</sup> approximately 20% of the patients showed a muscle angulation difference of more than 6° between the right and left sides. Likewise, the anteroposterior position of the muscle on the left and right sides varied by more than 6 mm in 30% of the patients. This finding does indicate the variability in size and/or position of muscular elements between the two sides of the face. However, part of this difference could be attributed to variations in the cephalometric technique.

In this study, the masseter muscle orientation was defined as the angle between the occlusal plane and a line parallel to the line connecting the key ridge and antagonist through the insertion site of the muscle. The interpretation of such measurements should be done with caution since the single superficial masseter muscle line determined does not necessarily correspond to the overall force vector of the superficial and deep masseter muscle.<sup>7</sup> Similarly, the temporalis muscle angulation, which was expressed by the linear combination of three different angulations, is not necessarily equivalent. It has been shown that a complex muscle may exhibit differential activity.<sup>24</sup>

Since the age of our patients was between 10 to 17 years old, some remaining skeletal growth might change the position or angulation of muscles. Carlson<sup>25</sup> found that during



the growth of the masseter muscle in rhesus monkeys, it migrates in a posterior and slightly superior direction relative to the mandible. It was proposed that this provides stability for the anteroposterior position of the masseter muscle despite the anterior displacement of the mandible during growth. The insignificant canonical variable loading for IMx in the study by Takada et al.<sup>7</sup> may imply that a similar positional change of the masseter muscle could occur in growing children. In some studies, age was not a significant determinant of variation in dimensions or orientation of the superficial masseter muscle.<sup>26,27</sup>

Despite the limitations of interpretation in any two-dimensional cephalometric study, the canonical correlations

between the masticatory muscle orientation and dentoskeletal morphology identified in this and another report<sup>7</sup> shed some light on our understanding of the contribution of muscle orientation to the development of occlusion.

## Conclusion

Increase of the masseter muscle angulation was accompanied by a more superior position of the muscle in female patients with class II properties. Increase of temporalis muscle angulation was seen in male patients with long face characteristics. Increase of the masseter muscle angulation and its higher position were seen in male patients with short face properties. **n**

## References

1. Demes B. Another look at an old face: Biomechanics of the Neandertal facial skeleton reconsidered. *J Hum Evol*. 1987;16:297–303.
2. Spencer M, Demes B. Biomechanical analysis of masticatory system configuration in Neandertals and Inuits. *Am J Phys Anthropol*. 1993;91:1–20.
3. Chan HJ, Woods M, Stella D. Mandibular muscle morphology in children with different vertical facial patterns: A 3-dimensional computed tomography study. *Am J Orthod Dentofacial Orthop*. 2008;133:10.e1–e13.
4. Kiliaridis S, Johansson A, Haraldson T, Omar R, Carlsson GE. Craniofacial morphology, occlusal traits, and bite force in persons with advanced occlusal tooth wear. *Am J Orthod Dentofacial Orthop*. 1995;107:286–292.
5. Becht MP, Mah J, Martin C, Razmus T, Gunel E, Ngan P. Evaluation of masseter muscle morphology in different types of malocclusions using cone beam computed tomography. *Int Orthod*. 2014;12:32–48.
6. Kiliaridis S. Masticatory muscle influence on craniofacial growth. *Acta Odontol Scand*. 1995;53:196–202.
7. Takada K, Lowe AA, Freund VK. Canonical correlations between masticatory muscle orientation and dentoskeletal morphology in children. *Am J Orthod*. 1984;86:331–341.
8. Gionhaku N, Lowe AA. Relationship between jaw muscle volume and craniofacial form. *J Dent Res*. 1989;68:805–809.
9. Peterson DD. Masseter muscle position relative to dento-skeletal elements, Master's Thesis, Washington University, St. Louis, Missouri, 1966.
10. Proctor AD, DeVincenzo JP. Masseter muscle position relative to dentofacial form. *Angle Orthod*. 1970;40:37–44.
11. Van Spronsen PH, Koolstra JH, Van Ginkel FC, Weijs WA, Valk J, Prahl-Andersen B. Relationships between the orientation and moment arms of the human jaw muscles and normal craniofacial morphology. *Eur J Orthod*. 1997;19:313–328.
12. Sassouni V. A classification of skeletal facial types. *Am J Orthod*. 1969;55:109–123.
13. Sassouni V, Nanda SK. Analysis of dentofacial vertical proportions. *Am J Orthod*. 1964;50:801–823.
14. Usui T, Maki K, Toki Y, Shibasaki Y, Takanobu H, Takanishi A, et al. Measurement of mechanical strain on mandibular surface with mastication robot: influence of muscle loading direction and magnitude. *Orthod Craniofac Res*. 2003;6:163–167.
15. Ferré JC, Barbin JY, Helary JL, Lumineau JP. The mandible, an overhanging mechanically suspended structure. Considerations on the system of attachment and servo-command of, the mandible. *Surg Radiol Ana*. 1984;6:3–10.
16. Wang H, Chen MS, Tian WD, Li SW. Stress distribution of mandible under different loading and biting condition. [Article in Chinese]. *Sichuan Da Xue Xue Bao Yi Xue Ban*. 2004;35:516–519.
17. Boom HP, van Spronsen PH, van Ginkel FC, van Schijndel RA, Castelijns JA, Tuinzing DB. A comparison of human jaw muscle cross-sectional area and volume in long- and short-face subjects, using MRI. *Arch Oral Biol*. 2008;53:273–281.
18. Ringqvist M. Isometric bite force and its relation to dimensions of the facial skeleton. *Acta Odontol Scand*. 1973;31:35–42.
19. Tabe T. A study on the activities in the masticatory muscles and the morphology of the orofacial skeleton. II. The correlation between the activities in the masseter muscle and the biting force, and the morphology of the orofacial skeleton. *J Jpn Orthod Soc*. 1976;35:255–265.
20. Throckmorton GS, Finn RA, Bell WH. Biomechanics of differences in lower facial height. *Am J Orthod*. 1980;77:410–420.
21. Lione R, Franchi L, Noviello A, Bollero P, Fanucci E, Cozza P. Three-dimensional evaluation of masseter muscle in different vertical facial patterns: a cross-sectional study in growing children. *Ultrasound Imaging*. 2013;35:307–317.
22. Wong A, Woods MG, Stella D. Three-dimensional computed tomographic assessment of mandibular muscles in growing subjects with different vertical facial patterns. *Aust Orthod J*. 2016;32:2–17.
23. Rohila AK, Sharma VP, Shrivastav PK, Nagar A, Singh GP. An ultrasonographic evaluation of masseter muscle thickness in different dentofacial patterns. *Indian J Dent Res*. 2012;236:726–731.
24. Herring SW, Grimm AF, Grimm BR. Functional heterogeneity in a multipinnate muscle. *Am J Anat*. 1979;154:563–576.
25. Carlson DS. Growth of the masseter muscle in rhesus monkeys (*Macaca mulatta*). *Am J Phys Anthropol*. 1983;60:401–410.
26. Kasai K, Richards LC, Kanazawa E, Iwasawa T. Cephalometric analysis of masseter muscle and dentoskeletal morphology in dentate and edentulous humans. *J Nihon Univ Sch Dent*. 1997;39:78–85.
27. Kasai K, Richards LC, Kanazawa E, Ozaki T, Iwasawa T. Relationship between attachment of the superficial masseter muscle and craniofacial morphology in dentate and edentulous humans. *J Dent Res*. 1994;73:1142–1149.

## How to cite:

Zand V, Oshagh M, Nasrabadi N I, Kharazi P, and Bahramnia F. Evaluation of canonical correlations between masticatory muscle orientation and craniodentofacial morphology in 10-17 year-olds. *J Dent Sch*. 2017; 35(2):71–75.