

Dental management of ectodermal dysplasia syndrome at an early age: a case report

Ghasem Ansari,^a Bahareh Nazemi,^{b*} and Amir Fayaz^c

^aDepartment of Pediatric Dentistry, Dental School, Shahid Beheshti University of Medical Sciences, Tehran, Iran.

^bDepartment of Pediatric Dentistry, Dental school, Zanjan University of Medical Sciences, Zanjan, Iran.

^cDepartment of Removable Prosthodontics, Dental School, Shahid Beheshti University of Medical Sciences, Tehran, Iran.

*Correspondence to: Nazemi B. (email: dr.b.nazemi@gail.com)

(Submitted: 17 January 2017 – Revised version received: 18 April 2017 – Accepted: 24 April 2017 – Published online: Summer 2017)

Objectives Ectodermal dysplasia (ED) is a relatively common sex-linked dermatitis characterized by congenital dysplasia of one or more ectodermal structures and their accessory appendages. Common manifestations include fragile skin and nails, defective teeth and salivary glands, frontal bossing with prominent supra orbital ridges, nasal bridge depression and protuberant lips. Teeth are often few in number (hypodontia or oligodontia) and have a conical form that results in generalized spacing. In extreme cases, both deciduous and the permanent dentition may fail to form (anodontia) and consequently, hypoplasia of the jaws may happen. This article reports a case of ED with its management protocol.

Methods A 4 year-old boy with hypohydrotic ED was referred to Dental School of shahid Beheshti University of Medical Sciences. Clinical examination revealed classical features of ED, with only a few teeth. He had fine scanty hair, dry skin and depressed nasal bridge. Removable denture was made with particular limitations for his lower jaw to restore esthetics and masticatory function. The existing upper teeth were initially reshaped using composite resin restoration material.

Conclusion Preventive treatments in ED patients are very important to save the existing teeth. In patients with oligodontia, removable dentures can be used as a cost-benefit and pleasant intermediate treatment to restore function and esthetics and improve patient's psychological status.

Keywords ectodermal, dysplasia, tooth abnormalities, child

Introduction

Ectodermal dysplasia (ED) is widely acknowledged as a rare inherited disorder characterized by defective development of tissues with ectodermal origin along with occasional dysplasia of mesodermal tissues.¹ It is usually characterized by the following three signs: Sparse hair (hypotrichosis), abnormal or missing teeth (hypodontia or oligodontia) and inability to sweat (anhidrosis or hypohydrosis). In case of presence of at least 2 types of these abnormal features, the diagnosis of ED would be suggested.² The incidence of ED is reported to be approximately 1 in 100,000 live births.³ The mortality rate of ED has been reported to be as high as 30 % at infancy and early childhood due to intermittent hyperpyrexia.⁴ Two different forms of the disease are clinically diagnosed: the 1st form is the Clouston syndrome. It is passed through an autosomal inheritance form. The 2nd is known as the Chris-Siemens syndrome (hypohidrotic form) and usually has X-linked recessive form of inheritance. The latter disorder is only expressed in men.⁵ Spontaneous gene mutation can also cause this condition.⁶

Clinical manifestations of ED include several facial abnormalities such as prominent forehead, saddle nose, thick lips, linear wise and hyper pigmentations around the eyes, hypoxemia and anodontia. Absence of teeth could lead to reduced alveolar bone growth, which often has a narrow and concave lingual clinical appearance.^{7,8} Infection may occur due to decreased function of lymphocytes and cellular immune hypofunction. One of the most important challenges faced in treatment of such patients is to achieve an improved appearance. Since the presence of teeth has a major influence on patients' self-esteem, such treatment is critically essential to be well defined. In this regard, providing any prosthetic replacement

for teeth is vital for such patients, which may include partial and complete dentures for their social engagements and attending school.^{9,10,11}

This article aimed to elaborate the characteristics and management of ED in a young patient through prosthetic rehabilitation and assess its effect on the patient's social life.

Case Report

A four-year-old boy was referred to the Department of Pediatric Dentistry at Shahid Beheshti University of Medical Sciences complaining of several unerupted teeth in the mandible. This was reportedly the main cause of his limited mastication. The existing upper teeth were conical in shape and had little or no occlusion. No family history was reported by parents and he was their only child.

Clinical examination revealed classical features of ED, with limited malshaped teeth as shown in Figs. 2 and 3. The teeth present in the maxilla were: 51,61,53,63,55 and 65 and the present mandibular teeth were 73 and 83. Extra-oral examination was conducted on the hair, skin and nails with results indicative of hypohidrosis and hypotrichosis. Hypotrichosis was judged by his poor hair coverage of the head and eyebrows. He also had a distinct and prominent forehead. Further findings were saddle nose, diminished lower facial height, missing eyelashes and eyebrows and protuberant lips (Fig. 1).

As the primary canines were the only set of teeth present in the mandible with a narrow edged posterior ridge, overall underdevelopment of alveolar ridge was evident in its either height or width. The palate was noticed to be shallow while oral epithelium was normal in appearance.

Further radiographic evaluation of the patient revealed similar complications evident on permanent teeth buds in the mandible. Permanent maxillary first molars were traceable in the arch along with four incisors (Fig. 2).

Prosthetic consultation was sought focusing on the potential use of primary mandibular canines as abutments for an over-denture. A comprehensive assessment was performed in order to initiate the treatment phase. The treatment plan consisted of cosmetic correction using composite reshaping technique (Filtek Z250, 3M ESPE, USA) to improve the esthetic appearance of the teeth while filling the gaps. This was a desirable intermediate treatment to fulfill the current needs until he could receive more durable and better fitted porcelain restorations at an older age (Fig. 3).

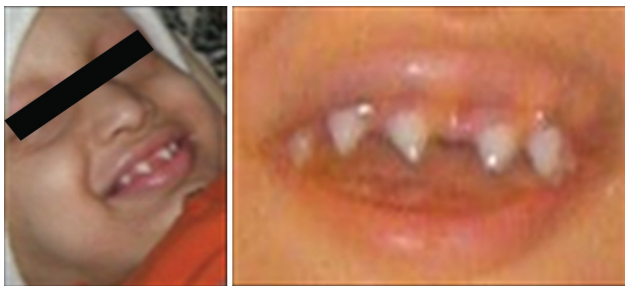


Fig 1. Clinical features of ectodermal dysplasia in the patient.

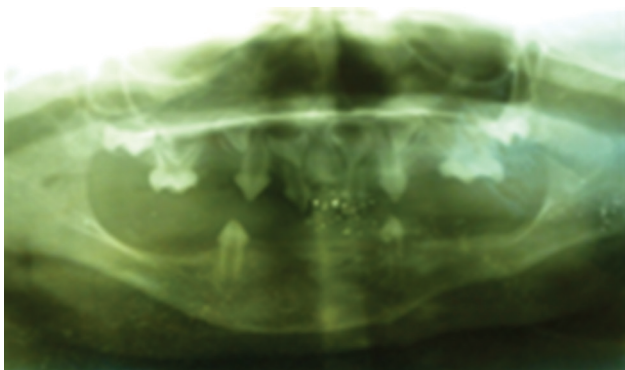


Fig 2. Radiographic features of ectodermal dysplasia in our patient.



Fig 3. Lower denture.

It is mandatory to avoid sophisticated permanent treatment modalities at this age since such children are still in the process of growth and development. Such treatment plans are usually postponed until growth is completed and the maxillofacial components reach a more stable stage.

Since the child's cooperation level was low and his treatment needs were extensive, he was scheduled to receive the

treatment in a single visit under general anesthesia. The patient was, therefore, referred to Mofid Children's Hospital, Tehran and subsequently received full mouth rehabilitation including reshapes and resizes. This was followed by a further step taking impressions of both jaws using Optosil/Xantopran impression materials (Dentsply, Germany) in special trays prepared prior to the treatment session. A conventional partial denture (metal framework) was designed for the missing areas in the mandible while an acrylic partial denture was designed for the maxilla (Fig. 4). Fabricated dentures were delivered and instructed for use in the subsequent visit. The follow up visits were arranged at one week, four weeks, three months and six months in order to evaluate the performance of denture and patient satisfaction. A few areas of discomfort were reported by the child during the first few weeks following limited use of dentures. The patient was encouraged to use dentures frequently and follow the instructions. It appeared that the child's initial acceptance was good to excellent as he used it for eating and public appearance. However, this use was slightly reduced to "only when needed" as reported at the 3- and 6-month follow ups. It was noted that parents had failed to put enough effort to encourage the child for his daily and constant use of dentures. A further 12-month follow up was arranged and more emphasis was placed on the importance of daily use of denture. However, he did not comply. This was when an alternative treatment by use of mini-implants was proposed.

Discussion

Appearance highly depends on the nature and symmetry of smile. Any defect interfering with a beautiful smile could directly influence various aspects of children's social and personal life. Dental appearance is believed to play the greatest role in esthetics among all components of facial esthetics. Patients with ED are visibly affected by such defective appearance and require immediate attention in order to encourage their self-esteem while correcting their occlusion for an improved mastication and speech.⁷ Characteristically, these patients suffer from a thin and underdeveloped ridge covered by a thin layer of mucosa usually topped with a cord of movable connective tissue.⁵ Removable dentures are usually used as the most common dental treatment choice for ED patients.¹⁰ It is routinely recommended to initiate their treatment with a removable, more tolerable denture for children when starting school.¹¹ School-age children are considered old enough to recognize the defective esthetics and feel the need to correct it. In certain cases, when such maturity and cooperation is not achieved, alternative treatment modalities are suggested including dental implants and implant-supported full dentures.¹² It is usually recommended to postpone the use of osseointegrated implants for children until growth is completed. Periodic recalls are essential as growth changes may jeopardize the suitability of denture. Removable partial dentures are often indicated for children and adults with ED.^{13,14} Nonetheless, the use of partial dentures has been described in a 2-year-old ED patient; such early rehabilitation prevents growth abnormalities and improves socialization.¹⁴ The main factors affecting the decision regarding the choice of a removable partial denture or an overdenture are presence of natural posterior teeth, facial esthetics, lip support, number and size of existing natural teeth, and the vertical dimension of occlusion.¹⁵ All changes in the dental arches, including alveolar bone growth in response to tooth eruption, should be considered to ensure appropriate adjustments are

made. Long-term treatment is an active process that must be constantly adjusted according to the child's development and growth.¹⁶ In a study by Pinto et al,¹⁷ after prosthetic rehabilitation, the child experienced a wider variety of foods. The relationship between the upper and lower jaws, esthetics, and self-esteem all improved. Children with such prostheses should perform standard oral hygiene and take care of the devices by themselves. In their study, dental implants were not indicated, because cone beam computed tomography revealed that both maxillary and mandibular micrognathism had occurred as the result of absence of teeth. Cephalometric analysis indicated that the patient had to be followed up to assess bone growth after placement of prosthesis.¹⁷ The authors recommended early prosthetic treatment in patients with this syndrome, especially when the child already has a social life, as is the case with school-age children.

In the present case, initial acceptance, eating and esthetic appearance were very good following delivery of removable

partial denture. But, removable partial denture needs good cooperation of children for use. If the child refuses to wear it full-time, obviously some objectives of treatment would fail, and this point is very important when considering such treatment plans for ED patients.

Conclusion

This case was presented with a desire to improve esthetics which was achieved by reshaping the teeth and replacing the missing ones by denture for better social engagement while improving bite and speech. Communication between physician and parents is the key to success in such cases.

Conflict of Interest

"None Declared." ■

References

1. Lypka M, Yarmand D, Burstein J, Tso V, Yamashita DD. Dental implant reconstruction in a patient with ectodermal dysplasia using multiple bone grafting techniques. *J Oral Maxillofac Surg.* 2008;66:1241–1244.
2. Rouse C, Siegfried E, Breer W, Nahass G. Hair and sweat glands in families with hypohidrotic ectodermal dysplasia: further characterization. *Arch Dermatol.* 2004;140:850–855.
3. Kupietzky K, Milton H. Hypohidrotic ectodermal dysplasia: Prosthetic management of hypohidrotic ectodermal dysplasia. *Quintessence Int.* 1995;26:285–291.
4. Clauss F, Manière MC, Obry F, Waltmann E, Hadj-Rabia S, Bodemer C. Dento-craniofacial phenotypes and underlying molecular mechanisms in hypohidrotic ectodermal dysplasia (HED): a review. *J Dent Res.* 2008;87:1089–1099.
5. Motil KJ, Fete TJ, Fraley JK, Schultz RJ, Foy TM, Ochs U. Growth characteristics of children with ectodermal dysplasia syndromes. *Pediatrics.* 2005;116:e229–e234.
6. Priolo M, Silengo M, Lerone M, Ravazzolo R. Ectodermal dysplasias: not only 'skin/deep. *Clinical genetics. Clin Genet.* 2000;58:415–430.
7. Shigli A, Reddy RV, Hugar SM, Deshpande D. Hypohidrotic ectodermal dysplasia: a unique approach to esthetic and prosthetic management: a case report. *J Indian Soc Pedod Prev Dent.* 2005;23:31–34.
8. Itthagarun A, King NM. Oral rehabilitation of a hypohidrotic ectodermal dysplasia patient: a 6-year follow-up. *Quintessence Int.* 2000;31:642–648.
9. Kaercher T. Ocular symptoms and signs in patients with ectodermal dysplasia syndromes. *Graefes Arch Clin Exp Ophthalmol.* 2004;242:495–500.
10. Till MJ, Marques AP. Ectodermal dysplasia: treatment considerations and case reports. *Northwest Dent.* 1992;71:25–28.
11. Shaw RM. Prosthetic management of hypohidrotic ectodermal dysplasia with anodontia. Case report. *Aust Dent J.* 1990;35:113–116.
12. Lypka M, Yarmand D, Burstein J, Tso V, Yamashita DD. Dental implant reconstruction in a patient with ectodermal dysplasia using multiple bone grafting techniques. *J Oral Maxillofac Surg.* 2008;66:1241–1244.
13. Vasconcelos Carvalho M, Romero Souto de Sousa J, Paiva Correa de Melo F, Fonseca Faro T, Nunes Santos AC, Carvalho S, et al. Hypohidrotic and hidrotic ectodermal dysplasia: a report of two cases. *Dermatol Online J.* 2013;19:18985.
14. Derbanne MA, Sitbon MC, Landru MM, Naveau A. Early prosthetic treatment in children with ectodermal dysplasia. *Eur Arch Paediatr Dent.* 2010;11:301–305.
15. Maroulakos G, Artopoulou I, Angelopoulou MV, Emmanouil D. Removable partial dentures vs overdentures in children with ectodermal dysplasia: two case reports. *Eur Arch Paediatr Dent.* 2016;17:205–210.
16. Dellavia C, Catti F, Sforza C, Tommasi DG, Ferrario VF. Craniofacial growth in ectodermal dysplasia: an 8 year longitudinal evaluation of Italian subjects. *Angle Orthod.* 2010;80:733–739.
17. Pinto AS, Melo Val Alencar C, Costa Oliveira L, Costa de Aquino C, Vasconcelos DF. Prosthetic management of a child with hypohidrotic ectodermal dysplasia: 6-year follow-up. *Case Rep Dent.* 2016;2016:2164340.

How to cite:

Ansari G, Nazemi B, Fayaz A. Dental Management of Ectodermal Dysplasia Syndrome at an Early Age: A Case Report. *J Dent Sch.* 2017;35(3):115–117.