

Titanium implant osseointegration in rheumatoid arthritis patients: Two case reports

Mehran Shokri^a, Jafar Rostamian^a, and Zahra Chegini^a

^aSchool of Dentistry, Shahid Beheshti University of Medical Sciences, Tehran, Iran.

*Correspondance to: Zahra Chegini (e-mail:dr.chegini71@gmail.com).

(Submitted: 30 May 2017– Revised version received: 18 July 2017 – Accepted: 15 August 2017– Published online: Autumn 2017)

Case Implant rehabilitation in patients suffering from rheumatoid arthritis (RA) has been reported an improvement in the quality of life. Implant treatment success depends on many factors like achievement of appropriate osseointegration. There are many controversies about the interactions between anti-rheumatic drugs and osseointegration. Moreover, the scientific evidence regarding implant survival in RA patients are scarce. This study presents two case reports including 65- and 51-year-old women who have used low-dose methotrexate and other anti-rheumatic drugs treated by dental implants. After 4-years follow-up, the patients are satisfied of function and aesthetics. Stable bone level was seen around all implants radiographically. Because of the lack of agreement in implant treatment protocol in RA patient, more studies are suggested.

Keywords implant osseointegration, low-dose methotrexate, rheumatoid arthritis

Introduction

Dental implants are considered as a valuable treatment in restoration of edentulous area. Intraosseous implant success mainly depends on a definition named *osseointegration* that is a constructional and functional connection between the living bone and the implant surfaces.¹ The mechanism of the mentioned phenomenon is similar to the bone remodeling and its repair. *Bone remodeling* described as a dynamic bone resorption process by osteoclasts and new bone formation by osteoblasts.² Therefore, factors which disturb the remodeling and bone repair procedure can end in osseointegration failure.³ Rheumatoid arthritis is a systemic autoimmune disease that can cause hard and soft tissue injuries, pain, swelling, and limited movement of joint are deemed prevalent complications of the problem.⁴ In order to relieve symptoms, patients were obliged to use long-term multiple medications including methotrexate (MTX),⁵ glucocorticoid,^{6,7} sulfasalazine,⁸ nonsteroidal anti-inflammatory drug (NSAID),⁹ Remicade and so forth. Such combination of drugs may interfere with bone repair and osseointegration.³

For instance, several studies have shown bone resorption and reduction new bone synthesis in long-term use of glucocorticoids, while other investigations have revealed evidence which suggests that when osseointegration is obtained, the use of glucocorticoid cannot cause osseointegration failure. Such controversy has also been proposed about NSAIDs and MTX.⁹

There are disagreements regarding the effects of low-dose MTX widely used in rheumatoid arthritis (RA) on bone metabolism. Many studies show the osteopathy resulting from long-term use of this drug, on the other hand, a protective effect on bone metabolism have reported for MTX that prevents bone generalized resorption.^{3,4,10,11}

In fact, it has to be said that there are not much scientific evidences about the survival rate of the implants in patients with rheumatoid arthritis. So a question comes to mind whether RA and anti-rheumatic drugs can be a real contraindication for the implant treatment in these patients?

This study shows a successful 4-years follow-up period of implant loading and osseointegration in two arthritis rheumatoid patients who have used anti-rheumatic drugs for long term. It may be an answer to this question. Certainly, further

studies with large number of patients and implants and longer follow-up can prove the results.

Case One

A fully edentulous 65-year-old woman who has used tissue supported complete denture, but loosed because of the moderate to severe maxillary and mandibular alveolar ridge resorption, referred to our clinic. According to the rheumatologist and internist administration, she has consumed prednisolone (AbuReyhan, Iran) 5 mg daily, MTX (Zahravi, Iran) 2.5 mg twice a week for a period of 14.5 years and two tablets of metformin 500 mg for 12.5 years to control her diabetes. Except of the mentioned information, patient had no other systemic problems.

After consultation with rheumatologist and internist and laboratory tests, she became acceptable for implant treatment which was determined as implant supported over dentures based on bone condition, prosthodontist order, and economic situation of patient. Then, she signed the consent form and a CBCT was taken for the precise positioning of the eight implants in the specified area. Before the surgery, mouth was rinsed with 0.12% chlorhexidine mouthwash (Iran Najo, Iran). Local anesthesia was gained with 2% lidocaine with epinephrine 1:80,000 (Persocaine-E, Darou-Paksh, Iran). Standard mucoperiosteal flaps were reflected and eight Biodenta implants (Biodenta tissue level, Swiss AG) were placed including four implants in the maxilla and four implants in the mandible. The implant sites were prepared by surgical drills with enough irrigation and eight fixtures with 3.7-mm diameter, were placed in ABDE positions. The surgical process was single-stage and wounds were sutured normally with Vicryl 4-0 (Ethicon, Johnson & Johnson, NJ) and removed after 10 days. Amoxicillin 500 mg every 8 h (Farabi, Iran) and Novafen (Acetaminophen 325 mg, caffeine 40 mg, Ibuprofen 200 mg—Alhavi, Iran) for relieving pain were prescribed for 1 week. During the preliminary healing period, the patient is advised to rinse her mouth two times a day with chlorhexidine 0.12% (Iran Najo, Iran).

After 4 months unloading phase, all implants were integrated. Bar and ball attachment were tightened. Finally, overdenture restorations were fabricated and loaded (Fig. 1).

Case Two

A 51-year-old woman suffering from severe RA with a history of total joint replacement in her left knee (TJR: total joint replacement) was referred to our clinic. She missed a number of teeth #2, 3, 18, 19, 29, 30, so came to the hospital to replace them with implants. According to the patient's rheumatologist prescription, she has consumed 5 mg of prednisolone (Nisopred, Iranhormone, Iran) daily and 2.5 mg of MTX (Ebetrex Pharma, Austeria) two times a week for 13 years, sulfasalazine (Iwata, Cadila, India) 500 mg twice a day for 10 years, 5 mg/day Apo-Glyburide (Apotex inc, Canada) and 50 mg Sitagliptin/day (Ziptin, Abidi, Iran) and 500 mg/day Metformin (Glucophage, Actoverco, Iran) daily as anti-diabetes medications and vitamin D3 50000 IU/week (Zahravi, Iran). Furthermore, in the patient's past medical history there was a period of 30 months chemotherapy from 1355 to 1388 and after that, she has used IV infusion of 400 mg Remicade (Behestan darou, Iran) vials every 2 months. She had no any other systemic problem. So she was suggested for implant treatment. Consultation with her rheumatologist, showed that there was no obstacle for implant treatment. She signed a consent form based on the treatment plan agreed by the prosthodontist.

Premedication was performed, mouth rinsed with chlorhexidine 0.12% (Iran Najo, Iran), specified areas were numbed with lidocaine 2% and epinephrine 1/80,000 (Persocaine-E, Darou-Paksh, Iran). Then standard mucoperiosteal flaps were retracted, five Biodenta tapered fixtures (Biodenta, Swiss AG, Switzerland) were installed in the areas of missing teeth #2, 3, 18, 19, 29 in healed bone.

The tooth #31 was removed and in the same appointment, a SIC Bone level fixture (SIC Invent AG, Switzerland) placed in the mesial socket of the extracted tooth. Some allograft (Ceno-Bone DFDDBA, Tissue Regeneration Co., Iran) material was packed around the fixture to fill the gaps. Then, flap was released and $1 \times 1 \text{ cm}^2$ collagen membrane (Cenomembrane, Tissue Regeneration Co., Iran) was placed and the wound was

sutured with cut chromic 4-0 (Supa, Iran). For the first week after surgery, amoxicillin 500 mg every 8 h (Farabi, Iran), Novafen (Acetaminophen 325 mg, caffeine 40 mg, Ibuprofen 200 mg—Alhavi, Iran) for relieve pain were prescribed. During the wound healing phase, the patient rinsed her mouth with chlorhexidine 0.12% (IranNajo, Iran) twice a day.

After 4 months unloading phase, we ensured of osseointegration by performing clinical examination and X-ray observations. In the second-stage healing, caps were tightened. After sufficient healing of the gums and formation of the gingival ring, patient was referred to prosthodontist to start impression and laboratory process. Fixed crowns and bridges were made and loaded. (Fig. 2) After 3 years of loading, a 2–3 mm vertical bone loss was seen just around the upper right first and second molar implants and no other implants, in regular clinical and radiographical examination. Despite this, all implants are still stable and functional.

Discussion

This present study revealed successful osseointegration of dental implants in two RA patients under long-term use of multiple anti-rheumatoid drugs, which are able to interfere with osseointegration.³

A series of chemical mediators, including TNF- α , cytokines (interleukins 1 and 6, etc.)¹² and prostaglandins are the cause of the RA symptoms (joint pain, inflammation, swelling, and stiffness).¹³ To relieve symptoms in these patients, a combination of drugs, such as low dose of MTX, glucocorticoids, sulfasalazine, NSAID, Remicade and ... is prescribed for long time to block the action of chemical mediators.^{13,14}

Methotrexate inhibits purine synthesis that leads to the accumulation of adenosine,^{4,15,16} also prevents T-cell activity. Moreover, it inhibits binding of IL-1 to its receptor on the target cell. In these ways, MTX reveals its anti-inflammatory effects.¹⁷

Remicade (Infliximab) inhibits TNF- α action. Adverse effects of this drug are serious infections like TB, fungal, viral, and

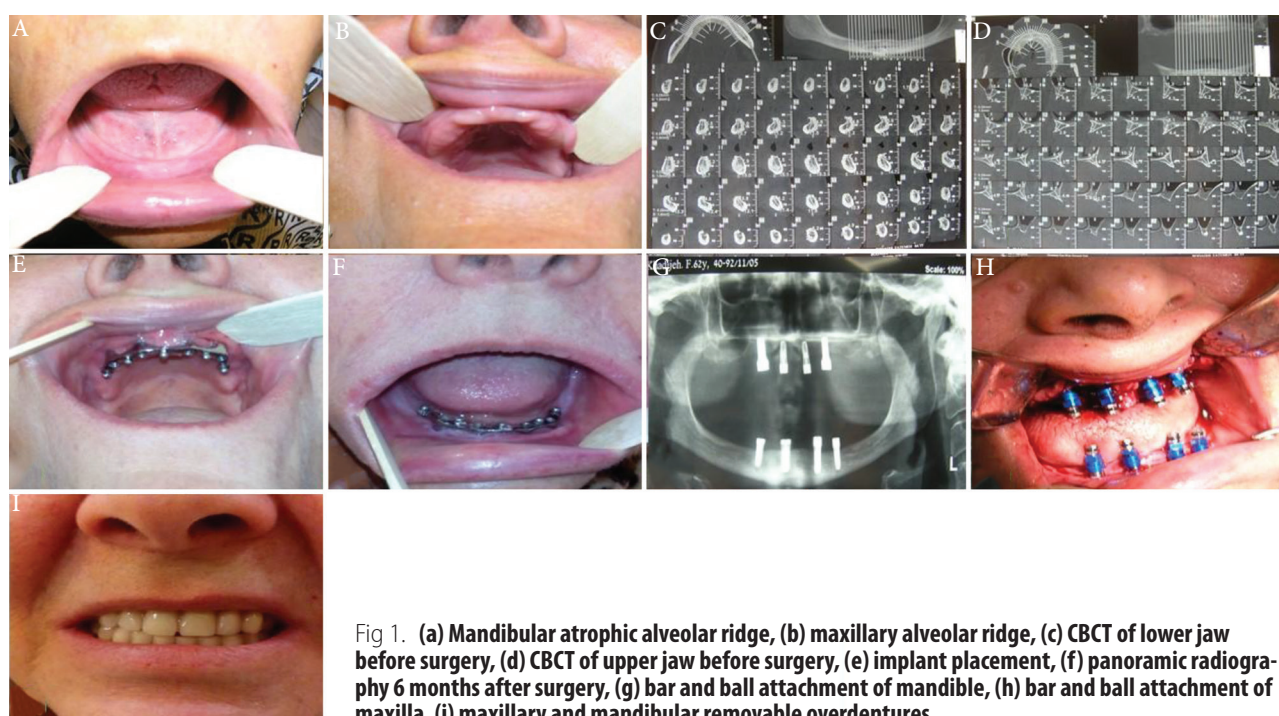


Fig 1. (a) Mandibular atrophic alveolar ridge, (b) maxillary alveolar ridge, (c) CBCT of lower jaw before surgery, (d) CBCT of upper jaw before surgery, (e) implant placement, (f) panoramic radiography 6 months after surgery, (g) bar and ball attachment of mandible, (h) bar and ball attachment of maxilla, (i) maxillary and mandibular removable overdentures.

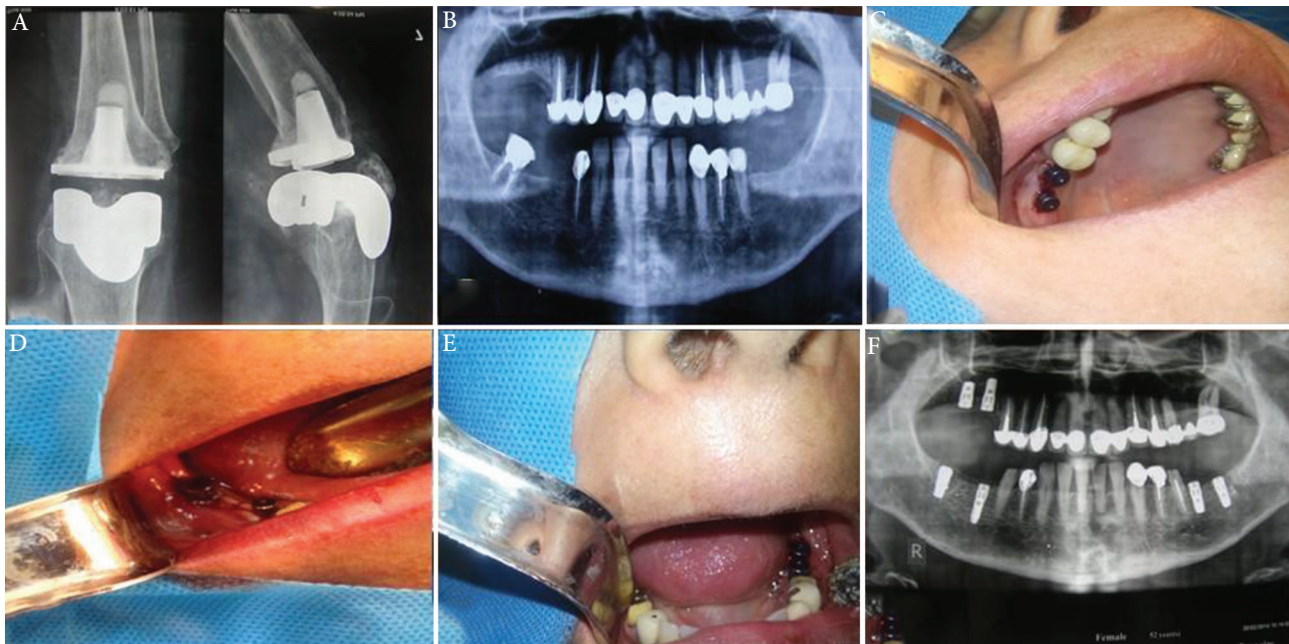


Fig 2. (a) Totally joint replacement (TJR) of the patient's left knee with a prosthesis following severe joint destruction. (b) Preoperative panoramic radiography showing absent teeth. (c) Maxillary fixtures of right first and second molar. (d) Mandibular fixtures in the left first and second molar area. (e) Mandibular fixtures in the right second premolar and second molar area, second molar fixture was installed immediately after the extraction of the tooth. (f) The panoramic radiography 6 months after surgery shows the stability of the fixtures and their osseointegration.

bacterial.¹³Sulfasalazine and NSAID inhibit cyclooxygenase and lipoxygenase enzymes and prevent the synthesis of prostaglandins.^{8,9}It has to be mentioned that there is a controversy about the effects of these drugs on bone metabolism.³ An *in vitro* study which investigated the effects of low dose of MTX on bovine osteoblasts, as an important part of bone remodeling, showed that MTX prohibited the differentiation of osteoblasts. This can have a negative influence on bone healing and osseointegration.⁴ Another study evaluated the effects of low-dose MTX on mice and concluded that long-term use of that resulted in significant osteoporosis by suppression of osteoblasts and stimulation of osteoclasts that led to bone resorption.⁵ Similarly, an article showed osteopenia and reduced bone growth in long-term use of high dose MTX in children. These complications seem to be due to intracellular accumulation of MTX and formation of MTX-polyglutamates in the rapidly growing skeletal structures of infants and children.^{3,18} Some studies have shown that osteopathy caused by low-dose MTX in adult RA patient is not common finding and is limited to a few cases.^{3,19,20} The effects of MTX singly or in combination with glucocorticoids on implants osseointegration installed in the tibia of rabbits was studied and the result showed that bone density around the implants and bone to implants contact area in group who consumed only MTX was not considerable. In contrast in group who used glucocorticoid alone or with MTX had significant reduction on both sites.²¹

Glucocorticoids (GC) are also prescribed to reduce inflammation in RA. Studies have shown that long-term use of GC causes bone loss, which can have a negative effect on osseointegration.^{9,22-28} But several studies indicated that when osseointegration achieved, long-term use of GC does not effect on it.^{9,29} Result of a research on the rabbit's tibia, showed no significant difference in osseointegration between a group that

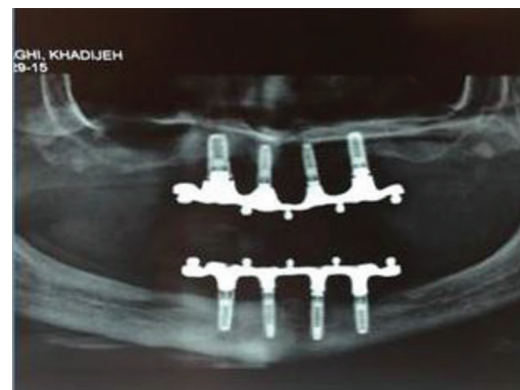

Fig 3. Case one, panoramic radiography, three and a half years after implant loading.

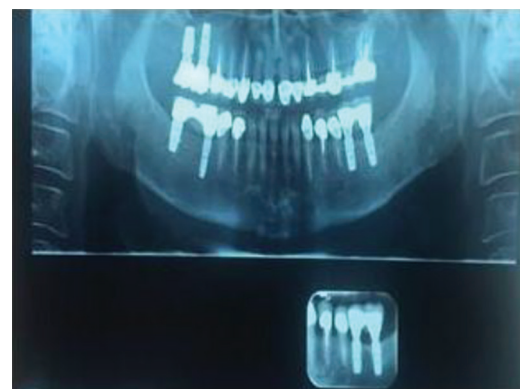

Fig 4. Case two, panoramic radiography, three and a half years after implant loading.

was injected dexamethasone and the control group.^{9,30} Another study examined the effects of steroid administration on the osseointegration of dental implants placed in the rabbit's mandible and they concluded that steroid administration might have less effect on implants osseointegration.^{9,27}

Several studies showed delayed healing of bony fractures when NSAIDs were used.^{9,31,32} A negative effect of Meloxicam on the osseointegration of titanium implants in rats has been recorded.^{9,33} Similarly, *in vivo* studies on a rat tibia model demonstrated that administration of diclofenac delayed healing of peri-implant bone.^{9,34} However, a randomized double-blind control trials demonstrated that oral administration of ibuprofen consumption in the first week after implant surgery, did not have significant effect on bone loss around implants.^{9,35}

Although several studies have clearly recorded a negative effect of anti-rheumatic drugs on bone healing, osseointegration, and implant success, many of these were or animal studies, therefore, cannot be applied to humans. The success of implant treatment has been reported by two studies, the first one is an 80-year-old woman with severe osteoporosis and chronic polyarthritis with 5-year follow-up, and the second one is a 56-year-old woman with RA and long-term use of anti-rheumatic drug and 4-year follow-up.^{36,37} Another study including 34 patients, 25 RA patients and nine patients

suffering from RA and concomitant connective tissue disease (CTD), showed that implant treatment had been successful in RA patient, but in RA + CTD group, some problem such as bone loss, bleeding and pocket were seen around implants.⁴

Our study indicated successful osseointegration implants in two patients with 4-year follow-up that agrees with the above studies. Another strength of our study is that study performed in a human. Of course further human clinical trial studies with more patients and longer follow-up are needed to reinforce our results.

Conclusion

Although it seems the RA medicines are able to interfere with implant osseointegration, there is no serious risk factor for implant osseointegration in RA patient.

Acknowledgment

None.

Conflict of Interest

None Declared ■

References

- Mavrogenis AF, Dimitriou R, Parvizi J, Babis GC. Biology of implant osseointegration. *J Musculoskelet Neuronal Interact*. 2009;9(2):61–71.
- Jaworski ZF. Physiology and pathology of bone remodeling. Cellular basis of bone structure in health and in osteoporosis. *Orthop Clin North Am*. 1981;12:485–512.
- Carvas JB, Pereira RM, Bonfa E, Silveira CA, Lima LL, Caparbo Vde F, et al. No deleterious effect of low dose methotrexate on titanium implant osseointegration in a rabbit model. *Clinics*. 2011;66:1055–1059.
- Annussek T, Kleinheinz J, Thomas S, Joos U, Wermker K. Short time administration of antirheumatic drugs—Methotrexate as a strong inhibitor of osteoblast's proliferation *in vitro*. *Head Face Med*. 2012;8:26.
- May KP, West SG, McDermott MT, Huffer WE. The effect of low-dose methotrexate on bone metabolism and histomorphometry in rats. *Arthritis Rheum*. 1994;37:201–206.
- Boulos P, Ioannidis G, Adachi JD. Glucocorticoid-induced osteoporosis. *Curr Rheum Rep*. 2000;2:53–61.
- Carvas JS, Pereira RM, Caparbo VF, Fuller P, Silveira CA, Lima LA, et al. A single dose of zoledronic acid reverses the deleterious effects of glucocorticoids on titanium implant osseointegration. *Osteoporos Int*. 2010;21:1723–1729.
- Hoult JR, Moore PK. Sulphasalazine is a potent inhibitor of prostaglandin 15-hydroxydehydrogenase: possible basis for therapeutic action in ulcerative colitis. *Brit J Pharmacol*. 1978;64:6–8.
- Ouanounou A, Hassanpour S, Glogauer M. The influence of systemic medications on osseointegration of dental implants. *J Can Dent Assoc*. 2016;82:g7.
- Patel S, Patel G, Johnson D, Ogunremi L, Barron J. Effect of low dose weekly methotrexate on bone mineral density and bone turnover. *Ann Rheum Dis*. 2003;62:186–187.
- Zonneveld IM, Bakker WK, Dijkstra PF, Bos JD, van Soesbergen RM, Dinant HJ. Methotrexate osteopathy in long-term, low-dose methotrexate treatment for psoriasis and rheumatoid arthritis. *Arch Dermatol*. 1996;132:184–187.
- Scott DL, Wolfe F, Huizinga TW. Rheumatoid arthritis. *Lancet*. 2010;376:1094–1108.
- Magyari L, Varszegi D, Kovesi E, Sarlos P, Farago B, Javorhazy A, et al. Interleukins and interleukin receptors in rheumatoid arthritis: Research, diagnostics and clinical implications. *World J Orthoped*. 2014;5:516–536.
- Emery P, Sebba A, Huizinga TW. Biologic and oral disease-modifying antirheumatic drug monotherapy in rheumatoid arthritis. *Ann Rheum Dis*. 2013;72:1897–1904.
- Braun J, Rau R. An update on methotrexate. *Curr Opin Rheumatol*. 2009;21:216–223.
- Hider SL, Bruce IN, Thomson W. The pharmacogenetics of methotrexate. *Rheumatology (Oxford)*. 2007;46:1520–1524.
- Phillips DC, Woollard KJ, Griffiths HR. The anti-inflammatory actions of methotrexate are critically dependent upon the production of reactive oxygen species. *Brit J Pharmacol*. 2003;138:501–511.
- Meister B, Gassner I, Streif W, Dengg K, Fink FM. Methotrexate osteopathy in infants with tumors of the central nervous system. *Med Pediatr Oncol*. 1994;23:493–496.
- van der Bijl AE, Zijlstra TR, Engelage AH, Posthuma BJ, van Veen GJ. [Three patients with a fracture during methotrexate use, possibly due to methotrexate osteopathy]. *Ned Tijdschr Geneesk*. 2008;152:2357–2360.
- Preston SJ, Diamond T, Scott A, Laurent MR. Methotrexate osteopathy in rheumatic disease. *Ann Rheum Dis*. 1993;52:582–585.
- Krennmair G, Seemann R, Piehlsinger E. Dental implants in patients with rheumatoid arthritis: clinical outcome and peri-implant findings. *J Clin Periodontol*. 2010;37:928–936.
- Coutinho AE, Chapman KE. The anti-inflammatory and immunosuppressive effects of glucocorticoids, recent developments and mechanistic insights. *Mol Cell Endocrinol*. 2011;335:2–13.
- Fu JH, Bashutski JD, Al-Hezaimi K, Wang HL. Statins, glucocorticoids, and nonsteroidal anti-inflammatory drugs: Their influence on implant healing. *Implant Dent*. 2012;21:362–367.
- Lane NE, Lukert B. The science and therapy of glucocorticoid-induced bone loss. *Endocrinol Metab Clin North Am*. 1998;27:465–483.
- Smith RA, Berger R, Dodson TB. Risk factors associated with dental implants in healthy and medically compromised patients. *Int J Oral Maxillofac Implants*. 1992;7:367–372.
- Cranin AN. Endosteal implants in a patient with corticosteroid dependence. *J Oral implantol*. 1991;17:414–417.
- Fujimoto T, Niimi A, Sawai T, Ueda M. Effects of steroid-induced osteoporosis on osseointegration of titanium implants. *Int J Oral Maxillofac Implants*. 1998;13:183–189.
- Beumer J, Landesman H, Terry B, Davis W, Davis C. Prosthodontic and surgical aspects of treatment planning for reconstructive surgery. In *Reconstructive Preprothetic Oral and Maxillofacial Surgery*; Saunders: Philadelphia, 1986; pp. 41–60.
- Bencharit S, Reside GJ, Howard-Williams EL. Complex prosthodontic treatment with dental implants for a patient with polymyalgia rheumatica: a clinical report. *Int J Oral Maxillofac Implants*. 2010;25(6):1241–1245.
- Werner SB, Tessler J, Guglielmotti MB, Cabrini RL. Effect of dexamethasone on osseointegration: A preliminary experimental study. *J Oral Implantol*. 1996;22:216–219.

31. Simon AM, Manigrasso MB, O'Connor JP. Cyclo-oxygenase 2 function is essential for bone fracture healing. *J Bone Miner Res.* 2002;17:963–976.
32. Beck A, Krischak G, Sorg T, Augat P, Farker K, Merkel U, et al. Influence of diclofenac (group of nonsteroidal anti-inflammatory drugs) on fracture healing. *Arch Orthop Trauma Surg.* 2003;123:327–332.
33. Ribeiro FV, Nociti FH, Jr., Sallum EA, Casati MZ. Effect of aluminum oxide-blasted implant surface on the bone healing around implants in rats submitted to continuous administration of selective cyclooxygenase-2 inhibitors. *Int J Oral Maxillofac Implants.* 2009;24:226–233.
34. Pablos AB, Ramalho SA, Konig B, Jr., Furuse C, de Araujo VC, Cury PR. Effect of meloxicam and diclofenac sodium on peri-implant bone healing in rats. *J Periodontol.* 2008;79:300–306.
35. Alissa R, Sakka S, Oliver R, Horner K, Esposito M, Worthington HV, et al. Influence of ibuprofen on bone healing around dental implants: a randomised double-blind placebo-controlled clinical study. *Eur J Oral Implantol.* 2009;2:185–199.
36. Ella B, Lasserre JF, Blanchard JP, Fricain JC. A 4-year follow-up of two complete mandibular implant-supported removable prostheses in a patient with severe rheumatoid polyarthritis: case report. *Int J Oral Maxillofac Implants.* 2011;26:e19–e22.
37. Eder A, Watzek G. Treatment of a patient with severe osteoporosis and chronic polyarthritis with fixed implant-supported prosthesis: a case report. *Int J Oral Maxillofac Implants.* 1999;14:587–590.

How to cite:

Shokri M, Rostamian J, Chegini Z. Titanium implant osseointegration in rheumatoid arthritis patients: two case reports. *J Dent Sch* 2017;35(4):150-154.