

Determination of Incisal Point as Anterior Guide to Transfer Maxillary Casts to Articulator: A Pilot Study

Amir Fayaz^a, Mahsa Hemmati^b, Fatemeh Sadat Mirhashemi^c, Yeganeh Memari^d, Ghassem Ansari^e

^a Dept. of Prosthodontics, School of Dentistry, Shahid Beheshti University of Medical Sciences, Tehran, Iran.

^b Dept. of Pediatric Dentistry, Dental School, Kermanshah University of Medical Sciences, Kermanshah, Iran.

^c Dept. Mechanics of Agricultural Engineering, Ferdowsi University of Mashhad, Mashhad, Iran.

^d Dept. of Prosthodontics, School of Dentistry, Shahid Beheshti University of Medical Sciences, Tehran, Iran.

^e Dept. of Pediatric Dentistry, School of Dentistry, Shahid Beheshti University of Medical Sciences, Tehran, Iran.

Correspondence to Ghassem Ansari (e-mail: profgansari@gmail.com).

(Submitted: 27 August 2017– Revised version received: 4 November 2017– Accepted: 18 November 2017– Published online: Winter 2018)

Objectives Despite the importance to use face-bow record for transferring maxillary cast to articulator some dentists use average points to avoid the time taken and ease of use. The location of incisal point could help to set the maxillary cast or denture in an appropriate position in mounting stage. This study was designed to determine the incisal point location in antero-posterior and vertical dimensions in different facial forms and genders.

Methods Dental casts were obtained from the maxillary jaw of 44 dental students (male and female) and subsequently transferred to the articulator using an ear bow. The three dimensional location of the incisal point in relation to condylar axis was determined using a Coordinated Measuring Machine (CMM). Collected data were compared between male and female participants as well as those of oval, squared and tapered faces. For data analysis Student t test was employed to make the comparisons.

Results The mean distance between the incisal point and the center of the condylar axis in antero-posterior and vertical dimensions was 81.28 mm and 42.85 mm respectively. The mean antero-posterior distance was significantly higher among male students ($P < 0.05$). The mean vertical dimensions did not show any significant difference between male and female students ($P > 0.05$). In square facial form, the mean antero-posterior distance was significantly higher compared to the ovoid facial form ($P < 0.05$).

Conclusion The differences on incisal points were significant between the two genders only in antero-posterior dimension. A similar finding was noted on square facial form when compared to ovoid facial form. The incisal point was more consistent with the Frankfurt mounting platform compare to Bonwill index.

Keywords Mounting, Maxillary, cast, Incisal, point, Facial, form

Introduction

Simulation of the jaws relation in articulator is critically important when transferring Maxillary cast to the articulator in order to restore function and aesthetics in prosthodontics.

¹ The use of a face-bow has long been used as the only available tool to transfer maxillary casts to articulators. The significance of reliability in face-bow records is widely accepted for duplication of the position and relationship of the maxillary arch to the temporo- mandibular joints on articulators.² It has been indicated earlier that mounting maxillary cast through the use of a face- bow will eliminate any possible change in vertical dimension and its subsequent effect on inter-arch relationship.³ However, the benefit of face-bow is somehow controversial too, especially in removable prosthesis.⁴⁻⁸ In a systematic review it has been shown that simpler approaches for the construction of complete dentures and occlusal splints may present acceptable results.⁹ Kawai showed that patient's satisfaction was in the same range when denture was produced traditionally or through simplified fabrication methods.¹⁰ It has also been suggested that dental casts can be mounted using mid-positions of articulator.¹¹ Some clinicians have recommended the use of nonadjustable articulators when constructing simple removable partial dentures.¹² Others have suggested arbitrary mountings of

maxillary casts by placement of the occlusal planes in wax occlusion rims on a horizontal plane and parallel to the arms of the articulator.¹³

Despite a wide range of advantages and indications for the use of face-bow recording throughout the literature, some clinician prefer to refer to mean values when mounting maxillary casts, due to its technique sensitivity and time taken¹⁴⁻¹⁵ Earlier reports claim that arbitrary orientations of maxillary casts on articulators may result in very small errors especially when monoplan occlusion issued or when vertical dimension does not have to be changed.¹⁶ Clinical experiences led to a halt in face bow use during complete denture treatments by many clinicians^{13, 17} with little to no significant differences in dentures quality with and without face bow.¹⁸ In a survey it is reported that clearly great majority of prosthodontists hardly used face bow in their daily practice.¹⁴

Therefore mounting maxillary casts without face bow recordings and, only with the aid of average value of their relative positions to the definite reference points/landmarks (one of which is the incisal point), may facilitate the correct simulation of maxillary jaw relationships when transferring dental casts to articulators. Arbitrary orientation requires an average value of maxillary cast positions among each population, especially in antero-posterior and vertical relationships to the inter condylar axis. Some articulators

(Hanau-mate 165-1) include a mounting jig designed according to anatomical landmarks which enables technicians to mount maxillary casts without the use of face bow recordings.¹⁹ In this system, the incisal edges of the maxillary central incisors are aligned on the Bonwill point (9 cm anterior and 3 cm inferior to the condyle center) or the Frankfurt point (8.2 cm anterior and 4.7 cm inferior to the condyle center).¹⁹

In fact, manufacturers design seems somewhat different for arbitrary mounting of maxillary cast in articulator and it is apparent that any errors in recording occlusal relations clinically may lead to functional and aesthetic problems. Therefore, when considering racial variations in terms of skeletal form, occlusal and maxillofacial relations, it is necessary to customize the mean values according to each population. However few facial and dental changes may need to be considered that took place during the years. This pilot study was conducted on dental students aged between 18 to 25 years with completed skeletal growth and stable occlusal plane to determine the approximate incisal point in an Iranian population and their relations with different facial forms and genders. The aim was to see if the location of incisal point in samples is the same as planned point on occlusal table of an articulator.

Materials and Methods

This descriptive cross-sectional study was carried out on 44 dental students (21 males and 23 females). The study was approved by the Institutional Review Board of Shahid Beheshti Dental School. The study subjects were enrolled on a sequential and voluntary basis with informed consent. All participants were fully dentulous, without any marked crowding, spacing and mal-related maxillary central incisors and no history of orthodontic treatments or orthognathic surgeries. To minimize operator confounding factor, maxillary impressions were made for all participants by the same operator using stock metal trays (Jesco-form, Aesculap, Tuttlingen, Germany) and irreversible hydrocolloid (Tropicalgin, Zhermack, BadiaPolesine, Rovigo, Italy). Casts were poured with improved stone plaster (Zhermack, BadiaPolesine, Rovigo, Italy). All procedures were carried out according to the manufacturer's instructions. An ear Face-bow (Dentatus international Ab, Stockholm, Sweden) was used to transfer the maxillary/condylar relationships to the articulators. Silicone indices were prepared from the occlusal surfaces of the maxillary casts using condensable silicone putty impression material (Zetaplus, Zhermack, BadiaPolesine, Rovigo, Italy). The impression material was then placed onto the fork of the face bow. The forks were assembled on the ear face bow and adjusted according to the axis-orbital plane. Each cast was then mounted on a semi-adjustable articulator (Dentatus, ARH International AB, Stockholm, Sweden). The facial forms of each student were determined via the Trubite tooth indicator (Trubite, New York, USA) and classified as square, ovoid or triangular.

To determine the midpoint of incisal curve or incisal point, it was necessary to draw incisal curve arising from incisal edges connection. For this reason two spots marking the mesial and middle points were placed on the incisal edge of both central incisors using a pen with a tip diameter of 0.5 mm. In order to evaluate the three dimensional locations of the points and their relationships to the condylar axis, articulator and mounted casts were transferred to a Coordinate Measuring Machine (C.M.M, Mora, Germany). This machine makes it possible to measure point coordinates on three-dimensional structures with 0.0002 mm precision and speed. The device contains a reference horizontal plane with a stable position which articulator along with mounted maxillary cast was being fixed on to determine the three dimensional positions of two condylar and incisal points. Location of each incisal points and external centers of condylar axis were determined with a touch trigger probe on a three dimensional (X, Y, Z) coordinate (Fig. 1, Fig 2).



Figure 1- Contact of probe of C.M.M to the spots marking the mesial and the middle point on incisors




Figure 2- Contact of probe of C.M.M to the external center of condylar axis.

Data were calculated using a specially designed 3-D remodelling program. Processing was carried out by an expert IT specialist alongside a prosthodontist (operator) on an Autodesk Mechanical Desktop (2007 version, Autodesk, Inc. San Rafael, CA, USA). As there is a slight measuring error in all measuring methods; while three points are needed to create a curve, four on the incisal edges, two on each central incisor, were evaluated to acquire more accuracy. Then four curves made with different combinations of three of the four measuring points on the incisal edges of the central incisors were constructed. The curve that matched closest against the fourth point was

selected (line 3 in fig. 4). Two external centres of each condyle, evaluated by C.M.M, were connected to each other by a line. This line was the condylar axis of the articulator (line 1 in fig. 3).

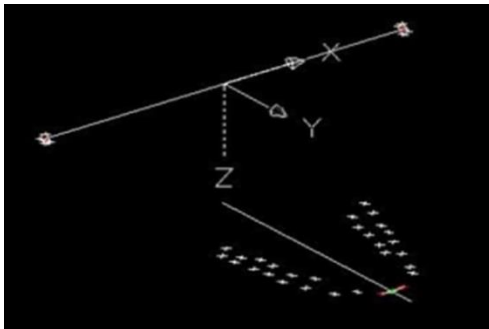


Figure 3- 3-D remodeling of the spots and data processing using Autodesk Mechanical Desktop to estimate the exact coordinate of incisal point.

Then the midpoint of this line was specified. A perpendicular line to condylar axis of the articulator in its midpoint was drawn (line 2 in fig. 3, 4).

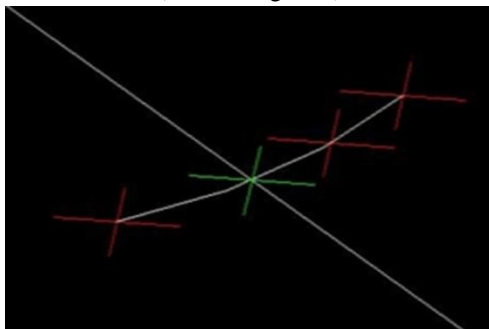


Figure 4- Magnification around maxillary centrals, the red points: the measured points by C.M.M, the green point: the estimated incisal point.

The intersection of perpendicular line with the assumed curve was defined as the incisal point (Fig. 4). All of these procedures were done for each subject to determine the three dimensional position of incisal point to the condylar axis. Data were submitted to SPSS software (version 11.5) and subjected to Student t tests ($\alpha=0.05$) after an initial kolmogorov Smirnov test for normal distribution check.

Results

Of the forty four dental students (age range: 18-25 years, mean: 22) who participated in this study, 48% were male and 52% were female. The percentages of ovoid, square and triangular facial forms were 55, 29 and 16 per cents respectively. It was noted that the average incisal point in samples was more consistent with Frankfurt point. The mean distance between the incisal point and the centre of the condylar axis in antero-posterior and vertical dimensions was 81.28 mm and 42.85 mm respectively. The mean antero-posterior distance was significantly higher among male students ($P=0.03$). The mean vertical dimensions (Table1) did not show any significant difference between male and female students ($P=0.16$). In square facial form, the mean antero-posterior distance was significantly higher compared to the ovoid facial form ($P=0.048$), whereas in the vertical dimension (Table 2), the distance was only slightly higher in square faces ($P=0.61$). Due to the limited number of triangular faces, triangular data were not compared to other groups.

Table 1- location of the incisal point according to gender

	Female (n=23) Mean/ SD	Male (n=21) Mean/ SD	Total (n=44) Mean/ SD	P value
Anterior posterior distance	79.07 (6.55)	83.69 (7.09)	81.28 (1.07)	0.03
Vertical distance	42.04 (3.45)	43.74 (4.51)	42.89 (0.60)	0.16

Table 2- Location of the incisal point according to facial forms

	Square (n=13) Mean/ SD	Ovoid (n=24) Mean/ SD	Total (n=44) Mean/ SD	P value
Anterior posterior distance	84.76 (8.16)	80.03 (5.82)	81.28 (1.07)	0.048
Vertical distance	43.08 (4.21)	42.34 (4.19)	42.85 (0.60)	0.61

Discussion

According to the results of this study, the mean antero-posterior distance between the incisal point and the condylar axis was 81.28 mm which was closer to the Frankfurt (82mm) than Bonwill (90mm) reference point on the mounting jig. In vertical dimension, the mean distance between the incisal point and the condylar axis was 42.85 mm; this was more consistent with the Frankfurt value (47 mm) and Laciello,²⁰ compared to the Bonwill (30 mm) value. It appears that mounting maxillary cast in articulator for included samples, Frankfurt reference point is more

acceptable than Bonwill reference point. The most common reference plane is the Frankfort plane, which has been assumed to be horizontal when the patient is in the natural head position.²¹ The variations between these reference points may be attributed to racial diversities or measuring techniques. Also, significant differences in antero-posterior distances between the incisal point and the condylar axis among genders was observed, this may be due to the differences in skeletal forms and growth potentials in men and women. The result of this study suggests that for male patients, clinicians should consider greater distances in antero-posterior direction when mounting maxillary casts.

In a study the mean distance from an arbitrary transverse horizontal axis to the maxillary central incisal edge position was 100.12 (SD 5.33) mm, but the measurements were down in one plane and a digital caliper (Ultra-Cal Mark III; Sylvac SA) was used for all measurements, however this study showed that distance between the arbitrary transverse horizontal axis and the maxillary central incisal edge was not influenced by the sex.²² To assess the angle between the occlusal and craniofacial planes, Petrivic concluded that no significant differences were found between males and females (as well).²³ Based on the clinical implication of this study, location of incisal points needs to be considered more anterior in mounting maxillary casts of male cases when compared to those in females. In the other hand individuals with square faces, have incisal points in a more advanced position from inter condylar axis than in individuals with ovoid faces. For the tapered faces, due to the low number of participants (2 participants) it was omitted. In fact there are very little studies in recent years in these fields and we need future research to get compelling evidence.

It is worth noting that in this study all subjects were young adults and there may be some changes in skeletal and facial dimensions with age. According to Henrikson arch form changes by age.²⁴ Bishara concluded that in both sexes, reduction of skeletal antero-posterior and vertical dimensions between 26-46 years of age results in a decreased maxillary length.²⁵ Harris concluded that antero-posterior length of dental arches decreased in average about

0.25mm during adulthood.²⁶ Therefore, it may be necessary to consider the age of the patients in determining the position of the incisal points during mounting of casts in older patients. And as mentioned above, it needs to be analyzed on older individuals with sound and intact dentition to get more accurate averages for these reasons. Overall, some of the available international mounting jigs, when used instead of face bow, are not reliable for all populations and need to be customized to meet the characteristics of each population.

Conclusion

It is concluded that:

1. The incisal point in the sample population was more consistent with the Frankfurt mounting platform (jig or occlusal table).
2. The mean distance between incisal point and center of condylar axis in antero-posterior dimension was higher among males than females and was higher in square faces than ovoid faces as well.
3. Considering Racial characteristic and gender are highly essential as well as facial form of the patients in arbitrary mounting maxillary cast.

Conflict of Interests

None Declared ■

References

1. Joffe E. Establishing the horizontal plane for positioning of the plane of occlusion. *N Y State Dent J*. 1993; 59:29-31.
2. Choi DG, Bowley JF, Marx DB, Lee S. Reliability of an ear-bow arbitrary face-bow transfer instrument. *J Prosthet Dent*. 1999 Aug;82(2):150-6.
3. Carr AB, Brown DT. McCracken's Removable partial prosthodontics, 13thEd. St. Louis: Elsevier, 2016; 163-165.
4. Dawson PE. Functional Occlusion from TMJ to Smile Design. St. Louis: Mosby Co, 2007; 235-236.
5. Goska JR, Christensen LV. Comparison of cast positions by using four face-bows. *J Prosthet Dent* 1988; 59:42-4.
6. Palik JF, Nelson DR, White JT. Accuracy of an earpiece face-bow. *J Prosthet Dent* 1985; 53:800-4.
7. O'Malley AM, Milosevic A. Comparison of three facebow/semi-adjustable articulator systems for planning orthognathic surgery. *British J Oral Maxillofac Surg* 2000; 38: 185-90.
8. Gonzales JB, Kingery RH. Evaluation of planes of references for orienting maxillary casts of articulator. *J Am Dent* 1968; 76: 329-36.
9. -Yohn k. The face bow is irrelevant for making prosthesis and planning orthognathic surgery. *J Am Dent Assoc* 2016;147:421-426
10. Farias-Neto A, Dias A.H.M., Miranda B.F.S., Face-bow transfer in prosthodontics: a systematic review of the literature. 2013;40:686-692.
11. Kawai Y, Murakami H, Shariati B, et al. Do traditional techniques produce better conventional complete dentures than simplified techniques? *J Dent* 2005; 33:659-68.
12. dos Santos Junior J, Nelson SJ, Nummikoski P. Geometric analysis of occlusal plane orientation using simulated ear-rod facebow transfer. *J Prosthodont* 1996; 5: 172-81.
13. Phoenix RD, Cagna DR, Defreest CF. Stewart's Clinical Removable Partial prosthodontics, 4thEd. Quintessence Publishing Co Inc., 2008; 371-373.
14. Zarb GA, Bolender CL, Carlsson GE, Boucher CO. Boacher's Prosthodontic Treatments for Edentulous Patients. St. Louis: Mosby, 1997; 327-329.
15. Harrison A, Huggett R, Murphy WM. Complete denture construction in general dental practice: an update of the 1970 survey. *Br Dent J* 1990; 169: 159-163
16. Ellinger CW, Simes GW, Nicol BR, Unger JW, Wesley RC. Patient response to variations in denture technique. Part III: Five-year subjective evaluation. *J Prosthet Dent* 1979; 42: 127-130.
17. Rahn AO, Heartwell CM. Textbook of Complete Dentures, 5thEd. BC Decker Inc Hamilton-London, 2002; 115-118.
18. Wang MQ, Xue F, Chen J, Fu K, Cao Y, Raustia A. Evaluation of the use of and attitudes towards a face-bow in complete denture fabrication: a pilot questionnaire investigation in Chinese prosthodontists. *J Oral Rehabil* 2008; 35: 677-81.
19. Shodadai SP, Turp JC, Gerds T, Strub JR. Is there a benefit of using an arbitrary facebow for the fabrication of a stabilization appliance? *Int J Prosthodont* 2001; 14: 517-22.
20. Lauciello FR, Appelbaum M. Anatomic comparison to arbitrary reference notch on Hanau articulators. *J Prosthet Dent* 1978; 40: 676-81.
21. Raghar D, Kapoor K, Alqahtani AA, Kola MZ, Alqahtani F. Intricate relations and concepts of reference points in prosthodontics: A literature review. *Eur J Prosthodont* 2016;4:1-6
22. Kois JC, Kois DE, Chaiyabutr Y. Occlusal errors generated at the maxillary incisal edge position related to discrepancies in the

Amir fayaz, et al.

- arbitrary horizontal axis location and to the thickness of the interocclusal record. *J Prosthet Dent* 2013;110:414-419
23. Petricevic N, Celebic A, Celic R, Baucic-Bozic M. Natural head position and inclination of craniofacial planes. *Int J Prosthodont* 2006; 19: 279-280.
 24. Henrikson J, Persson M, thilander B. Long-term stability of dental arch form in normal occlusion from 13 to 31 years of age. *Eur J Orthod* 2001; 23:51-61.
 25. Bishara SE, Treder JE, Jacobsen JR. Facial and dental changes in adulthood. *Am J OrthodDentofacOrthop* 1994; 106: 176-186.
 26. Harris EF. A longitudinal study of arch size and form in untreated adults. *Am J OrthodDentofacOrthop* 1997; 111: 419-427.

How to cite:

Amir Fayaz, Mahsa Hemmati, Fatemeh Sadat Mirhashemi, Yeganeh Memari, Ghassem Ansari. Determination of Incisal Point as Anterior Guide to Transfer Maxillary Casts to Articulator: A Pilot Study. *J Dent Sch* 2018; 36(1):7-11.