

Original Article

Corneal Collagen Crosslinking for Treatment of Keratoconus

Milad Abdolahian^{*1}, MSc; Gholamhosein Zolghadr¹, MD

1. Basir Eye Health Research Center, Tehran, Iran.

***Corresponding Author:** Milad Abdolahian

E-mail: opto.zdmu@yahoo.com

Article Notes:

Received: Apr. 30, 2017

Received in revised form:

May. 17, 2017

Accepted: May. 31, 2017

Available Online: Jun. 24, 2017

Abstract

Purpose: The aim of this study was to assess the effects of corneal collagen cross-linking (CXL) on uncorrected visual acuity (UCVA), best corrected visual acuity (BCVA), subjective refraction, corneal irregularity, anterior chamber depth (ACD), corneal thickness, and k-readings.

Keywords:

Cornea

Keratoconus

Collagen Crosslinking

Patients and Methods: Eighty-four eyes of 44 patients with keratoconus were treated using corneal collagen cross-linking. UCVA, BCVA, and subjective refraction were evaluated pre-operatively as well as 3 months and 4 years after treatment and corneal Orbscan results were evaluated preoperatively and 4 years after treatment. Comparisons were made using paired sample t tests and a P values less than 0.05 were considered statistically significant.

Results: There was a significant reduction in the mean thickness of the thinnest point of the cornea from $462.24 \pm 46.95 \mu\text{m}$ preoperatively to $454.36 \pm 55.32 \mu\text{m}$ ($P < 0.05$) at the last follow-up. The mean maximum and mean minimum curvature values reduced significantly from $48.00 \pm 4.02 \text{ D}$ and $45.03 \pm 2.88 \text{ D}$ preoperatively to $47.56 \pm 3.75 \text{ D}$ ($P < 0.05$) and $44.64 \pm 2.94 \text{ D}$ ($P < 0.001$), respectively at the last follow-up. The UCVA ($P = 0.309$), BCVA ($P = 0.594$), subjective spherical equivalent ($P = 0.591$), subjective cylindrical refraction ($P = 0.522$), irregularity at the 3 mm ($P = 0.338$) and 5 mm ($P = 0.915$) zone of the cornea, anterior chamber depth ($P = 0.072$), and central corneal thickness ($P = 0.203$) remained unchanged. There were no significant postoperative complications.

Conclusion: Based on our results, treatment of progressive keratoconus with CXL can effectively stabilize UCVA, BCVA, subjective spherical equivalent, subjective cylindrical refraction, corneal irregularity, central corneal thickness and anterior chamber depth while reducing keratometry readings.

How to cite this article: Abdolahian M, Zolghadr GH. Corneal Collagen Crosslinking for Treatment of Keratoconus. Journal of Ophthalmic and Optometric Sciences. 2017;1(4):8-14.

Introduction

Keratoconus is a noninflammatory cone like ectasia of the cornea, which is usually bilateral and progresses over time¹. Visual impairment typically commences during adolescence and progresses thereafter². Further increase in myopia, irregular astigmatism, and subepithelial scarring results in visual impairment³. Corneal collagen cross-linking (CXL) using UVA and riboflavin was introduced by Wollensak et al.,⁴ as a method of halting the progression of keratoconus. This therapy aims to increase corneal biomechanical stability by inducing additional covalent binding between molecules of collagen. In vitro studies have shown increased corneal rigidity and increased corneal resistance to enzymatic degradation after CXL⁵⁻⁸. In this procedure, the cornea is saturated with iso-osmolar riboflavin solution for 30 min followed by 3 mW/cm² UVA for 30 minutes. The treatment span is 1 h and the cumulative UVA dose is 5.4 J/cm². Clinical studies have reported the efficacy and safety of this new treatment modality in reducing the progression of ectasia in keratoconus patients⁹⁻¹⁴. In the present study, the outcomes of CXL in patients with keratoconus is presented.

Patients and Methods

This study was conducted in accordance with the principles of the Declaration of Helsinki. Prior to their participation, informed consent was obtained from all study participants. Eighty-four eyes of 44 patients (30 male and 54 female) with keratoconus were enrolled in this study. The mean age was 27.13 ± 6.28 (range, 14-43). Patients who had severe central corneal scars and opacities; a history of herpetic keratitis, concurrent corneal infections, concomitant autoimmune diseases, or any ocular surgery; lens or retina abnormalities; and non-cooperative patients were excluded. All procedures were performed in our institute by the same

surgeon under sterile conditions. After topical anesthesia and inserting a wire lid speculum, the photosensitizing solution (0.1 % riboflavin in 20 % dextran) was instilled every 3 min for 30 min. The penetration of riboflavin into the anterior chamber and corneal stroma was confirmed by slit lamp examination. The cornea was then irradiated with UVA for 30 min (radiance of 3 mW/cm²) using a 370 nm UVA double diode light source. During irradiation, the riboflavin solution was applied every 5 minutes. Balanced salts solution was frequently applied intraoperatively to prevent dehydration. The patients were prescribed topical antibiotics for 5 days along with tear substitutes for 3-4 weeks. Preoperative and postoperative evaluation after 3 months and then 4 years consisted of uncorrected visual acuity (UCVA), best corrected visual acuity (BCVA), subjective refraction, slit lamp, and fundus examinations. Corneal topography (Orbscan IIz; Bausch & Lomb, Rochester, NY) was performed preoperatively and then 4 years after CXL. Statistical evaluation of values before as well as 3 months and 4 years after CXL was performed using SPSS software version 20 (Armonk, NY: IBM Corp). The normality of the data was tested using the Kolmogorov-Smirnov test. Depending on the data distribution, paired t tests or Wilcoxon's paired test was used to check the differences. The level of statistical significance was set at $P < 0.05$. The study was approved by the ethics committee of the Basir Eye Health Research Center, Tehran, Iran.

Results

Visual Acuity and Refraction Results

The preoperative and postoperative data are presented in table 1. No statistically significant differences were observed in UCVA or BCVA at 3 months and 4 years post treatment

compared to the preoperative values (UCVA; $P = 0.371$, $P = 0.309$, BCVA; $P = 0.136$, $P=0.594$, respectively). Similarly, the change in spherical equivalent and cylindrical refraction was not significant at 3 months and 4 years after CXL (subjective SE; $P = 0.279$, $P = 0.591$, subjective CYL; $P = 0.423$, $P = 0.522$, respectively).

Topographic Results

There was a significant decrease in the mean thickness of the thinnest point of the cornea from $462.24 \pm 46.95 \mu\text{m}$ preoperatively to $454.36 \pm 55.32 \mu\text{m}$ ($P < 0.05$) at the last follow-up. The mean maximum and mean

minimum curvature values decreased significantly from $48.00 \pm 4.02 \text{ D}$ and $45.03 \pm 2.88 \text{ D}$ preoperatively to $47.56 \pm 3.75 \text{ D}$ ($P < 0.05$) and $44.64 \pm 2.94 \text{ D}$ ($P < 0.001$), respectively at the last follow-up. Figure 1 shows changes of K-readings after corneal CXL. No statistically significant difference was detected in the central corneal thickness ($P = 0.203$), anterior chamber depth ($P=0.072$), irregularity at the 3mm ($P = 0.338$) and 5mm ($P = 0.915$) zones of the cornea, at the last follow-up compared to the preoperative values. Figure 2 shows changes of corneal thickness.

Table 1: Patients’ visual acuity before and after treatment

Parameters (mean ± SD)	Preoperative	3 months postoperative	4 years postoperative
UCVA		0.33 ± 0.22	0.32 ± 0.23
P value		$P = 0.371$	$P = 0.309$
BCVA		0.70 ± 0.22	0.80 ± 0.18
P value		$P = 0.136$	$P = 0.593$
SUB SE	3.08	$- 4.11 \pm 3.96$	$- 3.69 \pm 3.15$
P value		$P = 0.279$	$P = 0.591$
SUB AST	$- 2.37 \pm 1.49$	$- 2.66 \pm 1.54$	$- 2.34 \pm 1.49$
		$P = 0.423$	$P = 0.522$

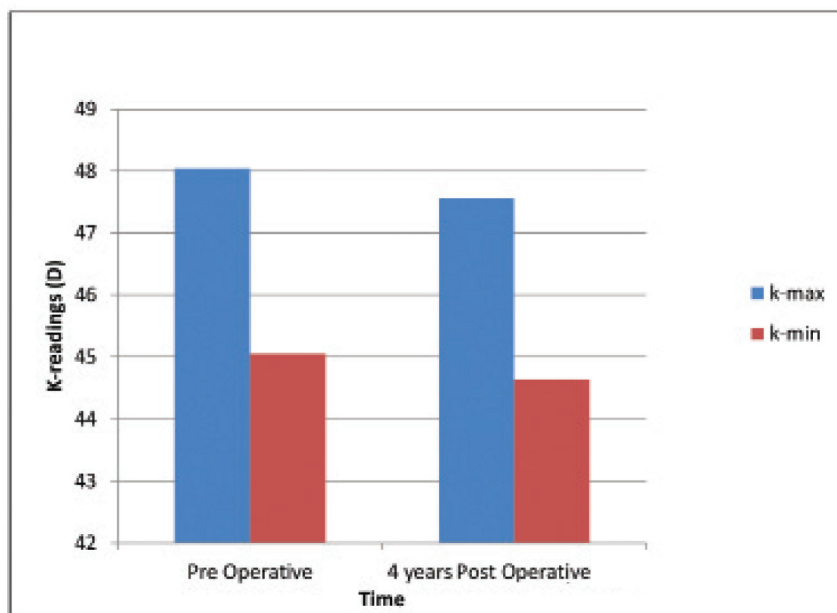


Figure1: Change in K-readings (D) after CXL

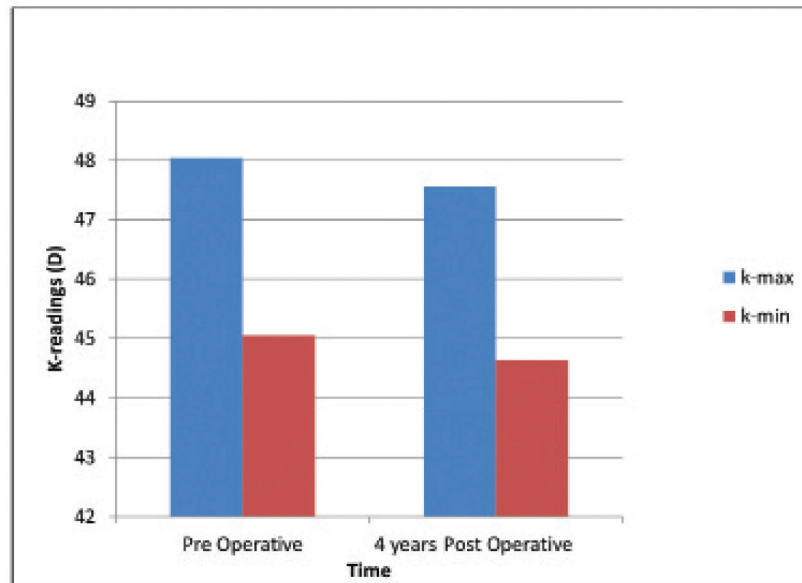


Figure 2: Change in corneal thickness (μm) after CXL

Discussion

Corneal CXL is a minimally invasive and relatively inexpensive treatment protocol that can halt keratoconus with high success rates even over the long-term. It flattens the cornea and in some cases, increases the visual acuity¹⁵. This study investigated the effect of CXL on UCVA, BCVA, and topographical values. After 4 years of follow-up, the study demonstrated that treating cases of progressive keratoconus with CXL can stabilize UCVA, BCVA, subjective spherical equivalent, subjective cylindrical refraction, central corneal thickness, anterior chamber depth and irregularity at the 3 mm and 5mm zones of the cornea in the long term. The observed changes after CXL included reduced thinnest point of the cornea, as well as a significant decrease in maximum and minimum curvature values.

Visual Acuity and Refraction Results

Changes in visual outcome were carefully documented over time because a comprehensive understanding of visual responses in postoperative time course will greatly help physicians

in setting realistic patient expectations after CXL. In this study, UCVA and BCVA showed no change. Our results show that 75 % of patients had improved or unchanged UCVA, 70.23 % had Improved or unchanged BCVA, whereas 25 % lost lines of UCVA and 29.77 % lost lines of BCVA at the last follow-up. Other short and long-term studies have reported significant continuous improvement in visual Caporossi et al.,¹⁶ have reported Significant improvement in both UCVA and BCVA after 6 months,¹⁶ 1 year,¹⁷ and 2 years,¹⁸ of follow up has been previously reported. Also after 1 year of follow-up, Grewal et al.,¹⁹ reported stable BCVA.

Topographic Results

The present study demonstrated a decrease of 0.44 ± 1.39 D in max-K and 0.39 ± 0.88 D in min-K at the last follow-up 4 years after CXL. This is similar to previous published results. Wollensak et al.,²⁰ reported a decrease in the maximum keratometry readings by 2.01 D. Derakhshan et al.,²¹ demonstrated that the maximum and mean K values decreased by

0.65 D and 0.51 D respectively. Raiskup-Wolf et al.,²² reported reduced curvature of 2.68 D in the first year, 2.21 D in the second year, and 4.84 D in the third year.

In the current study, changes in corneal thickness were evaluated after the CXL treatment. There was a significant reduction in the mean thickness of the thinnest point of cornea and no statistically significant difference was detected in the central corneal thickness. Thus far, the effect of CXL on corneal thickness has been less clear. Thinning immediately after CXL has been reported and is thought to be the result of several factors, including treatment-related effects from stromal compaction, postoperative dehydration, and alterations in epithelial healing and distribution^{23,24}. It also may represent a measurement artefact after treatment²⁵. Longer-term observations vary from no change in corneal thickness¹⁶ to a decrease at 12 months¹⁸ and an increase at 24 months²². The present study showed no statistically significant difference in anterior chamber depth at the last follow-up compared to the preoperative values. Polat et al.,²⁶ reported that the preoperative ACD values were significantly lower than the postoperative values. Emre et al.,²⁷ studied 216 previously untreated keratoconus patients and found that the ACD showed a significant increase with increasing keratoconus stage, and

that this increase could be as a result of anterior protrusion of the cornea. They found that the ACA showed a significant decrease and stated that this could be due to the compensatory flattening of the peripheral cornea. Abolbashari et al.,²⁸ reported a correlation between corneal curvatures and anterior segment parameters in keratoconus patients with peripheral ACD, usually being related to the anterior corneal curvature. Toprak and Yildirim²⁹ evaluated 47 keratoconic eyes during a 6-month period following CXL. They reported no significant change in ACD values. Another study conducted by De Bernardo et al.,¹¹ reported that there was no change in ACD values. They argued that the stability of the ACD was associated with the increase in axial length (AL). New studies measuring the pre and post-CXL iris-lens diaphragm positions and changes can better clarify this subject.

Conclusion

Based on our results, treatment of progressive keratoconus with CXL can effectively stabilize UCVA, BCVA, subjective spherical equivalent, subjective cylindrical refraction, corneal irregularity, central corneal thickness and anterior chamber depth while reducing keratometry readings.

References

1. Krachmer JH, Feder RS, Belin MW. Keratoconus and related noninflammatory corneal thinning disorders. *Surv Ophthalmol.* 1984;28(4):293-322.
2. Rabinowitz YS. Keratoconus. *Surv Ophthalmol.* 1998;42(4):297-319.
3. Davis LJ, Schechtman KB, Wilson BS, Rosenstiel CE, Riley CH, Libassi DP, et al. Longitudinal changes in visual acuity in keratoconus. *Invest Ophthalmol Vis Sci.* 2006;47(2):489-500.
4. Mohammadpour M, Masoumi A, Mirghorbani M, Shahraki K, Hashemi H. Updates on corneal collagen cross-linking: Indications, techniques and clinical outcomes. *J Curr Ophthalmol.* 2017;29(4):235-47.
5. Kohlhaas M, Spoerl E, Schilde T, Unger G, Wittig C, Pillunat LE. Biomechanical evidence of the distribution of cross-links in corneas treated with riboflavin and ultraviolet A light. *J Cataract Refract Surg.* 2006;32(2):279-83.
6. Wollensak G, Spoerl E, Seiler T. Stress-strain measurements of human and porcine corneas after riboflavin-ultraviolet-A-induced cross-linking. *J Cataract Refract Surg.* 2003;29(9):1780-5.
7. Dupps WJ Jr, Netto MV, Herekar S, Krueger RR. Surface wave elastometry of the cornea in porcine and human donor eyes. *J Refract Surg.* 2007;23(1):66-75.
8. Spoerl E, Wollensak G, Seiler T. Increased resistance of crosslinked cornea against enzymatic digestion. *Curr Eye Res.* 2004;29(1):35-40.
9. Wollensak G. Corneal collagen crosslinking: new horizons. *Expert Rev Ophthalmol.* 2010; 5:201-15.
10. Sadoughi MM, Feizi S, Delfazayebaher S, Baradaran-Rafii A, Einollahi B, Shahabi C. Corneal Changes After Collagen Crosslinking for Keratoconus Using Dual Scheimpflug Imaging. *J Ophthalmic Vis Res.* 2015;10(4):358-63.
11. De Bernardo M, Capasso L, Lanza M, Tortori A, Iaccarino S, Cennamo M, Long-term results of corneal collagen crosslinking for progressive keratoconus. *J Optom.* 2015;8(3):180-6.
12. O'Brart DP, Kwong TQ, Patel P, McDonald RJ, O'Brart NA. Long-term follow-up of riboflavin/ultraviolet A (370 nm) corneal collagen cross-linking to halt the progression of keratoconus. *Br J Ophthalmol.* 2013;97(4):433-7.
13. Hersh PS, Stulting RD, Muller D, Durrie DS, Rajpal RK; U.S. Crosslinking Study Group. U.S. Multi-center Clinical Trial of Corneal Collagen Crosslinking for Treatment of Corneal Ectasia after Refractive Surgery. *Ophthalmology.* 2017;124(10):1475-84.
14. Li G, Fan ZJ, Peng XJ. Corneal collagen crosslinking for corneal ectasia of post-LASIK: one-year results. *Int J Ophthalmol.* 2012;5(2):190-5.
15. Raiskup F, Theuring A, Pillunat LE, Spoerl E. Corneal collagen crosslinking with riboflavin and ultraviolet-A light in progressive keratoconus: ten-year results. *J Cataract Refract Surg.* 2015;41(1):41-6.
16. Caporossi A, Baiocchi S, Mazzotta C, Traversi C, Caporossi T. Parasurgical therapy for keratoconus by riboflavin-ultraviolet type A rays induced cross-linking of corneal collagen: preliminary refractive results in an Italian study. *J Cataract Refract Surg.* 2006;32(5):837-45.
17. Wittig-Silva C, Whiting M, Lamoureux E, Lindsay RG, Sullivan LJ, Snibson GR. A randomized controlled trial of corneal collagen cross-linking in progressive keratoconus: preliminary results. *J Refract Surg.* 2008;24(7):S720-5.
18. Vinciguerra P, Albè E, Trazza S, Seiler T, Epstein D. Intraoperative and postoperative effects of corneal collagen cross-linking on progressive keratoconus. *Arch Ophthalmol.* 2009;127(10):1258-65.
19. Grewal DS, Brar GS, Jain R, Sood V, Singla M, Grewal SP. Corneal collagen crosslinking using riboflavin and ultraviolet-A light for keratoconus: one-year analysis using Scheimpflug imaging. *J Cataract Refract Surg.* 2009;35(3):425-32.
20. Wollensak G, Spoerl E, Seiler T. Riboflavin/ultraviolet-a-induced collagen crosslinking for the treatment of keratoconus. *Am J Ophthalmol.* 2003;135(5):620-7.5.
21. Derakhshan A, Shandiz JH, Ahadi M, Daneshvar R, Esmaily H. Short-term Outcomes of Collagen Crosslinking for Early Keratoconus. *J Ophthalmic Vis Res.* 2011;6(3):155-9.



22. Raiskup-Wolf F, Hoyer A, Spoerl E, Pillunat LE. Collagen crosslinking with riboflavin and ultraviolet-A light in keratoconus: long-term results. *J Cataract Refract Surg.* 2008;34(5):796-801.
23. Greenstein SA, Shah VP, Fry KL, Hersh PS. Corneal thickness changes after corneal collagen crosslinking for keratoconus and corneaectasia: one-year results. *J Cataract Refract Surg.* 2011;37(4):691-700.
24. Kontadakis GA, Ginis H, Karyotakis N, Pennos A, Pentari I, Kymionis GD, et al. In vitro effect of corneal collagen cross-linking on corneal hydration properties and stiffness. *Graefes Arch Clin Exp Ophthalmol.* 2013;251(2):543-7.
25. Mazzotta C, Caporossi T, Denaro R, Bovone C, Sparano C, Paradiso A, et al. Morphological and functional correlations in riboflavin UV A corneal collagen cross-linking for keratoconus. *Acta Ophthalmol.* 2012;90(3):259-65.
26. Polat N, Gunduz A, Colak C. The influence of corneal collagen cross-linking on anterior chamber in keratoconus. *Indian J Ophthalmol.* 2017;65(4):271-5.
27. Emre S, Doganay S, Yologlu S. Evaluation of anterior segment parameters in keratoconic eyes measured with the Pentacam system. *J Cataract Refract Surg.* 2007;33(10):1708-12.
28. Abolbashari F, Mohidin N, Ahmadi Hosseini SM, Mohd Ali B, Retnasabapathy S. Anterior segment characteristics of keratoconus eyes in a sample of Asian population. *Cont Lens Anterior Eye.* 2013;36(4):191-5.
29. Toprak I, Yildirim C. Scheimpflug parameters after corneal collagen crosslinking for keratoconus. *Eur J Ophthalmol.* 2013;23(6):793-8.

Footnotes and Financial Disclosures

Conflict of Interest:

The authors declare no conflict of interest with the subject matter of the present manuscript.