



Diode Laser Excision of Oral Benign Lesions

Ena Mathur^{1*}, Mohit Sareen², Payal Dhaka², Pallavi Baghla²

¹Department of Oral Medicine and Radiology, Rajasthan Dental College, Jaipur, Rajasthan, India

²Senior Lecturer, Department of Oral Medicine and Radiology, Rajasthan Dental College, Jaipur, Rajasthan, India

Correspondence to

Ena Mathur, DDS; Department of Oral Medicine and Radiology, Rajasthan Dental College, Jaipur, Rajasthan, India.
Tel: +55-9414272301;
Email: enamathur@gmail.com

Published online 28 June 2015



Abstract

Introduction: Lasers have made tremendous progress in the field of dentistry and have turned out to be crucial in oral surgery as collateral approach for soft tissue surgery. This rapid progress can be attributed to the fact that lasers allow efficient execution of soft tissue procedures with excellent hemostasis and field visibility. When matched to scalpel, electrocautery or high frequency devices, lasers offer maximum postoperative patient comfort.

Methods: Four patients agreed to undergo surgical removal of benign lesions of the oral cavity. 810 nm diode lasers were used in continuous wave mode for excisional biopsy. The specimens were sent for histopathological examination and patients were assessed on intraoperative and postoperative complications.

Results: Diode laser surgery was rapid, bloodless and well accepted by patients and led to complete resolution of the lesions. The excised specimen proved adequate for histopathological examination. Hemostasis was achieved immediately after the procedure with minimal postoperative problems, discomfort and scarring.

Conclusion: We conclude that diode lasers are rapidly becoming the standard of care in contemporary dental practice and can be employed in procedures requiring excisional biopsy of oral soft tissue lesions with minimal problems in histopathological diagnosis.

Keywords: Diode laser; Biopsy; Soft tissue

Introduction

Lasers have made tremendous progress in the field of dentistry and have turned out to be crucial in oral surgery as collateral approach for soft tissue surgery. This rapid progress can be attributed to the fact that lasers allow efficient execution of soft tissue procedures with excellent hemostasis and field visibility. When matched to scalpel, electrocautery or high frequency devices, lasers offer maximum postoperative patient comfort.¹

Diode lasers have a variety of applications in the dentistry. It is a solid state semiconductor laser associated with aluminium, gallium and arsenic. They have a wavelength of 800-980 nm in the range of invisible near infrared light. Beams can be emitted in continuous or pulsed mode.² This laser has high absorption in tissues pigmented with hemoglobin, melanin and collagen chromophores and low absorption in dental hard tissues. As a result it can be used for surgery of oral soft tissue lesions in close proximity to dental structures which do not involve disproportionate bleeding.²

The diode laser is a portable and compact surgical unit, with ease of operation and is less expensive when compared to hard tissue laser equipment.³

The present paper discusses the use of diode laser as a vital tool in excision of benign soft tissue lesions of oral cavity with histological findings.

Case Reports

Soft tissue excisional biopsies were performed with different power settings in continuous mode using contact (focused) handpiece with a 810 nm diode laser. We used Picasso dental diode laser from AMD lasers with an integrated gallium-aluminum-arsenide (GaAlAs) semiconductor and 400 µm diameter glass fiber as a delivery system (Picasso by AMD lasers, LLC). Manufacturer states laser equipment as a class II B device. The surgical procedures were carried out under topical or local anesthesia and all specimens were sent for histopathological examination. All clinical cases were evaluated in the following sequence - first 3 days, 1 week, 2 weeks and 4 weeks post-operatively. Safety glasses were worn by the patient, the surgeon and the assisting staff all through surgery.

The wounds in the oral mucosa were not sutured and healing was facilitated by granulation and secondary epithelialization. Topical anesthetic ointments and antimicrobial mouthwash were prescribed to all patients to shield the wound initially and prevent any secondary infection.

Case 1

A male patient aged 50 years presented with a nontender, pedunculated, fibrous oval tumor arising from the palatal mucosa measuring about 3 cm × 1.5 cm in size. The tumor was excised under local anesthesia using power

output of 1.4 W in continuous mode. The tip was directed at an angle of 10 to 15 degrees to the tissue; and was applied continuously in contact mode. Histopathological examination diagnosed it as pyogenic granuloma. No bleeding, swelling or scar tissue formation was observed (Figures 1-3).

Case 2

A male patient aged 55 years reported with 2 nontender, pedunculated, firm and smooth tumors on lower labial mucosa with underlying oral submucous fibrosis. Excisional biopsy was done under local anesthesia with 2 W power settings in contact mode. Histopathological diagnosis was inflammatory fibrous hyperplasia (Figures 4-6).

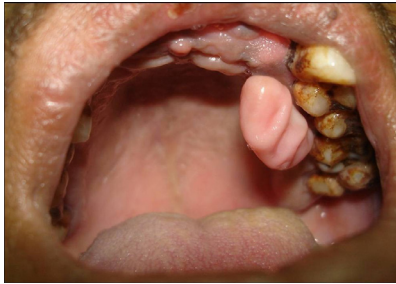

Figure 1. Chronic Irritational Fibroma on Palate.

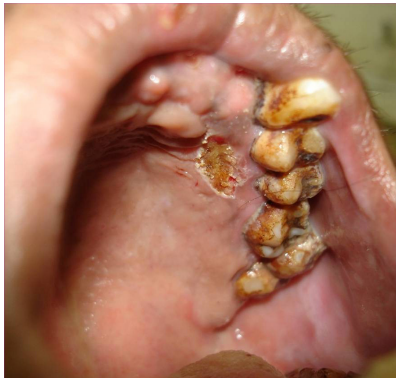

Figure 2. Immediate Postoperative With no Bleeding.

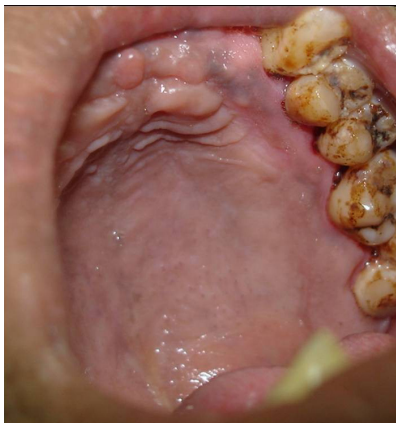

Figure 3. Desirable Wound Healing With no Scar Tissue Formation.

Case 3

A male patient aged 29 years presented with a nontender, pedunculated, exophytic papillomatous nodule with numerous blunt finger like projections. Excisional biopsy was done under local anesthesia with 0.7 watt power setting. Histopathological diagnosis was squamous papilloma (Figures 7-9).

Case 4

A 32 year old patient in her third trimester presented with a tender, soft pedunculated lesion in relation to 41 and 42 with profuse bleeding on probing. Excisional biopsy was done under local anesthesia with 0.8 W power setting. Histopathological diagnosis was pyogenic granuloma. No sutures or postoperative medication was required. Optimum healing with minimal pain and discomfort was noted (Figures 10-12).

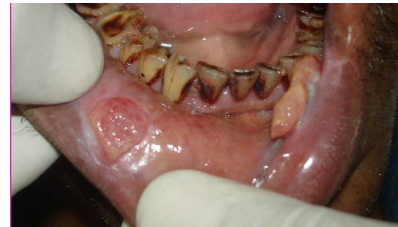

Figure 4. Traumatic Fibromas on Lower Labial Mucosa.

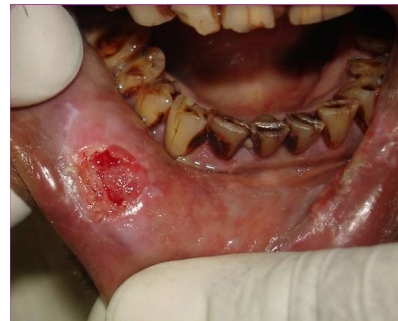

Figure 5. Immediate Postoperative With no Bleeding.

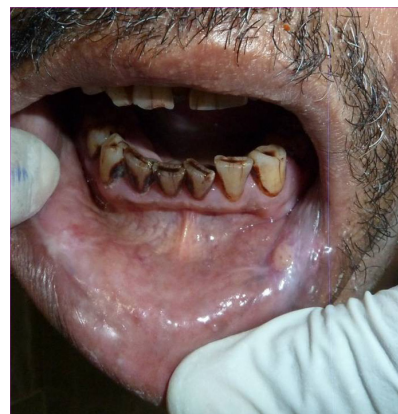


Figure 6. Complete Wound Healing 1 Month Postoperative.

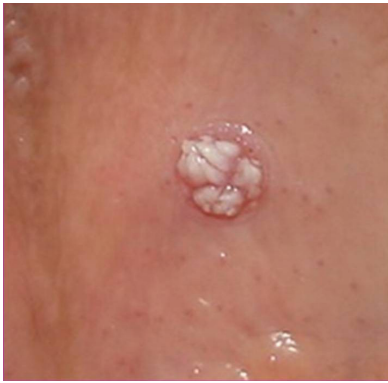


Figure 7. Papilloma on Hard Palate.

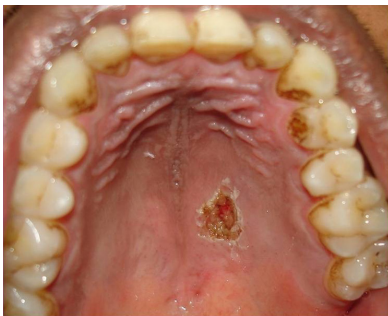

Figure 8. Immediate Postoperative With no Bleeding.

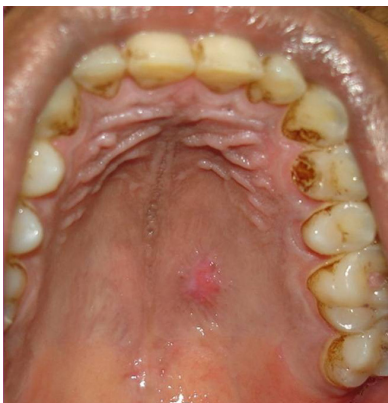

Figure 9. Two Weeks Postoperative Demonstrating Adequate Healing.

Discussion

This paper presents our elemental clinical experience from the use of diode laser for the purpose of excisional biopsies. The benefits of laser surgery include hemostasis and outstanding field visibility, precision, superior injection control and exclusion of bacteremia, reduced mechanical tissue trauma, minimal postoperative pain and edema, negligible scarring and tissue shrinkage, microsurgical capabilities, and fewer instruments at the site of operation.^{4,5} The hemostatic nature of the laser is of immense value in excising exophytic lesion. It can be used to arrest bleeding in the field by its ability to contract vascular wall collagen.⁶ This allows extremely good visibility and precision when

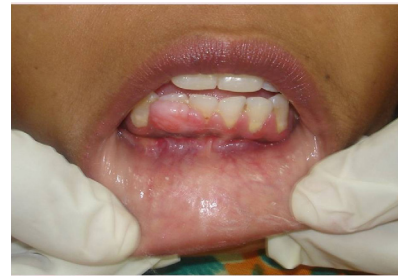

Figure 10. Pyogenic Granuloma in Relation to 41, 42.

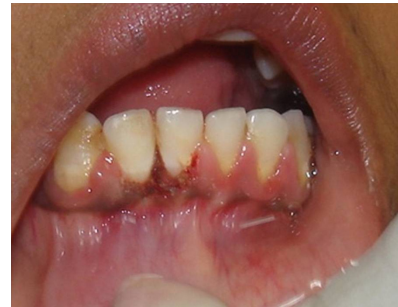

Figure 11. Immediate Postoperative With Minimal Bleeding.

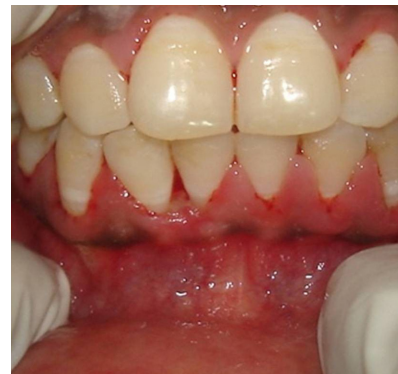

Figure 12. Complete Wound Healing Without Scar Formation.

dissecting through the tissue planes.

The outstanding tissue coagulation by diode laser is of immense clinical importance. Because of no bleeding at the site of surgery, suturing was not necessary, the surgical period was markedly minimized and patients were protected from potential high-risk infection. The denatured proteins from the tissue and plasma give rise to a surface which shields the surgical wound from frictional and bacterial action.⁷

Koppolu et al⁸ compared the excision of lesions with diode laser and scalpel and concluded that for intraoral soft tissue surgical techniques, laser is a reasonable alternate to the scalpel. Diminished postoperative swelling and pain is a distinctive quality of lasers and facilitates improved safety when performing surgery within the airway.

Studies evaluating the thermal tissue effects of diode lasers are not decisive. In an experimental study, histological analysis to confirm vertical and horizontal tissue damage as well as incision depth and width was performed in the oral mucosa using 810 nm diode laser.⁹ The authors concluded that the outstanding cutting ability and the tolerable damage zone visibly showed the diode laser to be very efficient and a valuable option in soft tissue surgery in oral cavity.

Angiero et al¹⁰ concluded that diode laser is a convincing therapeutic device for excising oral lesion larger than 3 mm in diameter, but can cause serious thermal effects in small lesions. They suggested that specimens should be of at least 5 mm in diameter in order to have a dependable evaluation of the histological sample. This was achieved in our cases where specimen size was above 3 mm which enabled the pathologist to provide an accurate histological diagnosis.¹¹

When compared to healing after scalpel surgery healing from laser surgery is usually outstanding with negligible scarring and amplified function; nevertheless, the rate of healing is usually lengthened. This delay in healing can be attributed to the sealing of blood vessels and lymphatics. Usual intraoral healing takes 2 to 3 weeks for wounds that would normally take 7 to 10 days.^{5,12}

Bryant et al¹³ evaluated wound healing of oral soft tissues after diode laser irradiation and stated that their clinical application in oral surgical procedures has favorable effects.

Jin et al³ stated that the diode laser is a fine cutting tool for oral mucosa; however, more tissue damage occurs than with the use of scalpel or an erbium, chromium doped yttrium scandium gallium garnet (Er-Cr:YSGG) laser.

Conclusion

Diode laser should be successfully used in oral surgical procedures for achieving adequate hemostasis, disinfection of surgical site, reducing risk of postoperative infection and significantly diminishing postoperative pain. We conclude that diode lasers are rapidly becoming the standard of care in contemporary dental practice and can be used for excisional biopsies of oral soft tissue lesions with minimal problems in histopathological diagnosis.

References

- Coluzzi DJ. Fundamentals of dental lasers: Science and Instruments. *Dent Clin Am.* 2004;48:751-770.
- Gontijo I, Navarro RS, Haypek P, Ciamponi AL, Haddad AE. The applications of diode and Er:YAG lasers in labial frenectomy in infant patients. *J Dent Child (Chic).* 2005;72(1):10-15.
- Jin JY, Lee SH, Yoon HJ. A comparative study of wound healing following incision with a scalpel, diode laser or Er,Cr:YSGG laser in guinea pig oral mucosa: A histological and immunohistochemical analysis. *Acta Odontol Scand.* 2010;68(4):232.
- Muller JG, Berlein P, Scholz C. The medical laser. Medical laser application. 2006; 21 (2): 99-108
- Strauss RA, Zeltser R, Sela M, et al. The use of lasers in dentistry: principles of operation and clinical applications. *Compend Contin Educ Dent.* 2003;24(12): 935-948.
- Panduric DG, Bago I, Zore IF, et al. Application of diode laser in oral and maxillofacial surgery. In: Motamedi MH, ed. *A Textbook of Advanced Oral and Maxillofacial Surgery.* InTech; 2013.
- Pedron IG, Muller Ramalho K, Artioli Moreira L, Moreira de Freitas P. Association of two lasers in the treatment of traumatic fibroma: excision with Nd: YAP laser and photobiomodulation using InGaAlP: a case report. *J Oral Laser Appl.* 2009;9:49-53.
- Koppolu P, Mishra A, Kalakonda B, Swapna LM, Bagalkoikar A, Macha D. Fibroepithelial polyp excision with laser and scalpel: A comparative evaluation. *Int J Curr Microbiol App Sci.* 2014;3(8):1057-1062.
- Goharkhay K, Moritz A, Wilder-Smith P, et al. Effects on oral soft tissue produced by a diode laser in vitro. *Lasers Surg Med.* 1999;25(5):401-406. doi:10.1002/(sici)1096-9101(1999)25:5%3C401::aid-lsm6%3E3.0.co;2-u.
- Angiero F, Parma L, Crippa R, Benedicenti S. Diode laser (808nm) applied to oral soft tissue lesions: a retrospective study to assess histopathological diagnosis and evaluate physical damage. *Lasers Med Sci.* 2012;27(2):383-388. doi:10.1007/s10103-011-0900-7.
- Suter VG, Altermatt HJ, Sendi P, Mettraux G, Bornstein MM. CO2 and diode laser for excisional biopsies of oral mucosal lesions. A pilot study evaluating clinical and histopathological parameters. *Schweiz Monatsschr Zahnmed.* 2010;120(8):664-671.
- Strauss RA. Lasers in oral and maxillofacial surgery. *Dent Clin North Am.* 2000;44(4):851-873.
- Bryant GL, Davidson JM, Ossoff RH, Garrett CG, Reinisch L. Histologic study of oral mucosa wound healing: a comparison of a 6.0- to 6.8-micrometer pulsed laser and a carbon dioxide laser. *Laryngoscope.* 1998;108 (1 pt 1):13-17. doi:10.1097/00005537-199801000-00003.