

# REVIEW ARTICLE

## Ullrich Congenital Muscular Dystrophy

How to Cite this Article: Haliloglu G, Topaloglu H. Ullrich Congenital Muscular Dystrophy. Iranian Journal of Child Neurology 2011;5(3): 1-13.

**Goknur HALILOGLU MD<sup>1</sup>,  
Haluk TOPALOGLU MD<sup>2</sup>**

### Abstract

#### Objective

Ullrich congenital muscular dystrophy is a rather severe type of congenital muscular dystrophy with early onset features related to motor development. In general it is inherited in autosomal recessive principles, however in the Western world mostly seen with de novo dominant mutations in the collagen VI genes. Milder form of the condition is the Bethlem myopathy. There may be overlap forms in the clinic resembling the Ehler-Danlos syndrome. There has been some radical efforts for cure especially through the apoptosis cascades.

**Keywords:** Ullrich congenital muscular dystrophy, collagen VI genes, Bethlem myopathy, autophagy.

### Introduction

#### Historical note and nomenclature

In 1930, Ullrich described a peculiar form of congenital muscular dystrophy (CMD) with an unusual combination of distal hyperextensibility and proximal contractures in two boys under the name of “congenital atonic-sclerotic muscular dystrophy” (1,2). Additional clinical findings were onset in the neonatal period or early infancy, generalized muscle weakness, hyperhydrosis, high-arched palate, protruded calcanei and normal intelligence. Other CMD patients with a similar clinical presentation confirmed the existence of this condition which was named “Ullrich disease”. Ullrich phenotype is now classified as a nosologically distinct group within the congenital muscular dystrophies, as a subtype of merosin-positive congenital muscular dystrophy (1,2). Ullrich congenital muscular dystrophy, UCMD; Mendelian Inheritance in Man (MIM) 254090 and Bethlem myopathy, BM; MIM 158810, were originally described as separate entities but demonstration of collagen VI gene mutations led to the concept of ‘collagen VI-related myopathies’ as a group of conditions covering a broad clinical spectrum (3).

#### Clinical manifestations

The signature clinical feature of the Ullrich congenital muscular dystrophy phenotype is congenital muscle weakness with proximal joint contractures and coexisting marked distal joint hyperlaxity. 100th ENMC International Workshop diagnostic criteria for Ullrich CMD due to primary collagen type VI involvement are summarized in Table 1 (4, 5).

Hypotonia, congenital hip dislocation, congenital torticollis, contractures, arthrogryposis and distal laxity may be the neonatal findings. Notably most of the

1. Professor of Pediatric Neurology, Hacettepe Children's Hospital, Ankara, Turkey
2. Professor of Pediatric Neurology, Department of Child Neurology, Ankara, Turkey

Corresponding Author:  
Topaloglu H. MD  
Hacettepe University Children's Hospital 06100 Ankara, Turkey  
Tel: +90 312 467 51 61  
Fax: +90 312 305 27 73  
Email: htopalog@hacettepe.edu.tr

Received: 13-May- 2011  
Last Revised: 22 -Aug-2011  
Accepted: 24 -Agu-2011

patients have delayed motor milestones and generalized slowly progressive muscle weakness including mild facial weakness and high-arched palate. Contractures of proximal joints, particularly elbows and knees are frequently present from birth. Distal joints of hands, ankles, toes and finger joints are hyperextensible lifelong. During the early follow-up most contractures release spontaneously and some return over the years, particularly involving elbows, knees and spinal joints. Patients usually have dry skin and protruded bulbs of hair follicles giving the appearance of dermatitis. There

may be excessive cheloid formation at the sites of muscle biopsy. Protruded calcaneus and thickening of the subcutaneous tissue on the soles of the feet may be the additional key features. There is absence of severe mental retardation. Cases of variable severity have been described; the most severe end of the disease is the sclerotic form with severe contractures and rigidity of the spine (6)(Fig.1). Although the patients at the severe end of the spectrum never achieve independent walking, there are also patients with a more benign presentation who can walk independently.

**Table1.** Diagnostic criteria for Ullrich CMD due to primary collagen type VI involvement

- Autosomal recessive inheritance
- Neonatal features may include hypotonia, hip dislocation, contractures and distal laxity
- Delayed motor milestones
- Generalized slowly progressive muscle weakness including mild facial muscles and high-arched palate
- Distal laxity (hand, foot, and finger)
- Contracture of proximal joints: torticollis, limited neck flexion, and kyphoscoliosis
- Protruded calcaneus
- A proportion of patients who never achieved the ability to walk
- Early respiratory failure
- No central nervous system involvement with normal intelligence
- Serum CK: normal or mildly elevated
- Muscle pathology varies from myopathic to dystrophic, with fiber size variation, interstitial fibrosis and may include necrotic and regenerating process
- Collagen VI staining: complete to partial deficiency
- The diagnosis can be confirmed by COL6 genes mutations

## Etiology

This is a collagen VI related disorder. In a series of 15 patients (5), 11 had muscle biopsy samples for collagen VI immunostaining and 5 had a marked reduction, 1 had a mild reduction and 5 had normal expression, whereas linkage analysis in 6 families linked with COL6A1, COL6A2 and COL6A3. As a result primary collagen VI involvement was 40% (6/15). According to our experience including 24 patients from 21 families, primary collagen VI involvement with muscle biopsy and /or genetic studies is 70% (7). The role of collagen VI is excluded in the remaining patients with Ullrich phenotype, indicating genetic heterogeneity. Further

analysis of tissue samples of this group is necessary for collagen VI expression. In most of the patients, there is variable deficiency of collagen VI at the basal lamina with an apparently preserved expression in the interstitial connective tissue, whereas a minority of the patients show complete deficiency in the protein (8).

## Pathogenesis and Pathophysiology

Collagen type VI is a ubiquitous connective tissue component, present primarily in the stroma and also close to the basement membrane of most tissues (9,10). It is a glycoprotein that consists of three separate chains,

the 1, 2 and 3 collagen chains, encoded by the COL6A1, COL6A2 (11), and COL6A3 genes, respectively. The 1 and 2 collagen chains are similar in size (140kDa) and their genes are linked in a head-to-tail orientation on chromosome 21q22.3 (8). The 3 collagen chain is much larger (260-330 kDa) and is encoded by the gene located on chromosome 2q37 (8). The three chains share the same core structure: a relatively short triple helical domain of 335-336 aminoacids with repeating Gly-Xaa-Yaa aminoacid sequences flanked by globular domains made up of motifs of 200 aminoacids each that are homologous to von Willebrand factor type A domains (12,13,14). The three chains fold into triple-helical monomers, which are then assembled in an antiparallel manner into dimers with the N-terminal globular domains protruding (12,15). The dimers associate laterally into tetramers, which are subsequently secreted into the extracellular space and associate, end-to-end, into double-beaded collagen VI microfibrils that are characterized by a band of periodicity of 100 nm. Collagen type VI is distributed in the connective tissues and is particularly abundant around cells, associated with interstitial collagen fibres types I-III, with a possible role as substrate for the attachment of cells and in anchoring collagen fibres, nerves and blood vessels to the surrounding connective tissue (16,1).

Collagen VI genes were first found to be associated with Bethlem myopathy indicating tissue-specific importance of collagen VI (17) identified compound heterozygosity in the COL6A2 gene and complete deficiency of collagen VI by immunohistochemistry in the muscle biopsy. Expression of collagen IV, a major component of the basal lamina was normal. Electron microscopy showed a total absence of microfibrils, which are usually seen in the interstitium associated with collagen fibrils. The authors suggested that loss of anchoring between the basal lamina and the interstitium may be the molecular mechanism of muscular dystrophy. Collagen VI mutations in UCMD reported to date are extremely heterogeneous. It was known that recessive mutations in COL6A2 and COL6A3 genes result in Ullrich CMD (17, 18, 19, 20, 21) whereas dominant mutations in all three collagen genes have been associated with Bethlem myopathy (OMIM # 158810) (21, 22, 23), a milder childhood-onset disorder characterized by muscle

weakness and later manifesting multiple joint contractures (24, 25). In three families, a form of autosomal dominant limb girdle muscular dystrophy has also been attributed to heterozygous mutations in the COL6A1 and COL6A2 genes (26). All of the COL6A2 mutations described in UCMD so far lead to translational frameshifts and subsequent premature stop codons (17, 18, 19). In two of these patients with UCMD, the COL6A2 mRNA has been shown to be nearly absent because of nonsense-mediated mRNA decay (27). Nonsense-mediated mRNA (NMD) decay is briefly an mRNA quality-control mechanism that degrades aberrant mRNAs containing premature translation termination codons. In a recent study the effects of NMD inhibition on the phenotype of Ullrich disease is evaluated (28). The patient studied showed a homozygous frameshift mutation with a premature translation termination codon in the collagen VI 2 gene, which encodes a truncated but partially functional protein. Fibroblast culture showed nearly complete loss of the triple-helical collagen VI protein and functional defects in the extracellular matrix. Knockdown of essential proteins for NMD causes the up-regulation of the mutant triple-helical collagen VI, resulting in the formation of partially functional extracellular matrix. The authors suggest also that inhibition of NMD may be a therapeutic approach (28, 29). Of the three COL6A3 homozygous mutations in UCMD, two are nonsense mutations-one in the N-terminal globular domain and one in the triple-helical domain-and third one leads to skipping of an exon encoding the triple-helical domain (20). The patients with COL6A3 gene mutations exhibited complete or partial deficiency of collagen VI protein in the muscle. All of the mutations defined so far are documented in a recent review (30). In two patients, one with a classical severe phenotype of UCMD and the other with distal joint hyperlaxity in the absence of contractures who carry de novo heterozygous in-frame deletions of different sizes and locations in the triple-helical domain of the COL6A1 mRNA were defined (23). This provides a biochemical and immunohistochemical evidence for a genotype/phenotype correlation and show that the severe UCMD phenotype can arise from a heterozygous mutation in collagen VI through a dominant negative mechanism. With this

challenge, additional patients from different groups were reported with dominant collagen VI mutations. Three of the five patients with a clinical diagnosis of Ullrich CMD had heterozygous in-frame deletion in N terminal region of the triple helical domain. Protein biosynthesis and assembly studies showed that these mutations act in a dominant negative fashion and result in severe collagen VI matrix deficiencies. These findings also show that dominant mutations are common in Ullrich CMD (11, 30, 31, 32). Biosynthetic consequences of the mutations depend on their positions in the triple-helical domain (33, 34). It is not clear what molecule anchors the collagen VI network to the basement membrane. Possible candidates are collagen type IV, perlecan and fibronectin which are present in the basement membrane and interact with collagen VI in vitro (35). These results all indicate a critical role of collagen VI in the muscle basement membrane and suggest that mislocalization of collagen VI is a potential mechanism for the severe UCMD phenotype. Pace et al studied effects of collagen VI glycine mutations on spectrum of clinical severity. Eight newly diagnosed patients with different clinical severity were screened for three collagen VI messenger RNA for mutations, collagen VI biosynthesis and assembly pathway (36). All of the patients had heterozygous glycine mutations toward the N-terminal end of the triple helix. There were two assembly phenotypes. In the first group collagen VI dimers accumulated in the cell but not the medium, microfibril formation in the medium was moderately reduced and amount of collagen VI in the extracellular matrix was not significantly altered. In the second group, a more severe assembly defect leads to reduced collagen VI in the extracellular matrix due to impaired microfibril formation in the medium due to defective disulfide bonding of the secreted collagen VI tetramers (36). This study demonstrated that collagen VI glycine mutations impair the assembly pathway in different ways and disease severity correlates with the assembly abnormality (36, 37). Further evidence showed that exon skipping mutations in Collagen VI are common and are predictive for severity and inheritance (38). Location of the skipped exon relative to the molecular structure of the collagen chain strongly correlates with the clinical phenotype. As a general conclusion, de novo dominant mutations in severe

UCMD occur relatively frequently in all three collagen VI chains and severity of the phenotype depends on the ability of mutant chains to be incorporated in the multimeric structure of collagen VI (38). Autosomal recessive inheritance of classic Bethlem myopathy have also been reported (39, 40). Either recessive or dominant mutations causing both Ullrich CMD and Bethlem myopathy have relevant implications for genetic counseling and genotype-phenotype correlations in collagen VI-related myopathies(25). As a summary, two mutational mechanisms are known to underlie UCMD: heterozygous dominant negatively-acting mutations and recessively-acting loss-of-function mutations. Large genomic deletions are described for the first time in two families with UCMD (41). Authors report in detail that, this type of a mutation will not be detected by single-exon amplification and sequencing (unless done quantitatively) and a hemizygous change detected on a nondeleted allele will appear homozygous, and obscure the true genotype of the patient's disease. on the other hand, clinically unaffected parents carrying large genomic deletions of COL6A1 and COL6A2 also provide evidence that haploinsufficiency for COL6A1 and COL6A2 is not a disease mechanism for Bethlem myopathy (41). These results have great translational importance and therapeutic strategies directed at the elimination of a dominant negatively-acting mutation are conceivable and would create a functional state of haploinsufficiency. There are still patients with UCMD phenotype and normal collagen VI expression on the muscle biopsy and/or not linked to known collagen VI loci indicating genetic heterogeneity of this condition (5, 7). Clinical and morphological phenotype of 15 Ullrich CMD patients from 11 consanguineous families showing potential linkage either to 21 q22.3 (6 families) or to 2q37 (5 families) was evaluated. The clinical phenotype of the patients with complete collagen VI deficiency in muscle or cultured fibroblasts was severe compared to the partial deficiencies with a milder presentation. There was no significant phenotypical difference between the families linked to each of the 2 loci. The authors suggest that there may be a correlation between clinical severity and degree of collagen VI deficiency (42). Genotype-phenotype correlation is reported for the first time in a study including five Ullrich CMD patients. It is

demonstrated that heterozygous glycine substitutions in the triple helix domain of COL6A1 are dominant and results in a milder phenotype whereas recessive mutations result in more severe clinical and biochemical phenotypes (43). In an Ullrich CMD patient on the severe end of the spectrum, reverse-transcription-PCR analysis of fibroblast RNA suggested a heterozygous in frame deletion of exon 13 in the triple helical domain of COL6A2. This dominantly acting mutation activated numerous cryptic splice acceptor sites and generated normal and exon-13 deleted COL6A2 mRNA, and multiple aberrant transcripts containing frameshifts that were degraded through a nonsense-mediated decay. Decreased mRNA expression was defined as the primary pathogenic mechanism in this unique patient (44). The algorithm of molecular work-up clearly shows that complete analysis is essential to make genotype-phenotype correlations. Pepe, et al identified highly similar heterozygous COL6A1 genomic deletions in two patients with UCMD and the milder Bethlem myopathy. The 5' breakpoints of both deletions are located within a minisatellite in intron 8 (45,32). The mutations cause in-frame deletions in the amino-terminus of the triple-helical domain. Although the biosynthetic consequences of the mutations are similar, there are differences in the clinical presentations of the patients due to modifying factors. The authors demonstrate the presence of a minisatellite in COL6A1 intron 8 predisposing the defined area to multiexon deletions in collagen VI-related muscular dystrophies. Genomic DNA analysis and short-range RT-PCR may underestimate the multiexon deletions so long distance RT-PCR and protein analyses are necessary for the accurate molecular diagnosis (32). Genetic and clinical correlations in early onset collagen VI myopathies (UCMD, Bethlem myopathy and intermediate phenotypes) have been reported recently, in a multicenter study (46). The authors characterized, at the clinical, cellular and molecular levels, 49 patients with onset in the first 2 years of life. Patients were classified into 3 groups: early severe (18%), moderate-progressive (53%), and mild (29%). In this study, ColVI secretion was analyzed in skin fibroblasts. Chain-specific transcript levels were quantified by quantitative reverse transcriptase polymerase chain reaction, and mutation analysis was

performed by sequencing of complementary DNA. As a result, ColVI secretion was altered in all fibroblast cultures studied and 56 mutations mostly novel and private were detected. Dominant de novo mutations constituted 61% of cases and mutations causing premature termination codons (PTCs) or in-frame insertions strikingly destabilized the corresponding transcripts. Homozygous PTC-causing mutations in the triple helix domains led to the most severe phenotypes (ambulation never achieved) and dominant de novo in-frame exon skipping and glycine missense mutations were identified in patients of the moderate-progressive group (loss of ambulation). Quantitative RT-PCR is defined as a helpful tool for identification of some mutations (46). As a whole, patients with a phenotype consistent with Ullrich CMD constitute the largest group of patients with merosin-positive congenital muscular dystrophy. Since direct molecular analysis of the COL6 genes is complex, a reliable test at the protein level is required to guide molecular analysis. In a recent study from the Hammersmith's group, it is documented that immunohistochemical analysis of skin biopsies may not always reveal an underlying collagen VI defect and analysis of collagen VI synthesis and deposition in skin fibroblast cultures is a useful technique (47). Collagen VI expression is analyzed in 14 patients with Ullrich CMD, and analysis of collagen VI in fibroblast cultures from eight of these patients showed reduced extracellular deposition in all cases and intracellular collagen VI staining in seven cases. Collagen VI immunolabelling was reduced in all the available muscle biopsies (n=7). Collagen VI status was also evaluated from the skin (n=10) and fibroblast cultures (n=8) and even in patients with normal collagen VI expression in skin (n=5), collagen VI was reduced in the extracellular matrix with varying degrees of intracellular labeling. There was no correlation between the extent of the reduction in the muscle and fibroblast cultures, the mode of inheritance and the severity of the clinical phenotype. Recently, the role of confocal microscopy and rotary-shadowing electron microscopy (REM) is reported to be useful to identify a secondary collagen VI defect (48). In a patient with Ullrich CMD, the authors described mildly reduced collagen VI immunolabeling around myofibers and significantly decreased collagen IV-VI co-localization in



basal lamina and several capillaries despite normal collagen VI staining in the muscle biopsy. The characteristic abnormality with selective reduction of collagen VI microfilaments at the level of the reticular lamina of the basal membrane reinforces the idea that other proteins closely interacting with collagen VI may be also implicated in the pathogenesis. By these means, extensive morphological analysis by confocal imaging and REM may be useful methods to predict Ullrich CMD patients with secondary collagen VI defects. Selective depletion of collagen VI in the muscle basal lamina compared to normal levels in the endomysium is not clear. Collagen microfibrils near the surface of muscle cells are reduced in patients with UCMD (17,49), and interactions of collagen VI near the cell surface may be more sensitive to structural changes and/or less stable than the interactions with extracellular matrix proteins leading to mislocalization of collagen VI. Collagen VI turnover is regulated by signaling through integrins and as an additional mechanism impaired binding between mutated collagen and VI and integrins may alter collagen composition of the basement membrane and endomysial connective tissue (50). Synthesis, formation and binding of collagen VI to the extracellular matrix was studied from fibroblast samples with p.G284R mutation in COL6A1 and showed decreased binding of collagen VI microfibrils to extracellular matrix resulting in sarcolemma-specific collagen VI deficiency (51). Secretion and assembly of type IV and VI collagens is demonstrated to depend on glycosylation of hydroxylysines which are shown to be indispensable for the formation of basement membranes (52). Skin abnormalities, including predisposition to keratosis pilaris and abnormal scarring were described in UCMD and Bethlem myopathy patients. COL6A5, previously designated as COL29A1 was linked to atopic dermatitis. To gain insight into the function of these two new chains, the authors studied expression of the collagen VI  $\alpha 5$  and  $\alpha 6$  chains in normal human skin and skin of patients with collagen VI-related myopathies. They showed that localization of  $\alpha 5$  and to a lesser extent  $\alpha 6$  is restricted to the papillary dermis, where the protein mainly colocalizes with collagen fibrils (53). In UCMD patients with COL6A1 and COL6A2 mutations, immunolabeling for  $\alpha 5$  and  $\alpha 6$  was often altered, whereas in a UCMD and

Bethlem myopathy patient with COL6A3 mutation, expression was unaffected, suggesting that these chains may substitute for  $\alpha 3$ , while forming heterotrimers. A dystrophic mouse model where collagen VI synthesis was prevented by genetic ablation of the Col6a1 gene allowed investigation of pathogenesis, which revealed the existence of a calcium-mediated dysfunction of mitochondria and the sarcoplasmic reticulum (54). Critical point appears to be inappropriate opening of the mitochondrial permeability transition pore (PTP), an inner membrane high conductance channel. Studies from fibroblasts of patients with UCMD and Bethlem myopathy showed the existence of a latent mitochondrial dysfunction irrespective of the genetic background (55). PTP opening seems to be final common pathway for skeletal muscle fiber death (56). On the other hand, mitochondrial ultrastructural alterations are observed in many forms of muscle pathology; myofibers with mitochondrial-sarcoplasmic reticulum alterations display nuclear features of apoptosis, and whether these findings are cause or consequence should be evaluated with caution. Defective activation of the autophagic machinery is described to be pathogenic first, in the skeletal muscles of collagen VI-knockout mice, and than muscle biopsies from subjects with Bethlem myopathy or UCMD (57). Persistence of abnormal organelles and apoptosis are caused by defective autophagy.

## Epidemiology

There is no epidemiological study in our population, but to our experience about 20% of our patients with merosin positive congenital muscular dystrophy have UCMD phenotype. A detailed population study of patients with genetic muscle disease in northern region of England, including over 1100 patients with molecularly characterized 31 muscle entities showed that for the group of congenital muscular dystrophies point prevalence was 0.89/100000 and Ullrich CMD and Bethlem myopathy have a prevalence of 0.13/100000 and 0.77/100000, respectively (58). This study for the first time presents epidemiological information for collagen VI related disorders.

## Prevention

Pattern recognition for clinical diagnosis and pedigree information is essential. Genetic counselling could be provided by collagen VI immunohistochemistry of chorion villus sample. By using both haplotype analysis of DNA extracted from chorionic villus samples and collagen VI immunocytochemistry, prenatal diagnosis of Ullrich CMD is possible. In a consanguineous family with linkage to COL6A3 locus and negative immunostaining with collagen VI in the proband's muscle tissue, haplotype analysis in combination with immunocytochemistry is presented as a rapid and a reliable method (59). Genetic counseling in Ullrich CMD may be complex in families with homozygous or compound heterozygous null mutations in COL6A1, COL6A2 and COL6A3 (60). Based on findings of increased occurrence of spontaneous apoptosis and latent mitochondrial dysfunction in myoblasts of patients with Ullrich CMD, pharmacological therapy with cyclosporine A and methylAla3ethylVal4cyclosporin in five patients with Ullrich CMD is reported and was demonstrated to prevent oligomycin-dependent mitochondrial depolarization in cells from Ullrich CMD patients (61). This study is presented by the authors as an essential step toward a pharmacological therapy. There is still a need for development of alternative outcome measures or biomarkers using different platforms such as genomics and proteomics, since randomized clinical trials are not feasible for this rare disorders (62). In the Col6a1<sup>-/-</sup> myopathic mice model, inactivation of the gene encoding for cyclophilin D was shown to rescue mitochondrial dysfunction and ultrastructural defects, and normalized incidence of apoptosis (63). The authors demonstrated that a) lack of cyclophilin D is equivalent to its inhibition with cyclosporin A at curing the mouse dystrophic phenotype, b) establish a cause-effect relationship between cyclophilin dependent permeability transition pore regulation and c) validate cyclophilin D and permeability transition pore as pharmacological targets for the therapy of human ColVI myopathies. Therapeutic effects of cyclophilin inhibitor Debio 025, a selective cyclophilin inhibitor, have been studied in Col6a1<sup>-/-</sup> myopathic mice (64). Debio 025 did not inhibit calcineurin activity, it desensitizes the mitochondrial permeability transition pore in vivo. Selective inhibition

of matrix cyclophilin D without inhibition of calcineurin, prevented the mitochondrial dysfunction and normalized the apoptotic rates and ultrastructural lesions. The authors suggest that collagen VI-related muscular dystrophies can be potentially treated with Debio 025 which does not expose patients to potential harmful effects of immunosuppression (64). Knockout mice has a mild motor phenotype and progress is hindered in part by lack of an adequate animal model for UCMD. Recently, zebrafish models of collagen VI-related myopathies are generated using antisense morpholino technology (64). Morpholinos designed to exon 9 of col6a1 produced a severe muscle disease reminiscent of UCMD, while ones to exon 13 produced a milder phenotype similar to Bethlem myopathy. This is the first vertebrate model with a severe phenotype resembling UCMD and zebrafish embryos with dominant-negative transcripts of col6a1 result in severe morphologic, structural and functional changes. Cyclosporin A improved motor deficits in UCMD-like zebrafish, but failed to reverse the sarcolemmal membrane damage (65).

## Differential diagnosis

Differential diagnosis is required with the rigid spine syndrome, merosin positive congenital muscular dystrophy, some forms of Ehler-Danlos syndrome, congenital laxity of the ligaments and connective tissue diseases. Furthermore, electron microscopy of the skin biopsies from patients with Ullrich CMD revealed ultrastructural abnormalities including alteration of collagen fibril morphology and increase in ground substance, which resemble findings in Ehler-Danlos syndrome. These findings suggest that there is true connective tissue component as part of the phenotypic spectrum of Ullrich CMD. There seems to be a clinical and morphological overlap between these two groups of disorders (66). Recently, in the French-Canadian population a new form of CMD with joint hyperlaxity and proximal contractures with a milder phenotype compared to UCMD, is defined and mapped to chromosome 3p23-21 (67). Pathological and genetic studies excluded mutations in collagen VI subunits. All patients are from the southwestern part of Quebec, suggesting a new French-Canadian founder effect.

### Diagnostic work-up

Diagnosis of Ullrich congenital muscular dystrophy is made on clinical grounds. The major features of the disease can be summarized as congenital muscular dystrophy with proximal contractures and distal laxity, with presentation usually in early infancy with neonatal hypotonia, congenital hip dislocation and torticollis. Additional key findings include a characteristic facial appearance, skin features, protruded calcanei and thickening of the subcutaneous tissue on the soles of the feet and absence of severe mental retardation. Serum creatine kinase levels may be normal or mildly elevated. An anteroposterior pelvic X-ray may be helpful to demonstrate hip dislocation. Electromyography is useless. Magnetic resonance imaging of the thigh muscles may show a selective involvement that is relative sparing of sartorius, gracilis, adductor longus and rectus (68). In a recent work, nineteen patients with genetically proven collagen VI related disorders, 10 with Bethlem myopathy and 9 with Ullrich CMD were evaluated with muscle MRI. At the thigh level, in patients with Bethlem myopathy, the vasti muscles appeared to be the most frequently and most strikingly affected thigh muscles with a rim of abnormal signal at the periphery of each muscle and relative sparing of the central part. The presence of a peculiar involvement of the rectus femoris with a central area of abnormal signal within the muscle was another frequent finding. Patients with Ullrich CMD had a more diffuse involvement of the thigh muscles with relative sparing of sartorius, gracilis and adductor longus. At the calf level a significant proportion of the patients had a rim of abnormal signal at the periphery of soleus and gastrocnemii. The authors suggest that muscle MRI may be used as an additional tool for collagen VI related disorders (69). Muscle MRI findings are also reported to be highly suggestive to identify specific patterns of involvement in muscular dystrophies with rigidity of spine (70). At the thigh and calf muscles levels respectively, UCMD is characterized by diffuse involvement with selective relative sparing of the anteromedial muscles and more diffuse changes than in Bethlem myopathy but similar peripheral involvement of the gastrocnemii, and Bethlem myopathy is characterized by peripheral involvement more obvious in vasti and internal signal in the rectus and peripheral

involvement of the gastrocnemii. Muscle biopsy shows myopathic and/or dystrophic changes with a positive staining for merosin. There is total or partial absence of Collagen VI immunostaining in muscle and fibroblast tissue in most of the patients. There are two modes of collagen VI deficiency based on immunohistochemistry: complete deficiency and sarcolemma-specific collagen VI deficiency (collagen VI is present in the interstitium but is barely detectable in the sarcolemma). Binding ability of mutated collagen VI to extracellular matrix was markedly reduced and this indicates that heterozygous mutations in COL6 genes diminish the anchorage of collagen VI microfibrils to the extracellular matrix surrounding myocytes (71). Very small muscle fibers in the patients with Ullrich CMD showed marked expression of desmin, neural cell adhesion molecule and neonatal myosin heavy chain, which is a characteristic finding of regenerating fibers, however, they showed poor expression of developmental myosin heavy chain and thrombomodulin. These additional findings suggest that abnormal regeneration or maturation processes are involved in the pathogenesis of dystrophic muscle changes in the advanced stages (72). Schessl et al studied early histological changes in muscle of patients with molecularly confirmed UCMD (73). Muscle biopsies from 8 UCMD patients with an age from 6 to 30 months were studied. Type I fiber atrophy and predominance were seen in the early stages of the disease, with a widening of fiber diameter. There were no dystrophic changes. A subpopulation of more severely atrophic type I fibers was present in one patient, fulfilling the diagnostic criteria fiber type disproportion. Early in the disease UCMD presents as a non-dystrophic myopathy with predominant fiber atrophy (73). Genetic studies including linkage and mutation analysis may further help to define COL6 gene mutations. It is also important to remember that there may be patients with an Ullrich CMD phenotype without a primary COL6 involvement. A method for rapid direct sequence analysis of all 107 coding exons of the COL6 genes using single condition amplification/internal primer (SCAIP) sequencing is described recently (30). Seventy-nine patients with Ullrich CMD or Bethlem myopathy phenotype was studied and putative mutations in one of the COL6 genes was found in 62% of the patients. This more



than doubles the number of identified COL6 mutations. Some patients showed changes in more than one of the COL6 genes so some of the Ullrich CMD patients may have dominantly acting mutations rather than recessive disease. The authors generated a large number of single nucleotide polymorphisms with this method which may be important in describing phenotypic variability seen in collagen VI related disorders (30). Quantitative RT-PCR (46) and a novel custom oligonucleotide CGH array designed to explore allelic and genetic heterogeneity in collagen VI-related myopathies (74) have been described as complementary diagnostic tools. By the use of second method, a pure intronic mutation in COL6A genes is identified for the first time and authors suggested using this technology especially in recessive forms of disease, when only one mutant allele is detected by standard sequencing (74).

### Prognosis and complications

Ullrich congenital muscular dystrophy is usually a slowly progressive disease. The clinical features and prognosis of the patients vary from each other, there are patients who never achieve independent walking usually in the sclerotic form, at the severe end of the spectrum and there are also patients who had mild delay in motor

milestones and can walk independently for years. There is no correlation between the severity of motor impairment, age at onset of the symptoms, histologic findings and collagen VI status on muscle biopsy and the severity of secondary complications (5, 7). Failure to thrive, early tendency to recurrent respiratory tract infections, spine deformities, painful dislocated hip may be the complications. Mercuri et al reported that failure to thrive became more evident after age 10 and 5 of their patients required gastrostomy(5,68,69,70). Forced vital capacity was always below 40% in all patients aged 5 years and older, 9 out of 15 patients required nocturnal ventilation and 5 of them also required scoliosis surgery. Echocardiography was normal in 7 of 154 patients, one of their patients with partial absence of Collagen VI died unexpectedly at age 12 years, bringing up the possibility of sudden electromechanical dissociation. Natural history of Ullrich CMD has been reported in a cohort of 13 patients followed up in a single center (75). Patients aged 15 years or older at last clinical attendance, who have long-term longitudinal follow-up data were included and compared with patients who were born in the same period and died, to better demonstrate the course of the disease. Diagnosis depends on clinical grounds and genetic confirmation of Col6 mutations.

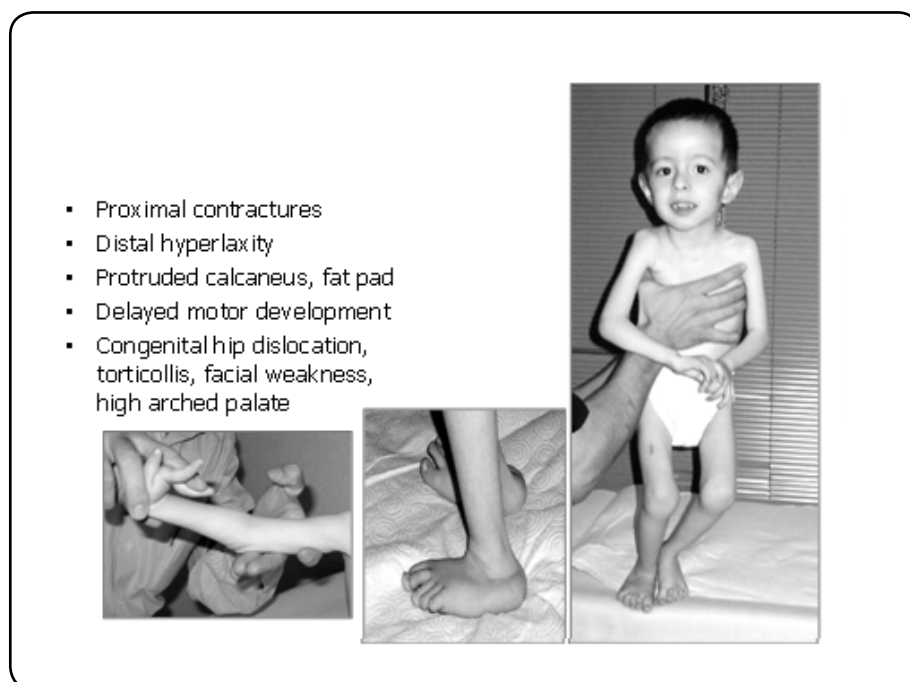


Fig 1. Ullrich CMD

The mean age of the patients was 19.5 years, mean age at onset of symptoms was 12 months (SD 14 months). Eight patients (61.5%) acquired independent ambulation at a mean age of 1.7 years (SD 0.8 years). Nine patients (69.2%) became constant wheelchair users at a mean age of 11.1 years (SD 4.8 years). Three patients continued ambulation in doors with assistance. Forced vital capacity (FVC) values were abnormal in all patients from age 6 years. The mean FVC declined at a mean rate of 2.6% (SD 4.1%) yearly. Nine patients started noninvasive ventilation at a mean age of 14.3 years (SD 5.0 years). Two patients died of respiratory insufficiency. Key points from this follow-up study are; a) The presenting features and age at presentation in these patients did not always correlate with motor and respiratory function at last follow-up, b) Maximum functional outcome did not correlate with age at onset of symptoms or the results of collagen VI immunolabeling or mutations, c) Scoliosis developed in all children except one who died at 10.8 years. The age at onset of scoliosis was between birth and 13.8 years, preceding the loss of ambulation in all patients but one. Scoliosis surgery was generally performed around the age when non-invasive ventilation was introduced, d) Respiratory insufficiency developed in nearly half of the patients who were ambulant. Two patients (15%) died at the age of 10.8 and 15.1 years due to respiratory complications in the cohort, compared to 50% mortality in another series with a mean age of 11.6 years in 1981 (76). As a summary, decline in motor and respiratory functions is more rapid in the first decade of life and deterioration is not always correlated with age or severity at presentation. Management of respiratory functions and introduction of non-invasive ventilatory support are crucial in the follow-up of these patients.

## Management

Treatment is supportive and symptomatic. Physical rehabilitation programmes, prevention of respiratory tract infections and respiratory insufficiency with non-invasive ventilatory interventions and dietary support are essential.

## Anesthesia

There is no detailed knowledge about the risk of anesthesia in patients with UCMD. On the other hand,

there is no defined complication due to anesthesia in five patients with UCMD phenotype who underwent scoliosis surgery (5).

## References

1. Ullrich O. Kongenitale, atonisch-sklerotische Muskeldystrophie, ein weiteres Typus der hereditären degenerativen Erkrankungen des neuromuskulären Systems. *Z Gesamte Neurol Psychiat* 1930; 126: 171-201.
2. Ullrich O. Kongenitale, atonisch-sklerotische Muskeldystrophie. *Monatsschr Kinderheilkd.* 1930; 47: 502-510.
3. Lampe AK, Bushby KMD. Collagen VI related disorders. *J Med Genet* 2005; 42: 673-685.
4. Muntoni F, Bertini E, Bonnemann C. 98th ENMC International Workshop on Congenital Muscular Dystrophy (CMD), 7th workshop of the international consortium on CMD, 2nd workshop of the MYO CLUSTER Project GENRE. 26-28th October, 2001, Naarden, The Netherlands. *Neuromuscul Disord* 12: 889.
5. Mercuri E, Yuva Y, Brown SC. Collagen VI involvement in Ullrich syndrome. A clinical, genetic and immunohistochemical study. *Neurology* 2002; 58: 1354-1359.
6. De Paillette L, Aicardi J, Goutieres F. Ullrich's congenital atonic sclerotic muscular dystrophy: a case report. *J Neurol* 1989; 236: 108-110.
7. Haliloglu G, Talim B, Giusti B, Pepe G, Kale G, Caglar M, Akcoren Z, Guicheney P, Topaloglu H. Ullrich congenital muscular dystrophy (UCMD): analysis of 21 families. 5th Congress of the European Paediatric Neurology Society (EPNS), Taormina, Italy, October 22-25, 2003.
8. Weil D, Mattei MG, Passage E. Cloning and chromosomal localization of human genes encoding the three chains of type VI collagen. *Am J Hum Genet* 1988; 42: 433-445.
9. Timpl R, Engel J. Type VI collagen. In: Mayne R, Burgeson RE (eds.), *Structure and Function of Collagen Types* 1987 Academic Press, New York, pp 105-143.
10. Timpl R, Chu ML. Microfibrillar collagen type VI. In: PD Yurchenco, DE Birk and RP Mecham, Editors, *Extracellular matrix assembly and structure*. Academic Press; San Diego. 1994. P. 207-242.
11. Heiskanen M, Saitta B, Palotie A, Chu ML. Head to tail organization of the human COL6A1 and COL6A2 genes

- by fiber-FISH. *Genomics* 1995; 29: 801-803.
12. Camacho Vanegas O, Zhang RZ, Sabatelli P. Novel COL6A1 splicing mutation in a family affected by mild Bethlem myopathy. *Muscle Nerve* 2002; 25: 513-519.
13. Chu ML, Conway D, Pan TC. Aminoacid sequence of the triple-helical domain of human collagen type VI. *J Biol Chem* 1988; 263: 18601-18606.
14. Chu ML, Pan TC, Conway D. Sequence analysis of alpha 1 (VI) and alpha 2 (VI) chains of human type VI collagen reveals internal triplication of globular domains similar to the A domains of von Willebrand factor and two alpha 2 (VI) chain variants that differ in the carboxy terminus. *EMBO J* 1989; 8: 1939-1946.
15. Furthmayr H, Wiedemann H, Timpl R, Odermatt E, Engel J. Electron-microscopical approach to a structural model of intima collagen. *Biochem J.* 1983 May 1; 211(2): 303-311.
16. Kuo HJ, Maslen CL, Kene DR, Glanville RW. Type VI collagen anchors endothelial basement membranes by interacting with type IV collagen. *J Biol Chem* 1997; 272: 26522-26529.
17. Ishikawa H, Sugie K, Murayama K. Ullrich disease: collagen VI deficiency: EM suggests a new basis for muscular weakness. *Neurology* 2002; 59: 920-923.
18. Camacho Vanegas O, Bertini E, Zhang RZ. Ullrich scleroatonic muscular dystrophy is caused by recessive mutations in collagen type VI. *Proc Natl Acad Sci* 2001; 98: 7516-7521.
19. Higuchi I, Shiraishi T, Hashiguchi T. Frameshift mutation in the collagen VI gene causes Ullrich's disease. *Ann Neurol* 2001; 50: 261-265.
20. Jöbsis GJ, Boers JM, Barth PG, de Visser M. Bethlem myopathy: a slowly progressive congenital muscular dystrophy with contractures. *Brain* 1999; 122: 649-655.
21. Jöbsis GJ, Keizers H, Vreijling JP. Type VI collagen mutations in Bethlem myopathy, an autosomal dominant myopathy with contractures. *Nat Genet* 1996; 14: 113-115.
22. Demir E, Sabatelli P, Allamand V. Mutations in COL6A3 gene cause severe and mild phenotypes of Ullrich congenital muscular dystrophy. *Am J Hum Genet* 2002; 70: 1446-1458.
23. Pan TC, Zhang R, Sudano D. New molecular mechanism of Ullrich Congenital Muscular Dystrophy: A Heterozygous In-Frame Deletion in the COL6A1 gene causes a severe phenotype. *Am J Hum Genet* 2003; 73: 355-369.
24. Bethlem J, Wijngaarden GK. Benign myopathy, with autosomal dominant inheritance. A report on three pedigrees. *Brain.* 1976 Mar;99(1):91-100.
25. Bertini E, Pepe G. Collagen type VI and related disorders: Bethlem myopathy and Ullrich scleroatonic muscular dystrophy. *Eur J Pediatr Neurol* 2002; 6: 193-198.
26. Scacheri PC, Gillanders EM, Subramony SH. Novel mutations in collagen VI genes: expansion of the Bethlem myopathy phenotype. *Neurology* 2002; 58: 593-602.
27. Zhang RZ, Sabatelli P, Pan TC. Effects on collagen VI mRNA stability and microfibrillar assembly of three COL6A2 mutations in two families with Ullrich congenital muscular dystrophy. *J Biol Chem* 2002; 277: 43557-43564.
28. Usuki F, Yamashita A, Kashima I, Higuchi I, Osame M, Ohno S. Specific inhibition of nonsense-mediated mRNA decay components, SMG-1 or Upf1, rescues the phenotype of Ullrich disease fibroblasts. *Molecular Therapy* 2006; 14: 351-360.
29. Heino J. The collagen receptor integrins have distinct ligand recognition and signaling functions. *Matrix Biol* 2000; 19: 3129-3123.
30. Lampe AK, Dunn DM, von Niederhausen AC. Automated genomic sequence analysis of the three collagen VI genes: applications to Ullrich congenital muscular dystrophy and Bethlem myopathy. *J Med Genet* 2005; 42: 108-120.
31. Baker NL, Mörgelin M, Peat R, Goemans N, North KN, Bateman JF. Dominant collagen VI mutations are a common cause of Ullrich congenital muscular dystrophy. *Hum. Mol. Genet.* (15 January 2005) 14 (2): 279-293
32. Pepe G, Lucarini L, Zhang R-Z. COL6A1 genomic deletions in Bethlem myopathy and Ullrich muscular dystrophy. *Ann Neurol* 2006; 59: 190-195.
33. Lamandé SR, Shields KA, Kornberg AJ, Shield LK, Bateman JF. Bethlem myopathy and engineered collagen VI triple helical deletions prevent intracellular multimer assembly and protein secretion. *J Biol Chem* 1999; 274:21817-21822.
34. Lamandé SR, Mörgelin M, Selan C. Kinked collagen VI tetramers and reduced microfibril formation as a result of

- Bethlem myopathy and introduced triple helical glycine mutations. *J Biol Chem* 2002; 277: 1949-1956.
35. Tillet E, Wiedemann H, Golbik R. Recombinant expression and structural and binding properties of alpha 1 (VI) and alpha 2 (VI) chains of human collagen type VI. *Eur J Biochem* 1994; 221: 177-185.
  36. Pace RA, Peat RA, Baker NL. Collagen VI glycine mutations: perturbed assembly and a spectrum of clinical severity. *Ann Neurol* 2008; 64: 294-303.
  37. Engel J, Prockop DJ. The zipper-like folding of collagen triple helices and the effects of mutations that disrupt the zipper. *Annu Rev Biophys Chem* 1991; 20: 137-152.
  38. Lampe AK, Zou Y, Sudano D. Exon skipping in collagen VI are common and are predictive for severity and inheritance. *Hum Mut* 2008; 29: 809-822.
  39. Gualandi F, Urciuolo A, Martoni E. Autosomal recessive Bethlem myopathy. *Neurology* 2009; 73: 1883-1891.
  40. Foley RA, Hu Y, Zou Y. Autosomal recessive inheritance of classic Bethlem myopathy. *Neuromusc Disord* 2009; 19: 813-817.
  41. Foley RA, Hu Y, Zou Y. Large genomic deletions: A novel cause of Ullrich congenital muscular dystrophy. *Ann Neurol* 2011; 69: 206-211.
  42. Demir E, Ferreira A, Sabatelli P. Collagen VI status and clinical severity in Ullrich congenital muscular dystrophy: phenotype analysis of 11 families linked to the COL6 loci. *Neuropediatrics* 2004; 35: 103-112.
  43. Giusti B, Lucarini L, Pietroni V. Dominant and recessive COL6A1 Mutations in Ullrich Scleroatonic Muscular Dystrophy. *Ann Neurol* 2005; 58: 400-410.
  44. Lucarini L, Giusti B, Zhang R-Z. A homozygous COL6A2 intron mutation causes in-frame triple helical deletion and non-sense mediated mRNA decay in a patient with Ullrich congenital muscular dystrophy. *Hum Genet* 2005; 117: 460-466.
  45. Pepe G, Giusti B, Bertini E. A heterozygous splice site mutation in COL6A1 leading to an in-frame deletion of the 1 (VI) collagen chain in an Italian family affected by Bethlem myopathy. *Biochem Biophys Res Commun* 1999; 258: 802-807.
  46. Brinas L, Richard P, Quijano-Roy S. Early onset collagen VI myopathies: Genetic and clinical correlations. *Ann Neurol* 2010; 68: 511-520.
  47. Jimenez-Mallebrera C, Maioli MA, Kim J. A comparative analysis of collagen VI production in muscle, skin and fibroblasts from 14 Ullrich congenital muscular dystrophy patients with dominant and recessive COL6A mutations. *Neuromusc Disord* 2006; 16: 571-582.
  48. Petrini S, D'Amico A, Sale P. Ullrich myopathy phenotype with secondary ColVI defect identified by confocal imaging and electron microscopy analysis. *Neuromuscul Disord* 2007; 17: 587-596.
  49. Niyama T, Higuchi I, Suehara M. Electron microscopic abnormalities of skeletal muscle in patients with collagen VI deficiency in Ullrich's disease. *Acta Neuropathol* 2002; 104: 67-71.
  50. Vogel WF. Collagen-receptor signaling in health and disease. *Eur J Dermatol* 2001; 11: 506-514.
  51. Kawahara G, Okada M, Morone N. Reduced cell anchorage may cause sarcolemma-specific collagen VI deficiency in Ullrich disease. *Neurology* 2007; 4: 1043-1049.
  52. Sipila L, Ruotsalainen H, Sormunen R. Secretion and assembly of type IV and VI collagens depend on glycosylation of hydroxylysines. *J Biol Chem* 2007; 16: 33381-33388.
  53. Sabatelli P, Gara SK, Grumati P. Expression of the collagen VI  $\alpha 5$  and  $\alpha 6$  chains in normal human skin and in skin of patients with collagen VI-related myopathies. *J Invest Dermatol* 2011; 131: 99-107.
  54. Irwin WA, Bergamin N, Sabatelli P. Mitochondrial dysfunction and apoptosis in myopathic mice with collagen VI deficiency. *Nat Genet* 2003; 35: 267-271.
  55. Angelin A, Bonaldo P, Bernardi P. Altered threshold of the mitochondrial permeability transition pore in Ullrich congenital muscular dystrophy. *Biochimica et Biophysica Acta* 2008; 1777: 893-896.
  56. Bernardi P, Bonaldo P. Dysfunction of mitochondria and sarcoplasmic reticulum in the pathogenesis of collagen VI muscular dystrophies. *Ann. N.Y. Acad. Sci* 2008; 1147: 303-311.
  57. Grumati P, Coletto L, Sabatelli P. Autophagy is defective in collagen VI muscular dystrophies, and its reactivation rescues myofiber degeneration. *Nat Med* 2010; 16: 1313-1321.
  58. Norwood FLM, Harling C, Chinnery PF. Prevalence of



- genetic muscle disease in Northern England: in-depth analysis of a muscle clinic population. *Brain* 2009; 132: 3175-3186.
59. Brockington M, Brown SC, Lampe A. Prenatal diagnosis of Ullrich congenital muscular dystrophy using haplotype analysis and collagen VI immunocytochemistry. *Prenat Diagn* 2004; 24: 440-444.
60. Peat RA, Baker NL, Jones KJ. Variable penetrance of COL6A1 null mutations: Implications for prenatal diagnosis and genetic counseling in Ullrich congenital muscular dystrophy families. *Neuromuscul Disord* 2007; 17: 547-557.
61. Angelin A, Tiepolo T, Sabatelli P. Mitochondrial dysfunction in the pathogenesis of Ullrich congenital muscular dystrophy and prospective therapy with cyclosporins. *PNAS* 2007; 104: 991-996.
62. Merlini L, Bernardi P. Therapy of collagen VI related myopathies (Bethlem and Ullrich). *Neurotherapeutics* 2008; 5: 613-618.
63. Palma E, Tiepolo T, Angelin A. Genetic ablation of cyclophilin D rescues mitochondrial defects and prevents muscle apoptosis in collagen VI myopathic mice. *Hum Molec Genet* 2009; 18: 2024-2031.
64. Tiepolo T, Angelin A, Palma E. The cyclophilin inhibitor Debio 025 normalizes mitochondrial function, muscle apoptosis and ultrastructural defects in Col6a1-/- myopathic mice. *British J Pharmacol* 2009; 157: 1045-1052.
65. Telfer WR, Busta AS, Bonnemann CG, Feldman EL, Dowling JJ. Zebrafish models of collagen VI-related myopathies. *Hum Molec Genet* 2010; 19: 2433-2444.
66. Kirschner J, Hausser I, Zou Y. Ullrich congenital muscular dystrophy: connective tissue abnormalities in the skin support overlap with Ehler-Danlos syndrome. *Am J Med Genet* 2005; 132A: 296-301.
67. Tétreault M, Duquette A, Thiffault I. A new form of congenital muscular dystrophy with joint hyperlaxity maps to 3p23-21. *Brain* 2006; 129: 2077-2084.
68. Mercuri E, Cini C, Pichiecchio A. Muscle magnetic resonance imaging in patients with congenital muscular dystrophy and Ullrich phenotype. *Neuromuscul Disord* 2003; 13: 554-558.
69. Mercuri E, Lampe A, Allsop J. Muscle MRI in Ullrich congenital muscular dystrophy and Bethlem myopathy. *Neuromuscul Disord* 2005; 15: 303-310.
70. Mercuri E, Clements E, Offiah A. Muscle magnetic resonance imaging involvement in muscular dystrophies with rigidity of the spine. *Ann Neurol* 2010; 67: 201-208.
71. Kawahara G, Ogawa M, Okada M. Diminished binding of mutated collagen VI to the extracellular matrix surrounding myocytes. *Muscle Nerve* 2008; 38: 1192-1195.
72. Higuchi I, Horikiri T, Niiyama T. Pathological characteristics of skeletal muscle in Ullrich's disease with collagen VI deficiency. *Neuromuscul Disord* 2003; 13: 310-316.
73. Schessl J, Goemans NM, Magold AI. Predominant fiber atrophy and fiber type disproportion in early Ullrich disease. *Muscle Nerve* 2008; 38: 1184-1191.
74. Bovolenta M, Neri M, Martoni E. Identification of a deep intronic mutation in the COL6A2 gene by a novel custom oligonucleotide CGH array designed to explore allelic and genetic heterogeneity in collagen VI-related myopathies. *BMC Medical Genetics* 2010; 11: 44.
75. Nadeau A, Kinali M, Main M. Natural history of Ullrich congenital muscular dystrophy. *Neurology* 2009; 73: 25-31.
76. Nonaka I, Une Y, Ishihara T, Miyoshino S, Nakashima T, Sugita H. A clinical and histological study of Ullrich's disease (congenital atonic-sclerotic muscular dystrophy). *Neuropediatrics* 1981; 12: 197-208.