

Research Paper: Brain CT Scan Findings in Patients Admitted to the Poisoning ICU of Baharloo Hospital, Tehran, Iran

Behnam Behnoush¹, Mahvash Ghahramani¹, Fakhredin Taghaddosinejad¹, Arash Okazi^{1*}

1. Department of Forensic Medicine, School of Medicine, Tehran University of Medical Sciences, Tehran, Iran.



Citation: Behnoush B, Ghahramani M, Taghaddosinejad F, Okazi A. Brain CT Scan Findings in Patients Admitted to the Poisoning ICU of Baharloo Hospital, Tehran, Iran. International Journal of Medical Toxicology & Forensic Medicine. 2017; 7(4):215-220. [http://dx.doi.org/10.22037/ijmtfm.v7i4\(Autumn\).17345](http://dx.doi.org/10.22037/ijmtfm.v7i4(Autumn).17345)

doi: [http://dx.doi.org/10.22037/ijmtfm.v7i4\(Autumn\).17345](http://dx.doi.org/10.22037/ijmtfm.v7i4(Autumn).17345)

Article info:

Received: 09 Jun. 2017

Accepted: 19 Sep. 2017

ABSTRACT

Background: Timely and correct diagnosis of poisoning is an important part of the management of poisoned patients. This study aimed to investigate the abnormal findings of brain CT scans of patients with drug overdose poisoning.

Methods: A retrospective cross-sectional study was conducted on patients with poisoning admitted to Baharloo Hospital, Tehran, Iran during 2015. Moreover, they underwent radiological assessment as a result of their decreased level of consciousness. For the purpose of the study, we examined patients' Computerized Tomography (CT) scan reports. The collected data were analyzed with SPSS 16. Frequency and percentage frequency were calculated for qualitative variables, and mean and standard deviation were calculated for the quantitative variables.

Results: Overall, 191 patients admitted with poisoning were evaluated. Of them, 119(62.3%) had normal brain CT scans and the remaining had pathologic findings. The most common pathologic findings in the brain CT scans comprised cerebral edema (24.6%) followed by infarction (5.2%). The least common pathologic finding was cerebral herniation (0.5%). This pattern was similar in both genders and in different subtypes of poisonings, with the exception of poisoning with cardio-respiratory drugs. The most common finding in the latter type of poisoning was herniation. In cases of simultaneous head trauma, the most common pathological brain CT scan findings were cerebral edema and hemorrhage.

Conclusion: The radiological assessment of the brain following poisoning and decreased level of consciousness can help in the diagnostic evaluation of patients. It can be a life-saving measure, through timely detection of the type of poisoning and brain damage.

Keywords:

Poisoning, Head trauma, CT scan, Radiology

1. Introduction

A

cute poisoning is nowadays one of the most common medical emergencies [1] and constitutes 1% to 5% of all cases attending general medical centers [2]. Generally,

the incidence of various types of poisoning, intentional or unintentional, is globally on the rise [3]. The significance of radiological assessment in the initial stages of attending the emergency department with decreased Level of Consciousness (LOC) has been proven and approved. Brain Computer Tomography (CT) scans in unconscious patients

*Corresponding Author:

Arash Okazi, PhD

Address: Department of Forensic Medicine, School of Medicine, Tehran University of Medical Sciences, Tehran, Iran.

Tel: +98 (912) 4067027

E-mail: Okazi@sina.tums.ac.ir

greatly facilitate the initial diagnosis of life-threatening pathologies [4].

Moreover, radiological brain assessments can identify the specific effects of certain poisonous substances on the central nervous system [5]. Poisoned patients present differently, some may have died before reaching the medical center, some present in a comatose state and some may have symptoms that cannot be attributed to any specific substance. In such patients, radiologic brain findings can help diagnose the type of poisoning or identify possible trauma [6]. The increasing use and widespread application of brain CT at the bedside have facilitated the detection of brain damage following poisoning.

Different toxins cause different brain damages in the poisoned individual, such as, cerebral atrophy, extracranial hemorrhage, cerebral edema, ischemia and infarction. Therefore, the responsible toxin should be detected as soon as possible. As a result, the therapeutic measures should start immediately, to prevent death or worsening of the patient's situation [7]. Moreover, brain damage associated with poisoning must be detected in patients with decreased LOC and a history of poisoning. A brain CT scan is recommended to rule out associated brain damages in all patients with a GCS lower than 15, any history of brain damage, and or neurologic examination suggestive of brain damage [8]. The brain CT scan can identify the type of poisoning and its associated brain damages [9]. Bearing in mind the large number of poisoning cases, this study was designed to investigate the abnormal brain CT scan findings in a large sample of poisoning and or drug over-dose cases, to use its findings in the timely detection of poisoning cases.

2. Materials and Methods

A retrospective cross-sectional study was conducted on all patients admitted to Baharloo Hospital for poisoning, who

had undergone radiological assessments. The inclusion criteria included, the initial diagnosis of poisoning and loss of consciousness associated with poisoning. The exclusion criteria included incomplete hospital files and simultaneous head trauma. Level of significance was set at 5% and statistical power was considered as 80%. The CT scan reports of the patients admitted to the Poison Center of Baharloo Hospital during the past year were registered.

All CT scans taken from the time of admission up to the time of discharge were included, along with the details of the exact times and trends of change observed, sequentially. The time of admission, medications taken, the time(s) of the first and following CT scans along with the explanations related to the subsequent changes observed in cerebral tissues were documented in a questionnaire.

3. Results

Overall, 191 files were investigated. Of them, 119 (62.3%) had normal brain CT scans, and the remainder showed pathologic findings in the radiologic assessment. The mean (SD) age of the study participants was 37(16.9) years (age range: 14–85 year). The characteristics of toxicity type, brain CT findings and brain CT findings in any toxicity type were shown in Tables 1, 2 and 3.

The most common pathologic finding in the CT was cerebral edema (24.6%), followed by infarction (5.2%). The least common pathologic finding was herniation (0.5%) (Table 2).

Regarding age and sex, the same pattern of frequency of pathologic findings was observed in both genders and all age groups. The most common reasons of admission were suicide (125 individuals), followed by substance abuse (50 individuals), and then accidental poisoning (5 individuals).

Table 1. The frequency of type of poisoning in patients with acute poisoning and loss of consciousness

	No.	%
Medication	163	85.3
Agriculture toxin	2	1.0
Rodenticides	5	2.6
Alcohol	1	0.5
CO gas	1	0.5
Unknown	19	9.9
Total	191	100.0

Table 2. The frequency of brain CT findings in patients with acute poisoning and loss of consciousness

		No.	%
CT result	Normal	119	62.3
	Cerebral edema	47	24.6
	Infarction	10	5.2
	Other	12	6.3
	Bleeding	2	1.0
	Hernia	1	0.5
	Total	183	95.8
Total		191	100

International Journal of
Medical Toxicology & Forensic Medicine

The same pattern of frequency of findings was observed in the CT scans of the suicide and substance abuse cases.

Upon separately studying the type of substance used, all cases of cerebral edema were observed in the drug and pesticide poisonings. Of 168 patients admitted with drug poisoning, 107 had normal brain CT scans. Cerebral infarction, hemorrhage and herniation were only observed in drug poisonings. Most of the CT scans that had pathologic findings were related to narcotic poisoning (109 individuals). In this group, the most common pathologic finding was cerebral edema (27.5%), followed by infarction (5.5%) and hemorrhage (1.8%). Poisoning with anxiolytics ensued (18 individuals), wherein the most pathologic finding was cerebral edema (22.2%) and infarction (5.6%). Analgesics and anti-inflammatory drugs came next (13 cases), where the most common pathologic finding observed was cerebral edema (46.2%). Poisoning with anticonvulsant drugs was the next most common type of drug poisoning (12 cases), and the most common pathologic findings were cerebral edema (25%) and infarction

(8.3%). Then, there was poisoning with cardio-respiratory drugs (5 cases), in which the only pathologic finding was herniation (20%). Finally, the least common drug poisoning belonged to anesthetics (1 case), wherein the only pathologic finding was infarction (100%).

LOC (GCS score) was divided into three groups: 3-8; 9-11; and 12-15. The most common pathologic findings of the brain CT were observed in the '3-8' GCS score group (45.3%). Such findings were observed in 25% of the patients with a GCS score of 9-11. In the '12-15' GCS score group, pathological findings were observed in 22% of patients. The prevalence of each of these findings are presented in [Table 4](#) and [Figure 1](#).

Normal brain CT scans were seen in 65.2% of patients with acute poisoning and simultaneous head trauma. The most common pathologic finding in these patients were cerebral edema (28.6%) and hemorrhage (14.3%). However, in the patients without history of head trauma,

Table 3. The frequency of brain CT findings in any toxicity type in patients with acute poisoning and loss of consciousness

Toxicity Type	CT Findings	No.	%
Medication	Hernia	1	0.6
	Infarction	10	5.8
	Bleeding	2	1.2
	Cerebral edema	42	24.4
	Other	3	1.7
	Normal	105	61.0
Agriculture toxin	Normal	2	1.2
Rodenticides	Cerebral edema	1	0.6
	Normal	4	2.3
Alcohol	Normal	1	0.6
CO gas	Other	1	0.6

International Journal of
Medical Toxicology & Forensic Medicine

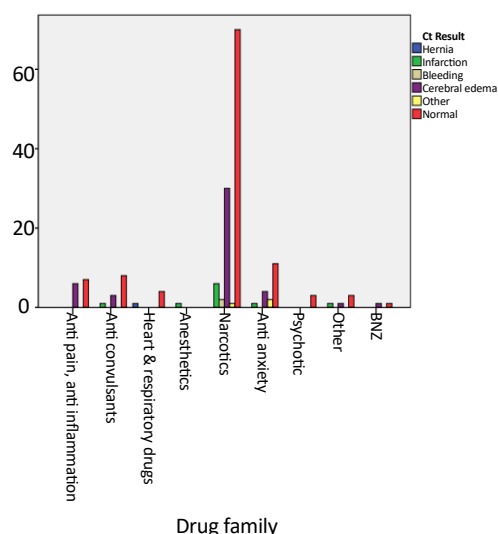


Figure 1. Frequency of brain CT scan findings of poisoning drugs in patients with acute poisoning and loss of consciousness

the most common findings were cerebral edema (25.2%) and infarction (6%).

4. Discussion

Decreased LOC is a common complication of acute poisoning [10]. One of the usual presentations of overdose is different levels of coma. This state may be created as a result of the substance used, secondary trauma following poisoning or combination of both [11]. The purpose of the brain CT in such patients was to rapidly diagnose the cause of reduced consciousness, such as traumatic cerebral hemorrhage, or locating a possible hematoma. However, in addition to ruling out such causes, brain CT scan can hint towards the types of substances that have caused the poisoning, as certain poisonous substances have specific presentations in radiological assessments.

These presentations can help in the faster and perhaps more effective cure of poisoned patients. Based on the current study, the most common pathologic findings in the CT of patients with simultaneous lowered consciousness and poisoning were cerebral edema and infarction. These pathological findings were similar across different genders and poisonings, with the exception of cardio-respiratory drug poisoning, in which the most common pathologic finding was cerebral herniation.

Most of the poisonings included in our study were drug-related, an observation confirmed by other studies [12, 13]. Narcotic drugs contributed the most to this share, in which the most common pathologic findings were cerebral edema, infarction and hemorrhage. Other studies have also indicated that the most common presentations of opioid poisonings in brain CT scans are cerebral infarction, edema, hemorrhage, and reduced density of the basal ganglia [14]; all are consistent with our findings. Here, poisoning with anti-convulsants was associated with cerebral edema and infarction. Earlier studies have also shown the association of mild cerebral edema with a high dose of anti-convulsant intake [15]. Benzodiazepine poisoning was also associated with cerebral edema, another finding that is consistent with studies conducted elsewhere; although infarction was observed as well. The long-term use of benzodiazepines, however, manifests as cerebral atrophy in radiologic assessments [16].

Among drugs, the most common drugs seen in poisonings were opioids. Most other related studies have reported opioid poisoning as the most common type of drug poisoning too [17]. However, some studies have rated opioid poisoning as the second most common type of poisoning [18]. Such statistics indicate the ease of access to opioid substances in high doses. We neighbor with the largest producer of opioid substances in the world, and our country lies

Table 4. Frequency of brain CT findings in various GCS levels of patients with acute poisoning and loss of consciousness

			CT Findings						Total
			Hernia	Infarction	Bleeding	Cerebral Edema	Other	Normal	
GCS class	3-8	No.	1	5	1	29	3	47	86
		%	1.2%	5.8%	1.2%	33.7	3.5	54.7	100
	9-11	No.	0	5	0	11	0	48	64
		%	0	7.8	0	17.2	0	75.0	100
	12-15	No.	0	0	1	4	1	21	27
		%	0	0	3.7	14.8	3.7	77.8	100
Total (%)		No.	1	10	2	44	4	116	177
		0.6	5.6	1.1	24.9	2.3	65.5	100	

along its transport route as well. In light of the aforementioned fact and the high prevalence of narcotic substance abuse in the country, a multisectoral and comprehensive plan should be designed to reduce access to these substances, and eventually lower the prevalence of poisonings with these substances.

5. Conclusion

The radiologic assessment of the brain following poisoning and reduced LOC can prove beneficial in the diagnostic evaluations of patients. The most common pathologies found in the brain CT scans were cerebral edema and infarction, and the least common was herniation. For future studies, we recommend using larger sample size with variety of poisonings to investigate the differences in brain CT scans in different types of poisonings.

Acknowledgements

The present paper was extracted from the thesis of the second Author in the Department of Forensic Medicine, School of Medicine, Tehran University of Medical Sciences, Tehran.

Conflict of Interest

The authors declared no conflicts of interest.

References

- [1] Murray CJL, Lopez AD. The global burden of disease: A comprehensive assessment of mortality and disability from diseases, injuries and risk factors in 1990 and projected to 2020. Geneva: World Health Organization; 1996.
- [2] Islambulchilar M, Islambulchilar Z, Kargar-Maher M. Acute adult poisoning cases admitted to a university hospital in Tabriz, Iran. *Human & Experimental Toxicology*. 2009; 28(4):185-90. doi: 10.1177/0960327108099679
- [3] Litovitz TL, Klein-Schwartz W, White S, Cobaugh DJ, Youniss J, Omslaer JC, et al. 2000 annual report of the American association of poison control centers toxic exposure surveillance system. *The American Journal of Emergency Medicine*. 2001; 19(5):337-95. doi: 10.1053/ajem.2001.25272
- [4] Lal NR, Murray UM, Eldevik OP, Desmond JS. Clinical consequences of misinterpretations of neuroradiologic CT scans by on-call radiology residents. *American Journal of Neuroradiology*. 2000; 21(1):124-29. PMID: 10669236
- [5] Brent J, Wallace KL, Burhart K. Critical care toxicology: Diagnosis and management of the critically poisoned patient. Philadelphia, Pennsylvania: Elsevier; 2004
- [6] Craig SA. CNS depression. In: Ford MD, Delaney KA, Ling LJ, Erickson T, editors. *Radiology: Clinical Toxicology*. Philadelphia, Pennsylvania: Saunders; 2001.
- [7] Marsha F, Kathleen A, Ling L, Ericson T. *Clinical toxicology*. Philadelphia, Pennsylvania: Saunders; 2000.
- [8] Stiell IG, Wells GA, Vandemheen K, Clement C, Lesiuk H, Laupacis A et al. The Canadian CT head rule for patients with minor head injury. *Lancet*. 2001; 357(9266):1391-6. PMID: 11356436
- [9] Choi IS, Kim SK, Choi YC, Lee SS, Lee MS. Evaluation of outcome after acute carbon monoxide poisoning by brain CT. *Journal of Korean Medical Science*. 1993; 8(1):78-83. doi: 10.3346/jkms.1993.8.1.78
- [10] Henderson A, Wright M, Pond SM. Experience with 732 acute overdose patients admitted to an intensive care unit over six years. *The Medical Journal of Australia*. 1993; 158(1):28-30. PMID: 8417286
- [11] Haydel MJ, Preston CA, Mills TJ, Luber S, Blaudeau E, DeBlieux PM. Indications for computed tomography in patients with minor head injury. *New England Journal of Medicine*. 2000; 343(2):100-5. doi: 10.1056/nejm200007133430204
- [12] Shadnia S, Esmaily H, Sasanian G, Pajoumand A, Hassanian-Moghaddam H, et al. Pattern of acute poisoning in Tehran-Iran in 2003. *Human & Experimental Toxicology*. 2007; 26(9):753-6. doi: 10.1177/0960327107083017
- [13] Varnell RM, Stimac GK, Fligner CL. CT diagnosis of toxic brain injury in cyanide poisoning: considerations for forensic medicine. *American Journal of Neuroradiology*. 1987; 8(6):1063-6. PMID: 3120533
- [14] Geibprasert S, Gallucci M, Krings T. Addictive illegal drugs: Structural neuroimaging. *American Journal of Neuroradiology*. 2009; 31(5):803-8. doi: 10.3174/ajnr.a1811
- [15] Lim CC. Magnetic resonance imaging findings in bilateral basal ganglia lesions. *ANNALS Academy of Medicine Singapore*. 2009; 38(9):795-8. PMID: 19816639
- [16] Perera KM, Powell T, Jenner FA. Computerized axial tomographic studies following long-term use of benzodiazepines. *Psychological Medicine*. 1987; 17(03):775-7. doi: 10.1017/s0033291700026003
- [17] Abdollahi M, Jalali N, Sabzevari O, Hoseini R, Ghanea T. A retrospective study of poisoning in Tehran. *Journal of Toxicology: Clinical Toxicology*. 1997; 35(4):387-93. doi: 10.3109/15563659709043371
- [18] Izadi-Mood N, Tavahen N, Masoumi GR, Gheshlaghi F, Siadat ZD, Setareh M, et al. [Demographic factors, duration of hospitalization, costs of hospitalization, and cause of death in patients intoxicated with amphetamines and opioids (Persian)]. *Journal of Isfahan Medical School*. 2011; 29(146):890-900.

